

Extranasopharyngeal Angiofibroma of the Nasal Septum A Case Report and Review of the Literature

Abdulrahman Al Khatib,^a Ali Al Momen,^b Hazim Al Eid^b

^aAssistant consultant ^bConsultant, ENT Section, Department of Surgery, King Fahad Specialist Hospital-Dammam, KSA

Correspondence to Abdulrahman Al Khatib
Tel: 00966138442222
e-mail: drent73@gmail.com

Received 26 April 2015
Accepted 2 April 2015
PAN Arab Journal of Rhinology
2015, 2:84-86

Nasopharyngeal angiofibromas are benign tumours occurring most commonly in adolescent males. The incidence of extranasopharyngeal angiofibroma (ENA) is very rare and nasal septum is a very rare site of origin of ENA. We report a rare case of ENA originating from the nasal septum. A 13 year old boy presenting with left sided nasal cavity mass. The diagnosis was made after excision and histopathological confirmation. The post-operative period was uneventful with no recurrence on 18 months follow-up.

Keywords: Angiofibroma, Nasal Septum, Endoscopic Excision

INTRODUCTION

Angiofibroma is a benign, but locally aggressive and extremely vascular Head and Neck neoplasm, occurring almost exclusively in the nasopharynx of adolescent males and accounts for only 0.5% of all head and neck tumors. [1] The lesion is composed of fibrous tissue interspersed to a variable degree with endothelium lined vascular spaces.

They usually arise from the posterolateral wall of the nasal cavity, where the sphenoidal process of the palatine bone meets the horizontal ala of the vomer and the pterygoid process. Tumors with histopathological features similar to angiofibroma which do not arise in nasopharynx have been described in the literature as extranasopharyngeal angiofibroma. (ENA).

ENA arising from the nasal Septum is extremely rare. [2,3]

CASE REPORT

A thirteen years old boy presented to ENT clinics of KFSH-D with a history of progressive left-side nasal obstruction and occasional episodes of mild epistaxis for 5 months duration.

Furthermore, he noticed a nasal mass on the left side with pulgung of the lateral nasal wall. The patient had no other health problems. The coagulation status was normal. External examination of nose showed fullness over left ala. Computerized tomography of nose and paranasal sinuses with contrast showed an enhancing homogenous opacity involving the anterior half of left nasal cavity with no extension to paranasal sinuses or nasopharynx (Fig. 1).

On anterior rhinoscopy, a pinkish brown, smooth, firm, lobular mass filling the left nasal cavity. On probing, the probe could be passed all around except medially with minimal bleeding on touching.

Endonasal endoscopic excision of the mass was performed under GA. The tumor attachment was very close to the bony cartilaginous junction when the base was cauterized with bipolar coagulation.

Intraoperative bleeding was minimal and anterior nasal pack was inserted and removed after 24 hours. The excised mass measured 4x2.5x1 sent for histopathology examination which revealed fibrous stroma with rich vascularity and network of sinusoidal like vascularity (Fig. 2). This confirmed the diagnoses of angiofibroma. Post-operative follow up of the patient for 18 months revealed no recurrence.

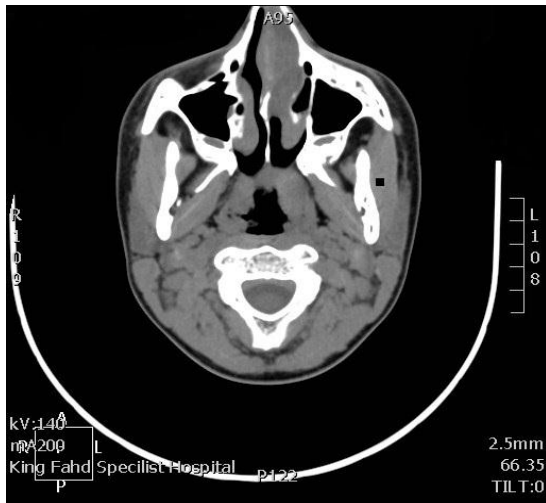


Fig 1

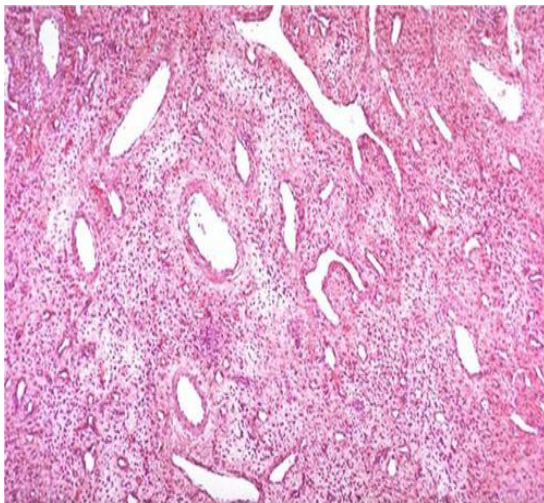


Fig 2

DISCUSSION

Angiofibroma of the head and neck are benign nonencapsulated lesions occurring predominantly in the nasopharynx. [4] The tumor usually originated near the Sphenopalatine foramen region, later it grows in all direction through multiple projections. [5] It develops almost exclusively in adolescent males, though there are reports of this tumor being found in children, the elderly and pregnant women. [6] There are various theories to explain the etiology of nasopharyngeal angiofibroma. They can be developmental, hormonal and genetics but none of them found general acceptance. Currently JAF are believed to be as vascular malformation, arising from discontinuous vascular basal

laminae, focal lack of pericytes and pronounced of the smooth muscle layers. [7]

Primary extranasopharyngeal angiofibromas have been reported sporadically in the literature. They most commonly originate from the maxillary sinus. Other rare sites reported are the ethmoid sinus, sphenoid sinus, nasal septum, middle and inferior turbinate, conjunctiva, molar and retromolar trigone, tonsil and larynx. [8,4,9]

Unlike nasopharyngeal angiofibroma, extra nasopharyngeal angiofibroma occur more frequently in female at later age [4] These tumors have a different clinical presentation due to their location and age of presentation and a different biological behavior. [10]

These case of extranasopharyngeal angiofibroma in nasal cavities present with painless, gradual increasing unilateral nasal obstruction, facial deformities and epistaxis.

The stalk of a septal extranasopharyngeal angiofibroma may be located at the junction of the perpendicular plate with quadrangular cartilage. It had been speculated that the tissue of origin is probably the periosteum of the perpendicular plate of the ethmoid bone as an abnormal presentation of the fascia basalis. [11] Involvement of septum may mimic bleeding polypus septum and the latter was the previous diagnosis in our case which turned out to be angiofibroma on histology.

The investigations required in a clinically suspected angiofibroma are CT and angiography. A transnasal biopsy is avoided as it can provoke brisk hemorrhage. Diagnostic angiography is undertaken to evaluate the blood supply to the tumor and as a prelude to selective embolization. [6] The various modalities for the treatment of angiofibromas include surgery, hormonal therapy, radiation and chemotherapy. [4] However, surgery remains the primary course of treatment especially for extranasopharyngeal angiofibroma. [5, 6]

In our case, the size and location of tumor permitted us to remove it completely, using simple endoscopic surgical procedure, without previous selective arteriography and embolization. The mass was limited to the left nasal cavity without eroding the nasal septum or the lateral wall of the nose. The nasopharynx was free. The histology of the mass was suggestive of angiofibroma.

CONCLUSION

Angiofibroma arising from the nasal septum is extremely rare. However, differential diagnosis of angiofibroma should be considered for any patient coming with complaints of nasal mass and spontaneous, recurrent epistaxis irrespective of age, sex, site of origin and extension of the mass.

Radiological and endoscopic examination along with histopathological analysis is necessary for its diagnosis. Surgical excision of the mass is the treatment of choice.

REFERENCES

1. Schiff M. juvenile nasopharyngeal angiofibroma. *Laryngoscope*. 1959;69:981-1016.
2. Tasca I, Compadretti GC. Extranasopharyngeal angiofibroma of nasal septum. A controversial entity. *Acta otorhinolaryngol Ital*. 2008;28:312-4.
3. Castillo MP, Timmons CF, McClay JE. Autoamputation of an extranasopharyngeal angiofibroma of the nasal septum. *Int. J. Pediatr. Otorhinolaryngol Extra*. 2000;Suppl 1:267-70.
4. J.P. Windfuhr and S.Remmert,"Extranasopharyngeal angiofibroma:etiology,incidence and management,"*Acta oto-laryngologica*. 2004;124:880-889.
5. A. Peric,N.Baletic, S. Cerovic et al.,"middle turbinate angiofibroma in an elderly womam," *Vojnosanitetski pregled*. 2009;66:583-586.
6. Gleeson Michael. Juvenil angiofibroma. *Scott-Brown's Otolaryngology, Head and Neck Surgery*, seventh edition. 2008;2:2437-2444.s.
7. V.Starliger, O.Wendler, M. Gramann, and B. Schick, "Laminin expression in juvenile angiofibroma indicates vessel's early developmental stage,"*Acta Otolaryngologica*, vol.127,no. 12,pp.1310-1315, 2007.
8. Dere H, Ozcan KM, Ergul G,Babar S, Ozcan I, Kulacoglu S.Extranasopharyngeal angiofibroma of the cheek. *J Laryngol Otol* 2006;120(2):141-4.
9. Taggarshe D, Quraishi MS, Dugar JM. Inferior turbinate angiofibroma:an atypical presentation. *Rhinology* 2004; 42(1):45-7.
10. Tasca I, Compadretti GC. Extranasopharyngeal angiofibroma of nasal septum. A controversial entity .*ActaOtorhinolaryngol Ital*.2008;28:312-4.
11. Hersh SP, Grimes CD Jr, Harrison WG, Iwamoto T. Angiomyofibroma of the nasal cavity: a clinical and electron micrographic study. *Otolaryngol Head Neck Surg*. 1995;112:603-6.