

When septoplasty will be considered as difficult procedure?

Khalid Mohamed Bofares

Otorhinolaryngology Department, Omar
Almoukhtar University, Elbyda, Libya

Correspondence to Khalid Mohamed Bofares
Tel: +218917455466
e-mail: bofaresstat2012@yahoo.com

Received 9 May 2014
Accepted 16 June 2014
PAN Arab Journal of Rhinology
2014, 4:46–56

Background and objective: Septoplasty is conservative approach to nasal septal surgery. In this operation much of the septal framework is retained. Only the most deviated parts are removed, rest of septal framework is corrected and repositioned by plastic means. For some extent in relation to many factors this surgery may become technically difficult to be performed sufficiently thus subsequently resulting in post-operative morbidities on top of local as well as systemic sequel and complications.

This study was conducted prospectively to evaluate for these variable patterns of difficulties, in relation to patient's demography, patient's health status, septal contour, and surgical technique. In addition, we tried to study the effect of these suggested difficulties on the outcomes of this common surgical procedure in rhinology.

Patients and methods: 663 patients aged 4- 63years of different types of DNS, namely c-shaped, s-shaped, anterior caudal dislocation, and nasal spur with and without external deformities of the nose, presented with variable pictures of clinical presentation of DNS at ENT department – Althowra central hospital and Altarahom private center-Elbyda city –Libya at period in between September 2005 to January 2014 who operated by septoplasty as closed technique. The variable patterns of procedure difficulties were studied and correlated to demographic, anatomical, pathological as well as surgical factors, namely 1) patients age, 2) sex, 3) type of clinical presentation, 4) cause of septal deviation, 5) type of DNS, 6) associated local pathology with deviation 7) recurrent or first attempt of surgery, 8) associated external deformity, and 9) surgical technique which was performed. Patients postoperatively were followed for 3-6 months and assessed for outcomes of the surgery in relation to these recorded difficulties.

Results: 25% of patients who underwent the septoplasty procedure elucidated difficult procedure due to certain factors which could be related to patient's general status, or local pathological circumstance, or surgical technique itself. Those patients followed for 3-6 months and 60% of them shown varieties of local complications ranged from local atrophic changes, to synechia, and septal perforation.

Conclusion: Generally speaking, the septoplasty is not always easy procedure. It might be so difficult that may create a permanent and non-curable postoperative sequel and complications. Thus these possibly appeared difficulties may be overcome by proper preoperative evaluation and preparation of patient, proper decision making, and improvement of our surgical technique in regard.

Keywords: Septoplasty, difficult septoplasty, deviated nasal septum reconstruction, septorhinoplasty, postseptoplasty complications

Introduction

Septoplasty is considered as one of commonest surgical procedures in rhinology. It can be performed either as a solitary or accompanied procedure with other nasal surgical procedures namely turbinate surgery and endoscopic sinus surgery. Hence septoplasty is one of commonest procedures in ENT as general thus it will be always associated with a lot of controversies, many dilemmas, and different issues which need to be studied and clarified. Once the septoplasty is widely and commonly conducted procedure therefore there were unexpected numbers of literatures in relation to different aspects of this procedure [1-7].

The basic concept and the main key point in relation to this procedure are to be as preservative and reconstructive for septal skeleton and related nasal

structures as much as possible. Sometimes because of certain difficulties which may interfere with proper performance of this kind of surgery thus this main goal of septoplasty cannot be achieved [1-10].

Septoplasty is done for the purpose of the correction of deviated nasal septum (DNS) that may be associated with certain conditions which can be considered as indications for this procedure. However the indications of septoplasty may play a significant role in determination of the incidence of these possibly appeared related difficulties, for this reason proper selection of the patient from the indication point of view is necessary to reduce the chance of facing of these difficult circumstances. This procedure has a wide spectrum of indications which simply can be classified into:

- a) The nasal obstructive effect of DNS, and this can be manifested subjectively by complain of the patient as difficult breathing through the nose, persistent mouth breathing, partial or complete loss of normal olfaction, dyspnea with exertion, and recurrent attacks of sore throat. On the other hand, the objective presentation of nasal obstruction is via the elucidation of impaired air flow in the rhinomanometry evaluation as well as demonstration of anosmia or hyposmia in bedside clinical assessment of smell function and by electro-olfactography
- b) Regional mall-ventilation and this is constituted by lack of proper ventilation to the paranasal sinuses, Eustachian tubes, pharyngeal region, and vocal tract
- c) Compressive, tension, and pressure local effect of DNS, as recurrent attacks of epistaxis on top nasal spur due to its persistent vascular tension effect, trigeminal nerve branches compression which may be manifested as trigeminal neuralgia and facial pain, vidian nerve compression which will presented as uncontrolled vasomotor rhinitis, and pressure on lacrimal system and its sequels as recurrent attacks of dacryocystitis
- d) Local pathological effect of DNS, as local persistent atrophic changes, and recurrent local non-specific granulomatous as well as ulcerative disorders
- e) Sequels of loss of proper nasal related pulmonary ventilation function and this can be manifested as recurrent attacks of uncontrolled chest infection and bronchospasm. This is due to persistent mouth breathing on top of DNS and subsequently the lack of sufficient humidification, purification, and rewarming of inspired air through the nose. In addition from the nasal function point of view, the DNS with persistent loss of normal olfaction function is considered as another significant indication for septoplasty
- f) Local as well as regional cosmetic effect of DNS either as co-existing local external nasal deformity, or subsequent oro-facial disfigurements as the result of chronic nasal obstruction and persistent mouth breathing
- g) Systemic sequels and complications of DNS and this mainly related to chronic and persistent hypoxia due to insufficient air flow as uncontrolled systemic hypertension, pulmonary hypertension, pulmonary edema, cor-pulmonaelle, congestive cardiac failure, secondary polycythemia, thromboembolism, cerebrovascular accidents, ischemic heart disease, and sleep related breathing disorders
- h) Septoplasty may be indicated as an approach to other endo-nasal procedures as endoscopic sinus surgery and trans-septal approach to the pituitary gland

Although this procedure is described as one of minor procedures in rhinology among the expert rhinologists but still at certain situations it can be very difficult procedure that may lead to very severe complications which result in permanent loss of normal rhino-sinus related function. These difficulties are mainly confined to the technique itself. However in addition to technical factor there are many other factors which may affect the incidence of appearance of these difficult conditions as demographic patients' characters, the cause and pattern of DNS, the external as well as internal contour of sino-nasal skeleton, and the positive history of previous septoplasty [1-10,13-15,17-19].

From the technique point of view, the septoplasty procedure has classical steps which are well-established and recommended since several decades. In contrary these steps cannot be applied uniformly for all cases of DNS. I.e. there are some cases which described as difficult cases may need to modify these steps accordingly to manage these difficult circumstances [1-12,16,20-25].

Therefore every otolaryngologist should have detailed anatomical and pathophysiological knowledge of the inner nose. The surgeon has to be experienced in the different techniques available today to be able to perform this procedure safely and effectively. The surgeon must be aware that the basic techniques are not sufficient to solve all septum problems. It is the author's intention to point out that it should be avoided that relatively inexperienced surgeons use aggressive surgical procedures and thus produce more harm than benefit. The procedure is particularly demanding if it is integrated into rhinoplasty as it itself can influence the outer aspect of the nose. In rhinoplasty, a good cosmetic result can be achieved by experienced rhinologists from other specializations; however, a good result that considers all cosmetic and functional aspects of the nose can only be obtained by the experienced otolaryngologist [22-25].

On the other hand the most common predisposing factor for DNS is the trauma. The correction of post-traumatic DNS is described as one of significant difficult circumstances of septoplasty procedure. The post-traumatic DNS is usually accompanied with external saddle shaped nasal deformity [19,22]. Won TB, et al stated that establishing a straight and firm septum supporting the overlying nasal structures is the most important step in correcting the post-traumatic combined deviated and saddle nose [19].

There are several trials to modify and improve the surgical techniques of septoplasty procedure just to overcome these possibly occurred associated difficult situations [20-25]. Wee JH, et al, described the importance of septal batten graft to correct cartilaginous deformities in endonasalseptoplasty and they concluded to that endonasal septal batten graft is a safe, useful, and effective technique to straighten moderate to severe septal cartilage deformities that are otherwise not correctable via conventional septoplasty techniques [20].

Even today the difficult septum presents a surgical problem. A severe septum deformity is caused mostly by an accident or is seen in patients with malformation like CLP-deformity. It is characterized by a massive deformation in all levels with a consecutive blocking of one or both airways. Such severe septal deformities cannot be corrected properly by classical septoplasty techniques. Therefore an extracorporalseptoplasty was suggested, where the whole septum is taken out and by different techniques a new septal plate is reconstructed and then replanted [21].

In addition the local preoperative evaluation can be considered as one of the important factors toward the improvement of the techniques of this procedure [22,23]. Corey CL and Most SP mentioned that successful management of posttraumatic nasal obstruction relies on a detailed history, careful analysis, and accurate diagnosis. Dividing the nose into horizontal thirds assists in preoperative analysis as well as surgical treatment. Adequate treatment of posttraumatic nasal obstruction must address deflection of the bony nasal pyramid, septal deformities (especially caudal or dorsal), turbinate hypertrophy, and incompetence of internal and external nasal valves. Treatment must balance the seemingly disparate goals of re-establishing structure, improving contour and esthetics, as well as restoring the nasal airway [22].

The operation of septoplasty is often given to junior surgeons to perform and dismissed as a simple procedure. This can lead to unsatisfactory results with unnecessary morbidity for the patient and disillusionment for the surgeon. Trainee surgeons feel that the operation of septoplasty is poorly taught. Some common problems encountered during septal surgery are described and a variety of surgical solutions are offered [23].

This study was conducted prospectively for these aims:

1. To describe the different patterns of difficult septoplasty
2. To elucidate the different measurements for this difficulty
3. To postulate the importance of this subject
4. To recommend certain precaution as trials to reduce the risk of these possibly occurred difficulties

Patients and methods

663 patients aged 4-63 years of different types of DNS, namely c-shaped, s-shaped, anterior caudal dislocation, and nasal spur with and without external deformities of the nose, presented with variable pictures of clinical presentation of DNS at ENT department - Althowra central hospital and Altarahom private center- Elbyda city -Libya at period in between September 2005 to January 2014 who operated by septoplasty as closed technique. The difficult situations of septoplasty procedure were classified according to different steps of this procedure on top of our practical experience into five groups, group-I was including the cases which were associated with difficult performance of hemi-transfixion incision, group-II was presenting those patients with difficult creation of elevation of septal flaps, group-III was dealing with all patients with difficult status of dissection of lower part of quadrilateral cartilage, group-IV was postulating for those cases with difficult circumstance regarding correction of deformed septal cartilage and/or septal bone, and finally group-V which was elucidating for those cases with difficult situation for preservation of maximum amount of septal cartilage and/or septal bone. There were five objective indicators which used in this serial study as measurements for these difficulties namely, 1) the operative time consumption for the procedure, 2) the intraoperative injuries of septal flaps, 3) the intraoperative induction of septal perforation, 4) the intraoperative palatal injury, and 5) the failure to achieve complete correction of DNS. The variable patterns of procedure difficulties were studied and correlated to demographic, anatomical, pathological as well as surgical factors, namely 1) patients age, 2) sex, 3) type of clinical presentation, 4) cause of septal deviation, 5) type of DNS, 6) associated local pathology with deviation 7) recurrent or first attempt of surgery, 8) associated external deformity, and 9) surgical technique which was performed. Patients postoperatively were followed for 3-6 months and assessed for outcomes of the surgery in relation to these recorded difficulties.

An informed consent was taken from the patients involved in the research prior to their participation.

Data were expressed by using descriptive analysis as means + standard error of mean (s. e. m) and percentages, test of significance was carried out, using Chi-square test and two way analysis of variance.

A probability less than 0.05 was considered as significant, the degree of significance was determined by using level of standard deviation test. Student -t-test was used for dependent sample, as well as contingency coefficient was calculated as measurement of association between nominal variables.

Results

As shown in (Table I) the difficulty to preserve the maximum amount of septal cartilage and bone constitutes the commonest variety of difficulties which associated with septoplasty procedure as compared to other patterns of difficulties. As illustrated in (Table II) the patients of age under 18 years particularly and female patients as general have significantly higher incidence of difficult septoplasty as compared to adult males (P < 0.05). As demonstrated in (Table III) the intraoperative time consumption is significantly increased among difficult septoplasty cases as compared to non-difficult cases (P < 0.05). As can be seen in (Table IV) the incidence of intraoperative complications is significantly raised among difficult septoplasty cases as compared to non-difficult cases (P < 0.05). On the other hand, (Table V) shown that the risk of flap rupture is increased with difficult elevation of septal flaps, while the risk of

septal perforation is increased with difficult elevation of septal flaps as well as difficult preservation of maximum amount of septal cartilage. In accordance the risk of incomplete correction of septal deviation is increased by difficult dissection of septal cartilage as well as difficult correction of deformed cartilage.

(Table VI) demonstrated the risk of post-operative complications in relation to the type of associated difficulty with septoplasty procedure. It was found that the incidence of flap infection and flap necrosis will be increased in association with difficult elevation of septal flaps; in addition the flap hematoma and seroma risk is raised in association with difficulty to preserve the maximum amount of septal cartilage and bone. On the other hand the risk of septal perforation is increased by difficult elevation of septal flaps as well as difficult dissection of septal cartilage. The post-septoplasty external aesthetic nasal changes are significantly associated with difficult preservation of maximum amount of septal cartilage and bone followed by difficult correction of deformed septal cartilage and difficult dissection of septal cartilage consecutively.

Table I Distribution of different patterns of difficult septoplasty procedure

Type of difficulty	No.	%
Performance of hemi-transfixion incision	12	1.8
Elevation of septal flaps	37	5.5
Dissection of septal cartilage	59	8.9
Correction of deformed cartilage	71	10.7
Preservation of maximum amount of septal cartilage and/or bone	84	12.6

Table II Demographic factors distribution namely age and sex in relation to different patterns of difficult septoplasty (P < 0.05)

Type of difficulty	Age		Sex	
	Up to 18	Above 18	M	F
Performance of hemi-transfixion incision	9	3	2	10
Elevation of septal flaps	25	12	5	32
Dissection of septal cartilage	3	56	50	9
Correction of deformed cartilage	0	71	68	3
Preservation of maximum amount of septal cartilage and/or bone	0	84	69	15

Table III The intraoperative time consumption in minutes among difficult septoplasty as compared to non-difficult septoplasty [the mean of intraoperative time consumption among non-difficult cases is 33 ± 2.9 (means \pm standard error)] ($P < 0.05$)

Type of difficulty	Intraoperative time consumption in minutes (means + standard error)
Performance of hemi-transfixion incision	77 ± 3.3
Elevation of septal flaps	83 ± 3.7
Dissection of septal cartilage	92 ± 4.1
Correction of deformed cartilage	101 ± 4.9
Preservation of maximum amount of septal cartilage and/or bone	97 ± 4.3
More than one pattern of difficulty	123 ± 5.2

Table IV The incidence of common intraoperative complications among difficult septoplasty cases as compared to non-difficult cases ($P < 0.05$)

Intraoperative complication	Difficult septoplasty		Non-difficult septoplasty	
	No.	%	No.	%
Flap rupture	150	23	86	13
Septal perforation	6	0.9	0	0
Palatal injury	1	0.016	0	0
Incomplete deviated septum correction	3	0.06	1	0.016

Table V the incidence of common intraoperative complications among difficult septoplasty cases in correlation with type of difficulty

Type of difficulty	Intraoperative complications			
	Flap rupture	Septal perforation	Palatal injury	Incomplete septal deviation correction
Performance of hemi-transfixion incision	7	0	0	0
Elevation of septal flaps	16	0.3	0	0
Dissection of septal cartilage	0	0	0.016	0.5
Correction of deformed cartilage	0	0	0	0.4
Preservation of maximum amount of septal cartilage and/or bone	0	0.6	0	0

Table VI The incidence of common post-operative complications among difficult septoplasty cases in correlation with type of difficulty

Type of difficulty	Post-operative complications				
	Flap infection & flap necrosis	Flap hematoma or seroma or abscess	Septal perforation	Aesthetic external nasal changes	Oro-nasal fistula
Performance of hemi-transfixion incision	0	0	0	0	0
Elevation of septal flaps	0.045	0.016	0.3	0	0
Dissection of septal cartilage	0	0	0.6	0.4	0
Correction of deformed cartilage	0	0	0	0.6	0
Preservation of maximum amount of septal cartilage and/or bone	0	0.6	0	2	0

Discussion

The described difficult situations at this serial study were according to our own practical experience. As we noted that these difficulties increase the incidence of post-septoplasty complications. For this reason we felt at the time of proposing of this study that it is very necessary to discuss these difficulties in relation to their different varieties, and what are the possible recommended measurements to overcome and manage these circumstances?.

In fact there are variable aspects according to which we can classify these difficulties among septoplasty, but as we mentioned before that these difficulties are based mainly up on our own experience from the technique of septoplasty point of view. Therefore as it is well-established that the technical steps of standard septoplasty are eight steps which are: [23]

- a) Infiltration of anterior part of cartilaginous nasal septum by diluted adrenalin solution [adrenalin: normal saline solution (1:100.000{v\ v})]. This will be helpful mainly for hydro-dissection of muco-perichondrial flap
- b) Performance of hemi-transfixion incision at most caudal end of quadrilateral cartilage.
- c) Bilateral elevation of muco-perichondrial as well as muco-periosteal flaps
- d) Preparation of both superior and inferior tunnels.
- e) Dissection of the septal cartilage at its upper and lower parts
- f) Partial or complete resection of the maxillary crest
- g) Minimal remove of septal cartilage and/or septal bone
- h) Correction of the deviation.
- i) Repair of the flap

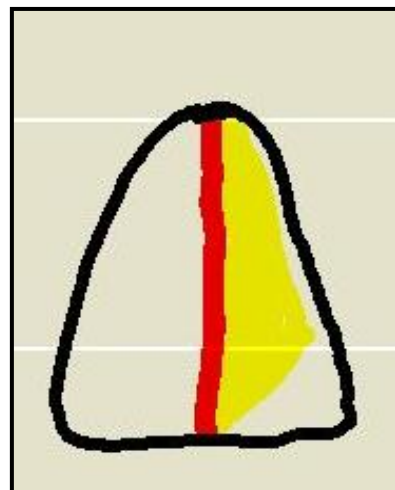
In accordance, the difficulties are classified at this study into five categories:

1. Difficult hemi-transfixion incision performance
2. Difficult elevation of the flap
3. Difficult dissection of the cartilage
4. Difficult complete correction of deformed or displaced septal cartilage or bone
5. Difficult to preserve maximal amount of septal cartilage and/or septal bone.

Hence the performances of hemi-transfixion incision as well as bilateral elevation of flaps are considered as most significant two initial steps in septoplasty because these two steps constitute the corner stone for septoplasty procedure. Thus any difficulties in relation to these two steps will subsequently result in more difficult septoplasty procedure as general and increases the incidence of postoperative complications. From this serial study and according to our experience it was observed that the difficulties in relation to these two steps are coming due to five reasons: I) patients' demography, it was noted that the

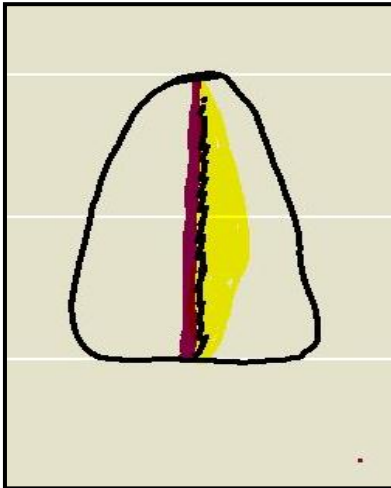
children as general and adult females particular possess more thin flaps which are more susceptible for flap rupture during its elevation as compared to adult males. II) The patients with history of previous septoplasty surgery who are presented for revision septoplasty either due to recurrent septal deviation or due to persistent and residual DNS after first surgery those patients show difficult elevation of septal flaps because of extensive local fibrosis and adhesions. III) As elucidated from figure-1, the sharply and extensively angulated septal cartilage and/or bone will create difficult dissection and elevation of the flap and it may result in rupture of flap either at angulation side or at opposite depression side or at the both. IV) As can be noted from figure-2, the collamellar impaction of most caudal end of quadrilateral cartilage may cause difficulty to perform the proper hemi-transfixion incision. V) The rolled-back deformity of quadrilateral cartilage also may interfere with the possibility of doing of hemi-transfixion incision. This pattern of cartilaginous deformity usually occurs as the result of direct sever blunt trauma to the nose during child-hood which is the developmental age hood. As shown at figure-3, in this type of deformity the caudal end of quadrilateral cartilage will be directed back ward.

Figure 1



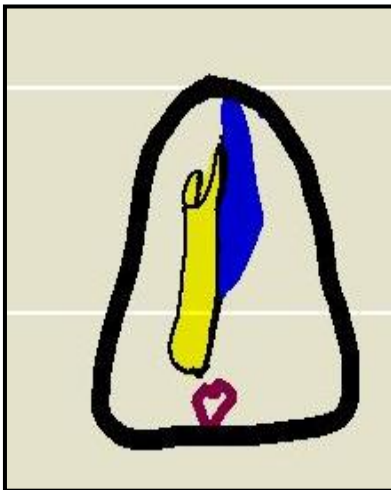
Sharply angulated quadrilateral cartilage

Figure 2



Collamellar impaction of quadrilateral cartilage

Figure 3



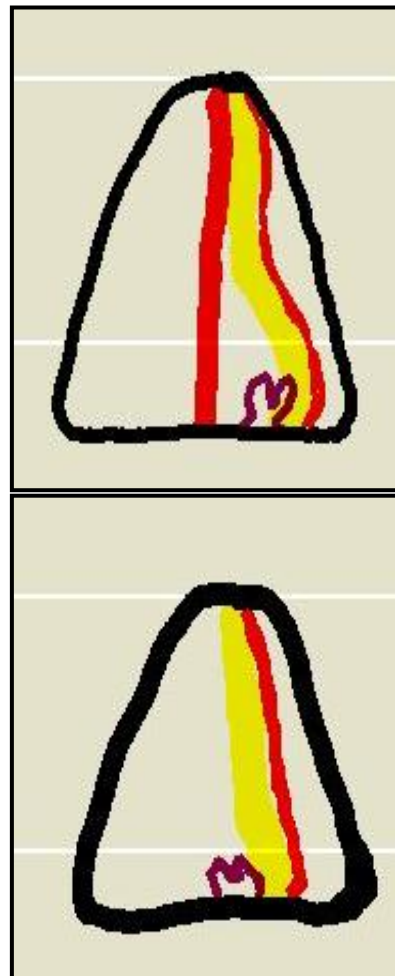
Rolled-back deformed quadrilateral cartilage

On the other hand, the lower dissection of quadrilateral cartilage is considered as another important step in relation to septoplasty procedure because via which the deformed or displaced cartilage will be separated and corrected therefore the main goal of septoplasty procedure will be achieved. It was confirmed from our study that there are certain conditions which present the difficult situations in relation to the separation and correction of deformed or displaced cartilage these situations can be described as five conditions which are:

- I) The lower impaction of quadrilateral cartilage by displaced or non-displaced maxillary crest. As it can be postulated from (Figs. 4,5) this will create a difficult dissection and separation of the quadrilateral cartilage at its lower border

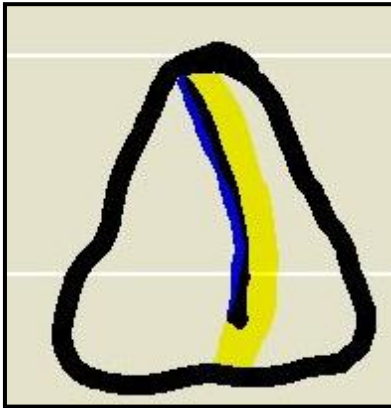
- II) The overlapping of the quadrilateral cartilage with the vomer bone this will lead to difficult dissection as well as correction of the displaced cartilage as can be illustrated from (Fig. 6)
- III) The highly sated maxillary crest due to deeply formed post-traumatic callus beneath to the maxillary crest this will increase the degree of impaction of quadrilateral cartilage by maxillary crest as it is demonstrated at (Fig. 7)
- IV) The lateral impaction of quadrilateral cartilage by highly arched palate as can be seen at (Fig. 8)
- V) The extensive disfigurement of quadrilateral cartilage may interfere with its proper correction and this type of difficulty will be presented as two patterns of cartilaginous deformities which are in form of wavy deformed cartilage and unilateral or bilateral rolled-back deformed cartilage as can be elucidated from figures- 9, 10 and 11 consecutively. (Figs 10,11): unilateral and bilateral rolled-back deformities of quadrilateral cartilage, as shown at figure-10 and 11 consecutively.

Figures 4,5



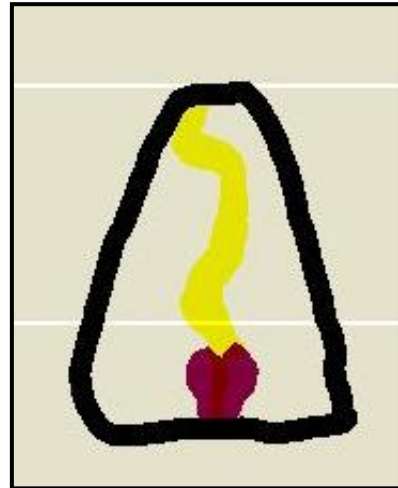Impacted quadrilateral cartilage at its lower part by displaced and non-displaced maxillary crest consecutively

Figure 6



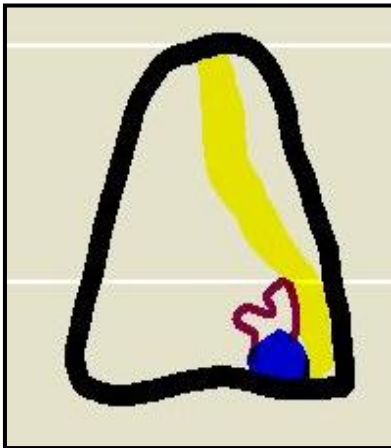
The overlapping of quadrilateral cartilage with vomer bone

Figure 9



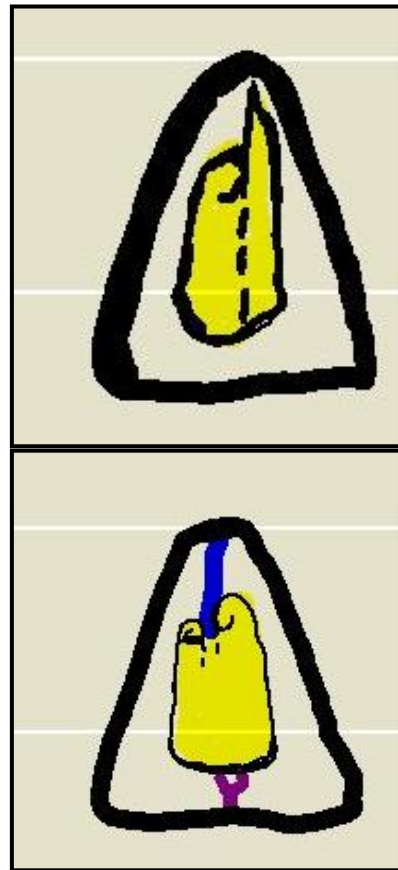
Wavy deformity of quadrilateral cartilage

Figure 7



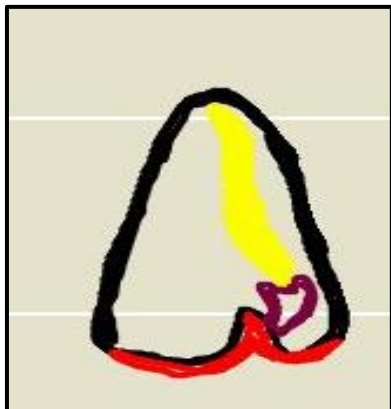highly arched palate with displacement of maxillary crest

Figures 10,11



Unilateral and bilateral rolled-back deformities of quadrilateral cartilage

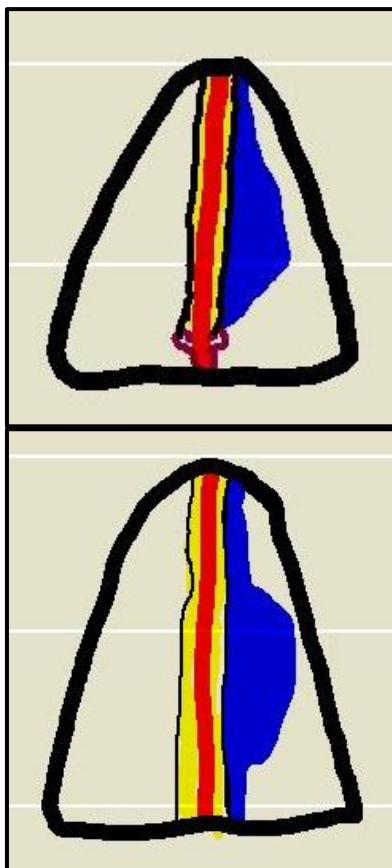
Figure 8



Highly arched palate with displacement of maxillary crest

In accordance, the preservation of maximum amount of septal cartilage and/or septal bone is considered as another significant goal for septoplasty procedure. Sometimes it becomes difficult to obtain this aim. This manner of difficulty comes from four circumstances: I) extensive wavy deformity of quadrilateral cartilage this usually will interfere with maximum preservation of this cartilage during septoplasty. II) Either unilateral or bilateral rolled-back deformities of septal cartilage which needs to remove the rolled deformed cartilaginous parts to achieve maximum correction of the septum. III) Extensive angulation of the vomer bone in form of nasal spur with wide base this will require the resection of this spur with its wide base that may result in the resection of most of vomer bone as can be noted from figure-12. IV) The vomer bone related bony bulge this usually occurs as a result of extensive post-traumatic callus formation as it is shown at figure-13. This bulge occasionally removed with the vomer bone.

Figures 12,13



Vomer related wide based nasal spur and extensive posttraumatic callus

There are five objective indicators which were used as measurements for the difficult septoplasty among this serial study these indicators are: A) time consumption, as it is well-known that by expert rhinologists the standard septoplasty will take from 20 min up to 45 min thus if the time of the procedure exceed this upper limit we will consider the septoplasty as difficult procedure [23]. B) The rupture of flap, mostly this occurs during the performance of flap elevation and this indicates that either the flap is thin as well as friable as in children and adult females, or the flap is tightly adherent to underlying septal cartilage and bone as in cases of previous septoplasty or old traumas with super-occurred septal hematomas, or the flap is covering extensive cartilaginous or bony deformities that interfere with the proper dissection. C) The induction of septal perforation, at certain difficult circumstances which are usually related to flap elevation, septal cartilage dissection and/or vomer bone resection there will be high incidence during the performance of these steps to induce intra-operative septal perforation and hence the procedure is already conducted by expert rhinologist therefore this sequel can be used as strong objective indicator for difficult procedure. D) The induction of palatal injury, this intra-operative complication occurs usually in association with highly arched palate which is susceptible for its injury during the process of dissection of the lower part of quadrilateral cartilage and resection of maxillary crest, or it may happen as the result of dissection of deeply impacted maxillary crest. E) The failure to achieve a complete correction of DNS is considered as another significant indicator for difficult septoplasty procedure among expert hands.

On the other hand, we consider this serial study as important issue because difficult septoplasty means high incidence of postoperative persistent and difficult to be managed sequels and complications namely; flap infection, flap necrosis, septal cartilage necrosis, septal bone necrosis, septal hematoma, septal abscess, septal perforation, external aesthetic changes as supra-tip depression deformity, saddle nose deformity, and humped nose deformity, in addition oro-nasal fistula, and residual DNS. Hence these complications are associated with persistent local handicapping of nasal function thus the best way is the prevention of occurrence of these complications by proper dealing and interference with these possibly suggested septoplasty related difficult situations.

Lastly, on top of our own experience, we would like to give certain recommendations to overcome these possibly faced difficulties in association with septoplasty procedure. These recommendations can be summarized as five points:

- a) Proper local infiltration of adrenalin: xylocain: normal saline diluted solution, this will be helpful for creation of sufficient hydro-dissection of the mucoperichondrial flaps bilaterally therefore this will give a plane for proper and safe elevation of the mucoperichondrial as well as muco-periosteal flaps [4,12,23].
- b) Preparation of enough sized inferior tunnels, this will give a sufficient access for the region of maxillary crest as well as the most lower part of quadrilateral cartilage thus this will facilitate the performance of the steps of dissection of lower part of septal cartilage, partial or complete resection of maxillary crest, resection of co-existing post-traumatic callus around the maxillary crest, and safe dissection around highly arched palate [20-25].
- c) If the quadrilateral cartilage is overlapping with the vomer bone it is recommended to separate the bone from the cartilage before its resection this will protect the cartilage from its resection with the bone and subsequently this will maintain the contour of continuity of nasal septum therefore the risk of septal perforations will be minimized [20-25].
- d) In the cases of extensive septal cartilage deformities as wavy or rolled-back deformities when it becomes difficult to preserve the cartilage thus for the purpose of achievement of main septoplasty procedure goal by the preservation of maximum amount of septal cartilage it is recommended to divide and split this deformed cartilage into small fragments which will be covered and supported by the septal flaps and subsequently this will be helpful for maintenance of the contour of continuity of nasal septum in addition this will reduce the risk of postoperative external aesthetic change by preservation of maximum amount of septal cartilage and bone [20].
- e) The application of splints, it was found to be helpful from three aspects [26-35]:
 1. The splints will give a support for already injured flap at its most posterior part which is difficult to be repaired therefore the injury edges of the flap will be maintained approximated by the applied splints
 2. The splints will provide a support for the cartilaginous small fragments which already produced by the dividing and splitting of extensively wavy or rolled-back or angulated septal cartilage these applicable splints will maintain the septal flaps over these supported

fragments for enough time until a complete healing process is finished

3. After the dissection of lower part of quadrilateral cartilage and particularly after the resection of maxillary crest the cartilage will become floppy and weakly supported this will increase the risk of its re-displacement and recurrence of the septal deviation for this reason the application of splints will be of beneficial effect for supporting of the cartilage for sufficient period until the complete healing is obtained.

We can conclude to that the septoplasty is not always easy procedure. It might be so difficult that may create a permanent and non-curable postoperative sequels and complications. Thus these possibly appeared difficulties may be overcome by proper preoperative evaluation and preparation of patient, proper decision making, and improvement of our surgical technique in regard. As this procedure is considered as one of common procedures in ENT as general and in rhinology particular therefore further related studies are required frequently to be conducted to resolve and clarify different aspects and issues which are related to this significant kind of surgical procedures.

References

1. Becker SS, Dobratz EJ, Stowell N, Barker D, Park SS. Revision septoplasty: review of sources of persistent nasal obstruction. *Am J Rhinol* 2008; 22:440-4. doi: 10.2500/ajr.2008.22.3200.
2. Constantian MB, Clardy RB. The relative importance of septal and nasal valvular surgery in correcting airway obstruction in primary and secondary rhinoplasty. *Plast Reconstr Surg* 1996; 98:38-54; discussion 55-8.
3. Posnick JC, Fantuzzo JJ, Troost T. Simultaneous intranasal procedures to improve chronic obstructive nasal breathing in patients undergoing maxillary (Le Fort I) osteotomy. *J Oral Maxillofac Surg* 2007; 65:2273-81.
4. Sillers MJ, Cox AJ 3rd, Kulbersh B. Revision septoplasty. *Otolaryngol Clin North Am*. 2009; 42:261-78, viii. doi: 10.1016/j.otc.2009.01.014.
5. Sedwick JD, Lopez AB, Gajewski BJ, Simons RL. Caudal septoplasty for treatment of septal deviation: aesthetic and functional correction of the nasal base. *Arch Facial Plast Surg* 2005; 7:158-62.
6. Busaba NY, Hossain M. Clinical outcomes of septoplasty and inferior turbinate reduction in the geriatric veterans' population. *Am J Rhinol* 2004; 18:343-7.

7. Becker DG, Becker SS. Treatment of nasal obstruction from nasal valve collapse with alar batten grafts. *J Long Term Eff Med Implants*. 2003; 13:259-69.
8. Veit J, Rotter N, Feucht A, Rettinger G, Scheithauer M. [Persistent nasal obstruction following septoplasty: deviated nasal pyramid and perpendicular plate]. *Laryngorhinootologie* 2012; 91:363-7. doi: 10.1055/s-0032-1309019. Epub 2012 Apr 4. German.
9. Lanfranchi PV, Steiger J, Sparano A, Brigandi L, Lin G, Becker SS, Becker DG. Diagnostic and surgical endoscopy in functional septorhinoplasty. *Facial Plast Surg* 2004; 20:207-15.
10. Paccoi P, Di Peco V. Septal cartilage graft for nasal valve incompetence associated with deviated septum. *Am J Rhinol* 2007; 21:622-5.
11. Kim JH, Kim DY, Jang YJ. Outcomes after endonasal septoplasty using caudal septal batten grafting. *Am J Rhinol Allergy* 2011; 25:e166-70. doi: 10.2500/ajra.2011.25.3648.
12. Chung BJ, Batra PS, Citardi MJ, Lanza DC. Endoscopic septoplasty: revisitation of the technique, indications, and outcomes. *Am J Rhinol* 2007; 21:307-11.
13. Kim DH, Park HY, Kim HS, Kang SO, Park JS, Han NS, Kim HJ. Effect of septoplasty on inferior turbinate hypertrophy. *Arch Otolaryngol Head Neck Surg* 2008; 134:419-23. doi: 10.1001/archotol.134.4.419.
14. Su YF, Sun XZ, Liu YX, Yu S, Wang JZ, Su F. Effect of septoplasty or in combination with out fracture of the inferior turbinate on the airflow field and nasal airway. *Zhonghua Er Bi Yan Hou Tou Jing Wai Ke Za Zhi* 2011; 46:96-100. Chinese.
15. Kemker B, Liu X, Gungor A, Moinuddin R, Corey JP. Effect of nasal surgery on the nasal cavity as determined by acoustic rhinometry. *Otolaryngol Head Neck Surg*. 1999 Nov; 121(5):567-71.
16. Neruntarat C. Laser-assisted outpatient septoplasty and laser-assisted uvulopalatoplasty for nasal obstruction and snoring. *J Med Assoc Thai*. 2005; 88 Suppl 1: S66-72.
17. Jun BC, Kim SW, Kim SW, Cho JH, Park YJ, Yoon HR. Is turbinate surgery necessary when performing a septoplasty? *Eur Arch Otorhinolaryngol* 2009; 266:975-80. doi: 10.1007/s00405-008-0855-x. Epub 2008 Nov 11.
18. Stewart MG, Smith TL, Weaver EM, Witsell DL, Yueh B, Hannley MT, and Johnson JT. Outcomes after nasal septoplasty: results from the Nasal Obstruction Septoplasty Effectiveness (NOSE) study. *Otolaryngol Head Neck Surg* 2004; 130:283-90.
19. Won TB, Kang JG, Jin HR. Management of post-traumatic combined deviated and saddle nose deformity. *Acta Otolaryngol* 2012; 132 Suppl 1: S44-51. doi: 10.3109/00016489.2012.659757.
20. Wee JH, Lee JE, Cho SW, Jin HR. Septal batten graft to correct cartilaginous deformities in endonasal septoplasty. *Arch Otolaryngol Head Neck Surg* 2012; 138:457-61. doi: 10.1001/archoto.2012.650.
21. Gubisch W. [20 years' experience with extracorporeal septoplasty]. *Laryngorhinootologie* 2002; 81:22-30.
22. Corey CL, Most SP. Treatment of nasal obstruction in the posttraumatic nose. *Otolaryngol Clin North Am* 2009; 42:567-78. doi: 10.1016/j.otc.2009.03.002.
23. Marshall AH, Johnston MN, Jones NS. Principles of septal correction. *J Laryngol Otol*. 2004; 118:129-34.
24. Carroll T, Ladner K, Meyers AD. Alternative surgical dissection techniques. *Otolaryngol Clin North Am* 2005; 38:397-411.
25. Fjermedal O, Saunte C, Pedersen S. Septoplasty and/or submucous resection? 5 years nasal septum operations. *J Laryngol Otol* 1988; 102:796-8.
26. Shone GR, Clegg RT. Nasal adhesions. *Journal of Laryngology and Otology* 1987; 101:555-57.
27. White A, Murray JA. Intranasal adhesions formation following surgery for chronic nasal obstruction. *Clinical Otolaryngology* 1988; 13:139-43.
28. Guyuron B. Is packing after septorhinoplasty necessary? A randomized study. *Plastic Reconstr Surg* 1989; 84:41-44.
29. Eliopoulos PN, & Phillippakis C. Prevention of post-operative intra-nasal adhesions (a new material). *J. Laryngol. Otol* 1989; 103:664-66.
30. Cook AC, Murrant NJ, Evans KL, Lavelle RJ. Intra-nasal splints and their effects on intra-nasal adhesions and septal stability. *Clinical Otolaryngology* 1992; 17:24-27.
31. Gilchrist AG. Surgery of the nasal septum and pyramid. *J. Laryngol. Otol*. 1974; 88:759-71.
32. Campbell JB, Watson MG, & Sheno PM. The role of intranasal splints in the prevention of post-operative nasal adhesions. *J. Laryngol. Otol*. 1987; 101:1140-43.
33. Von Schoenberg M, Robinson P, Ryan R. The morbidity from nasal splints in 105 patients. *Clinical Otolaryngology* 1992; 17:528-30.
34. Wagner R, Toback JM. Toxic shock syndrome following septoplasty using plastic nasal splints. *Laryngoscope* 1986; 96:609-10.
35. Malki D, Quine SM, Pfeleiderer AG. Nasal splints, revisited. *The Journal of Laryngology and Otology*. 1999; 113:725-27.