



## Original Article

### Surgical outcomes for Rhinogenic contact point headache

**Hazem M. Abdel Tawab, Fadi M. Gharib, Sherif A. Raafat, Mohamed H. Mohamed**

Otorhinolaryngology Department, Faculty of Medicine, Cairo University

Correspondence to: Hazem M. Abdel Tawab, Email: hazemabdeltawwab77@yahoo.com

**Objectives:** Investigate the role of some anatomical variations of the nose in rhinogenic contact point headache and to evaluate the role of surgery in management of such headache.

**Patients and Methods:** study included twenty patients from July 2013 till October 2013 with rhinogenic contact headache of more than one year duration. Evaluation of surgical management for these cases was done as regards improvement of headache duration, intensity and frequency over a follow up period of three months at least after the operation.

**Results:** twenty patients were included with ages ranging from 19 to 45 years, eleven of them were males and nine were females. Sixteen cases showed complete cure, 2 showed improvement and 2 showed unsatisfied results. Deviated septum was found in 16 cases (80%), hypertrophied middle turbinate in 9 patients (45%), concha bullosa in 6 patients (30%) and hypertrophied inferior turbinate in 5 patients (25%). More than one anatomical variation was encountered in most of the cases. The two failed cases showed pre-operative long duration since they started to complain from headache and longer duration of each headache attack, one of them was post-menopausal and the other was on psychiatric medications started after the operation.

**Conclusion:** intra nasal anatomical variations play a role in pathogenesis of contact rhinogenic headache and the surgical treatment of these anatomical variations succeeded in eliminating or significantly reducing the contact headache. Key words anatomical variations, contact headache, rhinogenic.

**Keywords:** Anatomical variations, contact headache, rhinogenic.

## INTRODUCTION

Patients with facial pain present a diagnostic challenge. Difficulties in management arise because of the frequency of referred pain and the overlap in symptoms between different conditions. Painful stimuli affecting facial structures are mostly transmitted via afferents in the trigeminal nerve to the spinal tract in the brain stem.<sup>(1)</sup>

Stimulation of the lateral wall of the nose through contact between middle turbinate and nasal septum in cases of severely deviated nasal septum, enlarged pneumatized middle turbinate (concha bullosa), or medially displaced

middle turbinate by enlarged ethmoidal bulla produce contact edema between mucosal surfaces and release of pain mediators resulting in pain radiating along nerve fibers.<sup>(2)</sup>

The middle turbinate in close proximity to other mucosal surfaces has been implicated as a possible cause of the contact point rhinogenic pain. Surgical removal appears to provide relief in appropriately selected patient's population.<sup>(3)</sup>

The commonest surgical modality used for management of headache is submucous resection of nasal septum and

partial middle turbinectomy. Due to the debates regarding this problem, this study was conducted to evaluate the effect of various anatomical structures in the pathogenesis of headache and the outcomes of its surgical management.

## PATIENTS AND METHODS

This study included 20 patients with refractory or resistant headache for more than one year. They were admitted in Otorhinolaryngology Department, Faculty of Medicine, Cairo University in the period from July 2013 to October 2013.

All the patients were subjected to full history taking stressing on the duration of complaint and any associated symptoms. All the patients were examined through anterior rhinoscopy, nasal endoscopy after decongestion of the nasal mucosa to facilitate examination to comment on the nasal anatomical variations that may cause contact headache. Local anesthetic test was done for every patient to confirm contact point presence and was repeated for three times to avoid false negative results.

Medical treatment as decongestant nasal drops, antibiotics, antihistamines and occasionally topical steroids was given to patients and sometimes repeated if no response in the first course. Axial and coronal computed tomography (CT) was done for the nose and sinuses after medical treatment.

### Inclusion criteria for surgical interference to treat this headache were:

- Duration of headache more than one year.
- Patient not responding to several trials of medical treatment (at least three courses).
- Presence of contact between part of the lateral wall of the nose and septum on clinical and endoscopic examination and in C.T. images.
- Positive local anesthesia test.

### Exclusion criteria were:

- Short duration of headache less than one year.
- Patient is cured with medical treatment.
- Contact between the lateral wall of the nose and the nasal septum is not confirmed by either clinical, endoscopic or CT imaging.
- Negative local anesthesia test.

Endoscopic surgery with removal or correction of the anatomical variation that caused headache according to endoscopic examination and CT scan was done.

Patients were followed on weekly basis in the first month, monthly basis after that for another two months.

- Data regarding headache severity, frequency and duration were specifically emphasized. All patients were asked to quantify the frequency, duration, and intensity of their headache pre- and post-operatively. Patient was considered cured if the duration and frequency of attacks were abolished after the operation, patient was considered improved if duration and frequency of attacks were diminished for at least 50% of the pre-operative state, and otherwise failure was considered.

- Intensity was rated subjectively on a scale of 0 (no headache or pain) to 10 (worst headache or pain ever) (Fig. 1).

Cure as regards intensity of headache was considered if the patient did not complain of headache at all (score 0), improvement was considered if the patient showed a score 4-5 while failure was considered if the patient gave a score of 8-10 post operatively.

In every office visit patients underwent nasal endoscopy. Post-operative axial and coronal CT was done for each patient after 3 months from the operation.

Data were statistically analyzed using percentage scores for the results found in the study.

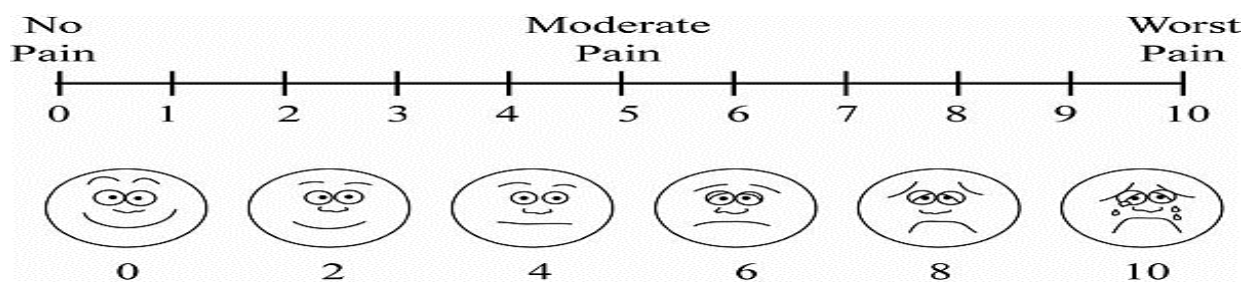


Fig 1 Headache and pain scale used in the study.

**RESULTS**

This study included 20 patients complaining of contact headache of at least one year duration and resistant to medical treatment. Their ages ranged from 19 to 45 years

with mean age of  $31.85 \pm 8.53$  years. Eleven of them were males (55%) and nine were females (45%). Duration of headache is shown in Table 1.

**Table 1 Duration of headache in the patients included in the study**

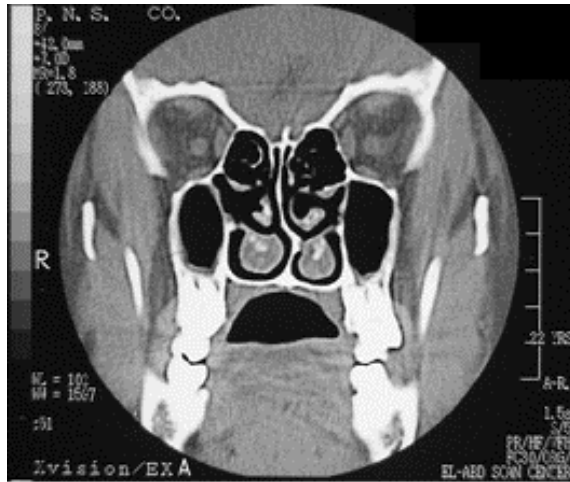
Case Number	Duration in Years	Case Number	Duration in Years	Case Number	Duration in Years	Case Number	Duration in Years
1	5	6	5.5	11	5.5	16	5
2	2.5	7	8	12	5	17	5
3	3.5	8	2.5	13	5	18	5
4	4	9	8	14	4	19	6
5	4	10	6	15	4	20	1

Frequency of the anatomical variations as seen by endoscopic examination or CT scanning is shown in Table 2. More than one finding co-existed in the most of

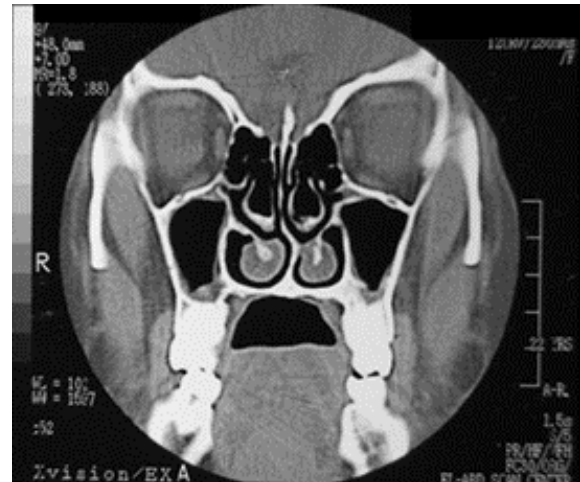
the patients. It appears that deviated nasal septum was the commonest anatomical variation seen in this study.

**Table 2 Frequency of anatomical variation findings in the cases of the study**

Finding	Number of patients	Percentage
Deviated septum (DS) (Fig. 2)	16	80%
Hypertrophied middle turbinate (HMT)	9	45%
Concha bullosa (CB) (Fig. 3)	6	30%
Double middle turbinate (DMT)	1	5%
Paradoxical middle turbinate (PMT)	1	5%
Hypertrophied inferior turbinate (HIT)	5	25%



**Fig 2 Deviated nasal septum to the left side with contact with the left inferior turbinate.**



**Fig 3 Bilateral concha bullosa.**

The surgical procedures done in the study according to pathology is shown in Table 3.

**Table 3 Surgical procedures done in the study**

Case number	CT finding	Procedure done
1	DS+ HIT	Septoplasty + partial inferior turbinectomy
2	DS+HMT	Septoplasty+ Partial middle turbinectomy
3	DS+CB	Septoplasty+ Removal of the lateral lamella of middle turbinate
4	DS+HMT	Septoplasty+ Partial middle turbinectomy
5	DS+CB	Septoplasty+ Removal of the lateral lamella of middle turbinate
6	DS+HMT	Septoplasty+ Partial middle turbinectomy
7	DS+CB	Septoplasty+ Removal of the lateral lamella of middle turbinate
8	DS+HMT	Septoplasty+ Partial middle turbinectomy
9	DS+HMT	Septoplasty+ Partial middle turbinectomy
10	HMT	Partial middle turbinectomy
11	CB+HIT	Removal of the lateral lamella of middle turbinate + Partial inferior turbinectomy
12	DS+PMT	Septoplasty+ Partial middle turbinectomy
13	DS+HIT	Septoplasty+ Partial inferior turbinectomy
14	DS+HMT	Septoplasty+ Partial middle turbinectomy
15	DS+HMT	Septoplasty+ Partial middle turbinectomy
16	DS+HIT	Septoplasty+ Partial inferior turbinectomy
17	CB+HIT	Removal of the lateral lamella of middle turbinate + Partial inferior turbinectomy
18	DS+DMT	Septoplasty+ Partial middle turbinectomy
19	CB	Removal of the lateral lamella of middle turbinate
20	DS+HMT	Septoplasty+ Partial middle turbinectomy

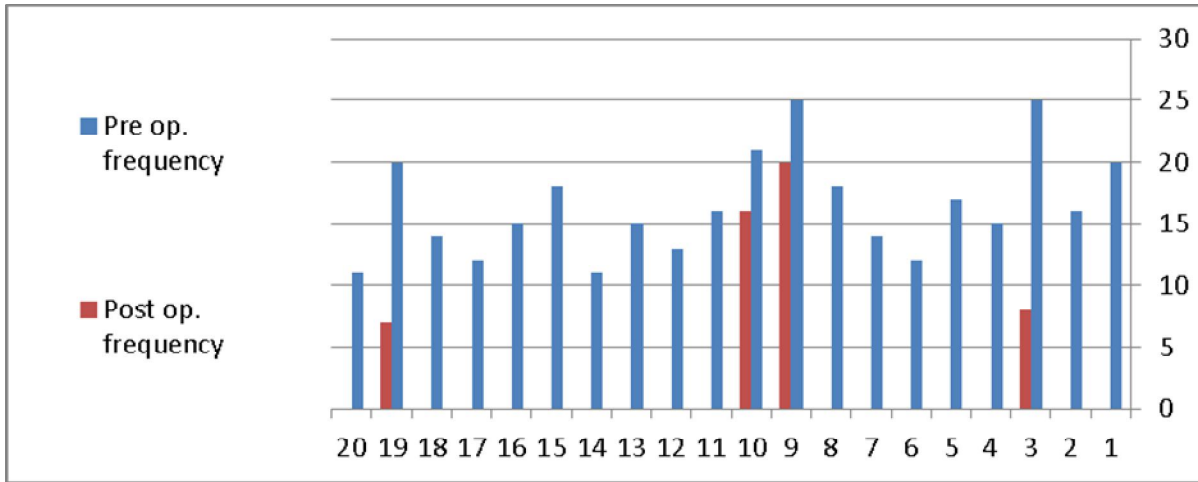
**Surgical outcomes for Rhinogenic contact point headache**

From the data collected after surgery, septoplasty was done in 80% of cases, partial middle turbinectomy in 45%, partial inferior turbinectomy in 25% and removal of lateral lamella of the middle turbinate in 30% of cases.

In the current study, the twenty patients were operated upon and 18 cases (90%) showed improvement or complete cure, 16 cases of them (80%) showed complete

cure, while 2 cases (10%) showed improvement only. Two cases (10%) showed failure.

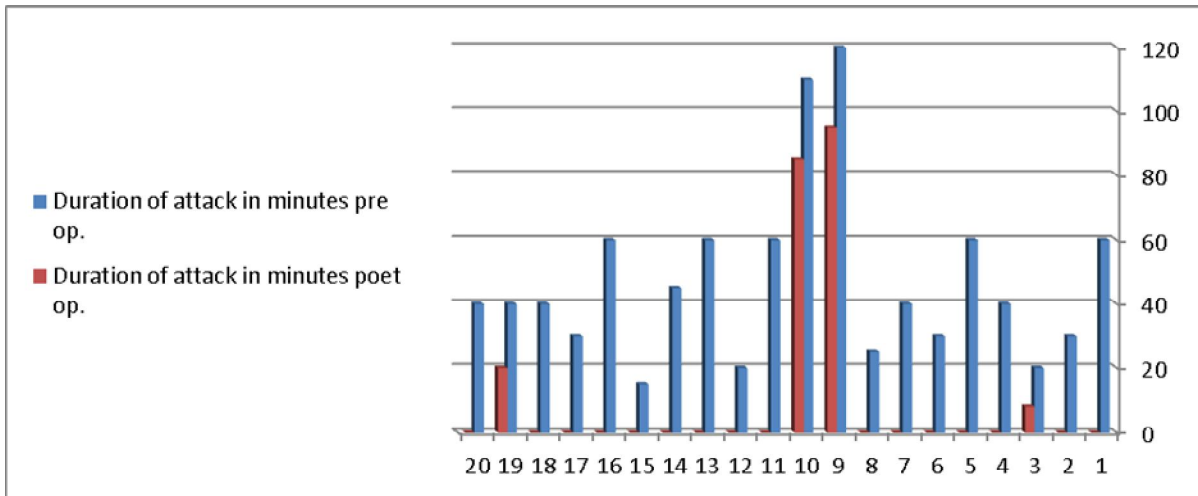
As regards frequency of headache attacks (Fig. 4), sixteen patients were cured and showed no attacks at all after the operation, two patients showed marked improvement as the attacks decreased to more than 50% of their original frequency preoperatively. Two cases failed and were complaining from headache in almost near the same number of attacks as their preoperative condition.



**Fig 4 Frequency of headache attacks pre- and post-operatively.**

As regards the duration of headache attack (Fig. 5), sixteen patients showed complete resolution while two cases showed diminution of the attack duration to about the

half. The last two cases showed almost near the same duration as before the operation.



**Fig 5 Duration of the headache attack in minutes pre- and post-operatively.**

As regards headache intensity, sixteen cases showed score (0) after the operation which means complete cure. Two patients showed a score of<sup>(4-5)</sup> which means improvement. The remaining two cases showed a score within<sup>(8-10)</sup> meaning failure after the operation.

One of the two failed cases was a female of 45 years old, with the history of headache of 8 years and long duration of every headache attack and she was discovered to start her menopause period. The other case was a male patient of 39 years old with the history of headache of 6 years and long duration of the headache attack also. This patient was found to be on psychiatric medication which started after procedure for unrelated cause. This suggests that longer duration of the complaint and longer duration of the attack can constitute the major causes of failure of these two cases. Also the patients should be followed for any other factors that may happen post operatively and endanger the results of the operation like menopause or psychiatric factors or any other cause unrelated to the procedure.

## DISCUSSION

Over years, many theories had been proposed to explain the pathophysiology of headaches with a possible nasal origin until the advent of nasal endoscopy and computed tomography (CT) has greatly challenged this problem.<sup>(4)</sup>

Besides their resistance to ordinary medical measures, contact point headache patients usually show underlying endoscopic and/ or radiological sinonasal changes in the form of anatomic variations and/ or mucosal disease.<sup>(5)</sup>

Many sinonasal anatomical variations might predispose to headache by narrowing the already narrowed ethmoidal recesses. Only contact of opposing mucosal surfaces may impede the ventilation and drainage of sinuses that serves as a mechanical stimulus for referred pain.<sup>(6)</sup>

In this study, examination of patients during the headache attack showed that mucosal contact was present between the septum and a part of the lateral wall of the nose in all the cases. This matches with Clerico et al., study in 1996 who reported that septal- turbinate contact implies that the pathologic process in rhinogenic headache is in the nasal rather than the sinus cavity.<sup>(7)</sup>

By clinical and endoscopic examination we found that various anatomical variations had been implicated as possible causes of rhinogenic headache in absence of sinusitis. In this issue, deviated nasal septum (80%) of cases and different types of middle turbinate variations (85%) were the commonest causes. This matches with the studies of Saunte and Soyka in 1993<sup>(8)</sup> and Ramadan in 2007<sup>(9)</sup> who reported patients with headache secondary to septal deviation.

The encountered middle turbinate variations in this study included hypertrophied middle turbinate (45%), concha bullosa (30%), paradoxical middle turbinate (5%) and double middle turbinate (5%). This matches with the study of Saunte and Soyka in 1993<sup>(8)</sup> and the study of Clerico and Fieldman in 1994.<sup>(10)</sup>

Large concha bullosa was encountered in 30% of cases in this study. This shows that it plays an important role in the mucosal contact causing headache. This matches with Stammberger and Wolf in 1988<sup>(6)</sup> but comes in contrast to the study of Yousem et al in 1991 who denied this conclusion.<sup>(11)</sup>

Paradoxical middle turbinate (5%) and double middle turbinate (5%) were encountered in this study. These form uncommon pathologies and this finding matches with Stackpole and Edelstein study in 1996.<sup>(12)</sup>

Hypertrophied inferior turbinate was encountered in 25% of cases in this study and this finding matches with the studies of Greenfield in 1990 and 1991.<sup>(13,14)</sup>

In this study, almost all the cases with deviated septum (80%) were cured or improved after septoplasty and this matches with the study of Clerico in 1995 who reported 30 patients of headache improved after surgical septal correction.<sup>(15)</sup>

In this study, almost all the cases with hypertrophied middle turbinate (45%) were cured or improved after partial middle turbinectomy and this matches with the study of Saunte and Soyka in 1993<sup>(8)</sup> and Clerico et al., in 1996<sup>(7)</sup> who reported 40 patients with headache completely improved after surgical correction of hypertrophied middle turbinate.

In this study, all the cases with hypertrophied inferior turbinates (25%) were cured after partial inferior turbinectomy and this matches with the studies of Greenfield in 1990 and 1991.<sup>(13,14)</sup>

Surgical correction of cases with concha bullosa in this study (30%) had relieved the headache and this matches with Stammberger study in 1991 who reported 10 patients with headache improved after surgical correction of concha bullosa.<sup>(2)</sup>

Correction of double middle turbinate (5%) and paradoxical middle turbinate (5%) in this study had relieved the headache matching with studies of Stackpole and Edelstein in 1996<sup>(12)</sup> and Clerico et al., in 1996.<sup>(7)</sup>

In this study, headache intensity, frequency and duration of the attack had totally cured in sixteen cases, improved to its half or less in two cases while two cases showed failure of improvement as regards the three parameters.

## Surgical outcomes for Rhinogenic contact point headache

The two failed cases showed very long history of headache and longer duration of every single attack of headache which gives an idea about the relation of headache improvement after surgery with its duration prior to surgery. As the duration of headache complaint or the duration of every attack increases, it will be unlikely for the headache to be cured after surgery.

Also, any changes affecting the social, psychiatric and physical conditions of the patient after surgery can endanger the results of surgery as one of the failed cases started her menopause one month after the operation while the other started medications for psychiatric purposes after the operation which might contribute as causes of failure in these two conditions.

## CONCLUSION

Nasal anatomical variations play an important role in the development of contact rhinogenic headache and this headache can be cured or significantly improved after surgical correction of the deformities encountered in every single case.

Longer history of headache complaint and longer duration of the attacks of headache largely contribute to the failure of the surgical procedures done. Exclusion of any social, physical or psychological changes that affect the patient post operatively is mandatory to have clear results regarding improvement after surgery.

**Conflicts of Interest:** There were no conflicts of interest encountered in this study.

## REFERENCES

1. Blau NJ. A plain man's guide to the management of migraine. *British Medical Journal*. 1982;28:1095-7.
2. Stammberger H. *Functional Endoscopic Sinus Surgery*. Philadelphia: B. C. Decker. 1991.
3. Landrigan GP and Kirkpatrick DA. Intranasal xylocaine: a prognostic aid for preoperative assessment of facial pain of nasal origin. *J Otolaryngol*. 1992;21:126-8.
4. Clerico DM. Rhinopathic headaches: Referred pain of nasal and sinus origin. In: *Diseases of the sinuses*. Greshwin ME., Incaudo G., eds., Humana Press Inc., Totowa, NJ. 403-23.
5. Novak VJ and Makek M. Pathogenesis and surgical treatment of migraine and neurovascular headaches with rhinogenic trigger. *Head and Neck*. 1992;14:467- 72.
6. Stammberger H and Wolf G. Headache and sinus disease: The endoscopic approach. *Ann Otol Rhinol Laryngol*. 1988;97:3-23.
7. Clerico DM, Grabo DJ, Goldberg A. The mucosal contact theory of migraine: radiographic, histologic & clinical evidence. Presented at the 42nd annual scientific meeting of the American Rhinologic Society. 1996;28, Washington DC.
8. Saunte C and Soyka D. Headache related to ear, nose and sinus disorder. In: Olesen, J.; Tfelt- Hansen, P.; Welch, K.M.A., eds., *The Headaches*, New York, Raven. 1993;753-7.
9. Ramadan H. Non-surgical versus endoscopic sinonasal surgery for rhinogenic headache. *Am J*. 2007;13:455- 7.
10. Clerico DM and Fieldman RF. Referred headache of rhinogenic origin in the absence of sinusitis. *Headache*. 1994;34:226- 9.
11. Yousem DM, Kennedy DW and Rosenberg S. Ostiomeatal risk factors for sinusitis: CT evaluation. *J Otolaryngol*. 1991;20:419-24.
12. Stackpole SA and Edelstein DR. Anatomic variants of the paranasal sinuses and their implications for sinusitis. *Curr Op Otolaryngol Head Neck Surg*. 1996;4:1-6.
13. Greenfield HJ. Headache and facial pain associated with nasal and sinus disorders: a diagnostic and therapeutic challenge. Part 1. *Insights Otolaryngol*. 1990;5:2-8.
14. Greenfield HJ. Headache and facial pain associated with nasal and sinus disorders: a diagnostic and therapeutic challenge. Part 11. Clinical application. *Insights Otolaryngol*. 1991;6:2-8.
15. Clerico DM. Sinus headaches reconsidered: referred cephalgia of rhinologic origin masquerading as refractory primary headaches. *Headache*. 1995;35:185-92.