

The clinical efficacy of septoplasty and inferior turbinate reconstruction in unilateral atrophic rhinitis

Ossama M. Mady, Ahmed M. Maarouf, Ahmed A. Teaima

Department of Otorhinolaryngology, Faculty of Medicine, Ain Shams University, Cairo, Egypt

Correspondence to Ossama M. Mady, MD, Lecturer of otorhinolaryngology, Ain shams university, 62 C, Gardenia Heights 3, 5th Settlement, New Cairo, 11566, Egypt. e-mail: omady84@gmail.com

Received 09 October 2020

Revised 22 November 2020

Accepted 05 December 2020

Published 09 August 2021

Pan Arab Journal of Rhinology

2021, 11:43–46

Introduction

Atrophic rhinitis (AR) is a chronic disease affecting nasal mucosa and turbinates. Patients with AR mainly present with nasal obstruction, fetor, nasal discharge, anosmia, epistaxis, and excessive crustations. AR may be primary or secondary. One of the causes of secondary AR is the markedly deviated nasal septum. Incidence of AR varies from 0.3 to 1% of population.

Objectives

Our aim was to study the effect of septoplasty and inferior turbinate reconstruction with the autogenous septal cartilage in the management of secondary AR due to deviated nasal septum.

Patients and methods

The study was done on 13 patients. Sino-Nasal Outcome Test-25 (SNOT-25) was estimated preoperative and at 3, 6, and 12 months postoperatively. Septoplasty and usage of autogenous septal cartilage for reconstruction of inferior turbinate were done.

Results

The results were significant and showed dramatic improvement in SNOT-25 and quality of life, with no complications during 12 months postoperatively.

Conclusion

Surgical correction of secondary AR, due to deviated nasal septum, by septoplasty and inferior turbinate reconstruction with autogenous cartilage had good effect on SNOT-25 and quality of life, with no complications.

Keywords:

atrophic rhinitis, septoplasty, turbinate reconstruction and nasal crustation

Pan Arab J Rhinol 11:43–46

© 2021 2090-7640

Introduction

Atrophic rhinitis (AR) is a chronic progressive disease, characterized by atrophy of nasal mucosa and turbinates, and presence of a viscid secretion with foul odor. AR may be primary or secondary [1].

Klebsiella ozaenae is a causative organism in many cases of primary AR. Hereditary, nutritional deficiency, endocrinal disturbances, and autoimmune causes may also be responsible for primary AR [2].

Secondary AR may be owing to syphilis, rhinoscleroma, lupus, chronic sinusitis, excessive surgical resection of the inferior turbinate, or deviated nasal septum [3].

Incidence of AR varies from 0.3 to 1% of population (primary AR 82% and secondary AR 18% of cases) [3].

Patients with AR mainly present with nasal obstruction, fetor, nasal discharge, anosmia, epistaxis, excessive crustations in the nose, and the nasal cavity appears larger [4].

Treatment of AR included medical and surgical lines; medical such as irrigation, antibiotics, glucose in glycerin drops, iron, multivitamins, and zinc. Surgical treatment is needed to decrease the size of the cavity by submucosal injection of different implant

materials (e.g., medpor, silastic, alloderm, or hyaluronic acid) or increase lubrication by insertion of parotid gland duct into antrum of maxillary sinus [2].

The aim of surgery in AR is to permit considerable volume of air to cross the nasal cavity mainly by narrowing of the nasal airway, which was known as Young's operation with nasal irrigation and ointment application [5].

Objectives

The aim of our study was to evaluate the effectiveness of septoplasty and inferior turbinate reconstruction on quality of life in patients with secondary AR with unilateral deviated septum.

Patients and methods

This study was reviewed and accepted from the ethical point of view by research ethics committee at the

This is an open access article distributed under the terms of the Creative Commons Attribution-NonCommercial-ShareAlike 3.0 License, which allows others to remix, tweak, and build upon the work non-commercially, as long as the author is credited and the new creations are licensed under the identical terms.

Faculty of Medicine, Ain Shams university (number FMASUR 36/2020 – Faculty of Medicine, Ain Shams University research number 36 in 2020). Informed consent was obtained from all individual participants included in the study.

Study design

It was an interventional pilot study on 13 patients.

Interventions

The intervention included septoplasty and usage of autogenous septal cartilage for reconstruction of inferior turbinate.

Main outcomes and measures

The main outcome was assessment of patients with Sino-Nasal Outcome Test-25 (SNOT-25) questionnaire, preoperatively and at 3, 6, and 12 months postoperatively.

The study included 13 patients with unilateral AR and deviated septum to the opposite side. History, endoscopic examination, and computed tomographic scanning of nose and paranasal sinus were done. All our patients showed no response to medical treatment for 6 months before surgery (medical treatment in the form of nasal irrigation, saline douches, liquid paraffin drops, glycerin drops, local and systemic antibiotics, and multivitamins) and had no previous nasal surgery, radiotherapy, or nasal trauma.

Regarding history, the main and presenting complaints were nasal obstruction (in 100% of our patients), foul odor, severe nasal crustation, and postnasal drip.

Regarding examination, markedly deviated septum, in roomy nose side extensive crustation, and atrophy of inferior and middle turbinate were found.

SNOT-25 score (Table 1) was estimated initially preoperatively and then at 3, 6, and 12 months postoperatively.

Surgical technique

Septoplasty was done first, and after correction of the deviated septum, the removed cartilage was used as autogenous implant for augmentation of the lateral nasal wall and inferior turbinate, and then creation of a pocket just inferior to the inferior turbinate in the roomy side by elevation of the mucoperiosteal flap. Thereafter, the pocket was filled with cartilage (three to four pieces of septal cartilage each of 2–3 cm length and 1–2 cm width). Closure of the pocket was done, followed by nasal packing with Vaseline gauze for 48 h.

Table 1 The Sino-Nasal Outcome Test-25 for the assessment of empty nose syndrome [6]; each question is evaluated on a scale of 0-5, with 5 being most severe

Sino-nasal outcome test -25	
1 Need to blow nose	11 Difficulty falling asleep
2 Sneezing	12 Waking up at night
3 Runny nose	13 Lack of good night's sleep
4 Cough	14 Waking up tired
5 Postnasal drip PND	15 Fatigue
6 Thick nasal discharge	16 Reduced productivity
7 Ear fullness	17 Reduced concentration
8 Dizziness	18 Frustration/restlessness/irritability
9 Ear pain	19 Sadness
10 Facial pain	20 Embarrassment
ENT-specific symptoms	
21 Dryness	
22 Difficulty with nasal breathing	
23 Suffocation	
24 Nose is too open	
25 Nasal crusting	

Results

Our study included 13 patients, comprising five (38%) males and eight (62%) females. The mean age was 25 years.

The total SNOT-25 was estimated preoperatively and during 3, 6, and 12 months postoperatively, as shown in Table 2.

The mean score of total SNOT-25 preoperatively was 104.84, which became 25.38 at 12 months postoperatively, as shown in Table 3.

Regarding ENT-specific symptoms, the highest score preoperative was regarding difficulty with nasal breathing and the smallest was regarding suffocation.

All symptoms improved postoperatively, especially at 3 months. At 12 months, the lowest score (significant improvement) was regarding nasal crustations. The mean values of ENT-specific symptoms are illustrated in Table 4 and Fig. 1. Improvement of total SNOT-25 score of each patient is illustrated in Fig. 2.

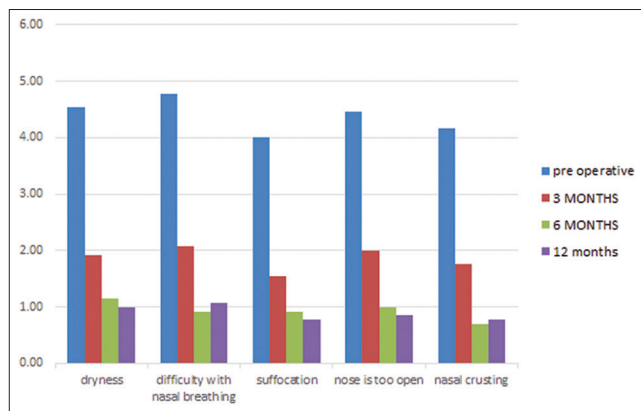
Clinical improvement and healthy nasal mucosa were noticed during follow-up in contrast to the atrophic preoperative nasal mucosa, as shown in Fig. 3.

Discussion

In AR, there is a change in histological structure and loss of mucociliary clearance, so formation of thick nasal discharge and nasal crustation [7].

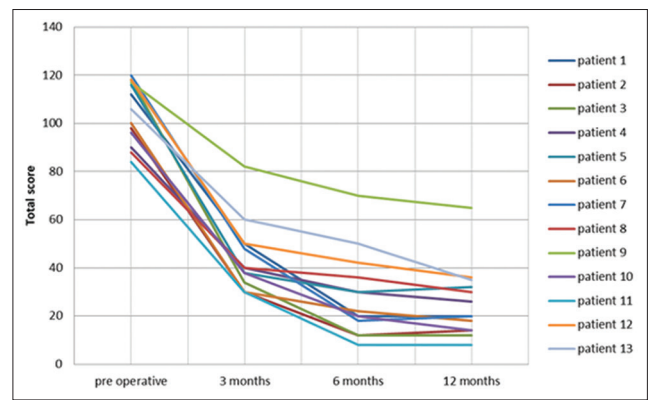
Instead of long-life medical treatment and irrigation in AR, which may not so effective, the cause of secondary

Figure 1



Changes in average of ENT-specific symptoms preoperatively and after 3, 6, and 12 months

Figure 2



Diagrammatic improvement of each patient from preoperative till 12 months postoperatively; the *P* value of two tails was less than 0.05 (significant)

Table 2 Scores of total Sino-Nasal Outcome Test-25 for the study group

Number of patients	Sex	Age	Total SNOT-25 score			12 months follow up
			Preoperative	3 months follow up	6 months follow up	
1	M: male	22	112	50	20	20
2	F: female	16	98	30	12	14
3	F	24	118	34	12	12
4	M	26	90	40	30	26
5	F	28	116	38	30	32
6	F	18	100	30	22	18
7	F	26	120	48	18	20
8	F	35	88	40	36	30
9	M	28	117	82	70	65
10	M	25	96	38	20	14
11	F	19	84	30	8	8
12	M	32	118	50	42	36
13	F	33	106	60	50	35

SNOT-25, Sino-Nasal Outcome Test-25.

Table 3 The mean Sino-Nasal Outcome Test-25 and its *P* value during follow-up

	Preoperative	3 months	6 months	12 months
Mean	104.85	43.85	28.46	25.38
Observations	13	13	13	13
<i>P</i>	Preoperative	3 months		
			<i>P</i> <0.01 (HS)	
	Preoperative	12 months		
			<i>P</i> <0.01 (HS)	
	6 months	12 months		
			<i>P</i> >0.05 (NS)	

HS, highly significant.

AR should be treated [3]. In our study, 13 patients with unilateral AR owing to deviated nasal septum had undergone septoplasty and augmentation of the lateral nasal side and inferior turbinate with the autogenous septal cartilage.

Narrowing of the airway in the roomy side after surgery leads to decrease amount of flow during inspiration, so less drying and less crustations and helps in regeneration of nasal mucosa [5].

A healthy normal nose is responsible for ~50% of airway resistance. In AR, there was a decline in nasal resistance, so imbalance of airway resistance, leading to deep inspiration, shortness of breath, and sensation of suffocation [8].

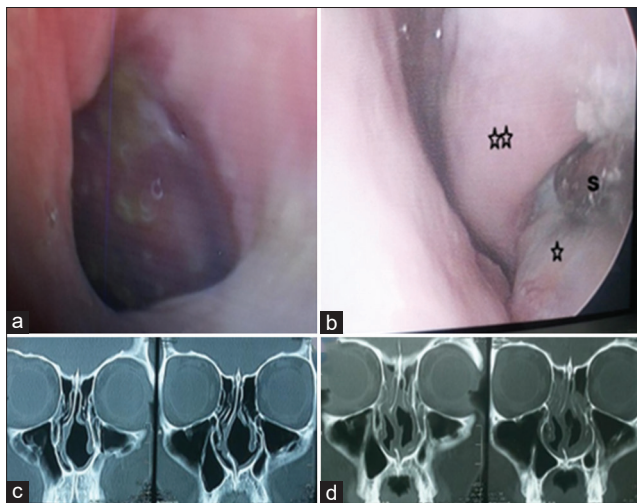
In the present study, there was a highly significant improvement of SNOT-25 after surgery, especially at 3 months postoperatively, were all symptoms improved, including suffocation and difficulty with nasal breathing, leading to improvement of chronic fatigue, irritability, anxiety, and frustration. The early significant postoperative improvement is owing to surgery, and we cannot ignore the postoperative improved nasal hygiene.

Our results go along with the data by Saafan[9] and Jiang *et al.*[10] regarding significant improvement in the SNOT-25 postoperatively. The score was reduced at 3, 6, and 12 months of follow-up in comparison with the primary preoperative score (*P* < 0.01). Improvement of the quality of life of our patients was a supportive indicator about effectiveness of our technique.

Table 4 The mean values of ENT-specific symptoms

	Preoperative	3 months	6 months	12 months
Dryness	4.53	1.92	1.15	1
Difficulty with nasal breathing	4.77	2.07	0.92	1.08
Suffocation	4	1.54	0.92	0.77
Nose is too open	4.46	2	1	0.84
Nasal crusting	4.15	1.77	0.69	0.76

P value between preoperative and 12 months postoperatively was <0.01 highly significant.

Figure 3

(a) The preoperative atrophic nasal mucosa with crustations and (b) postoperative after 12 months of follow-up showing the inferior turbinate (double star) and plugging pocket of reconstructed cartilage just below the inferior turbinate (single star) suction tip (s) in between (c) preoperative computed tomography and (d) postoperative computed tomography

Saafan[9] compared acellular dermal grafts versus silastic as submucosal implants. There were improvements after surgery, and no significance between the two groups. However, Jiang *et al.*[10] used medpor implant for augmentation of inferior turbinate, and there was significant improvement in symptoms of AR.

Several materials are used for augmentation of the inferior turbinate and treatment of AR, such as silastic, medpor, and hyaluronic acid, but they carry a risk of extrusions or rapid resorption [11]. In our study, no recorded complications of extrusions were found along 12 months of follow-up.

In our opinion, we had limitations or weak points in our study, such as limited number of patients and lack of rhinomanometry.

Conclusion

AR is a condition with significant effect on quality of life. Surgical correction of secondary AR, owing to deviated nasal septum, by septoplasty and inferior turbinate reconstruction with autogenous cartilage had good effect on SNOT-25 and quality of life, with no complications.

Financial support and sponsorship

Nil.

Conflicts of interest

There are no conflicts of interest.

References

- 1 Killera S, Borlingegowda V, Vijayashree M. Efficacy of 25% glucose in glycerin and honey in the management of primary atrophic rhinitis: a comparative prospective study. *Res Otolaryngol* 2017; 6:23–26.
- 2 Sreedharan SS, Prasad V, Shenoy VS, Kamath PMA. Clinical study on atrophic rhinitis, its management and surgical outcome. *Gen Med* 2015; 3:1000155.
- 3 Dutt SN, Kameswaran M. The aetiology and management of atrophic rhinitis. *J Laryngol Otol* 2005; 119:843–852.
- 4 Chhabra N, Houser SM. The diagnosis and management of empty nose syndrome. *Otolaryngol Clin North Am* 2009; 42:311–313.
- 5 Young A. Closure of the nostrils in atrophic rhinitis. *J Laryngol Otol* 1967; 81:515–524.
- 6 Houser SM. Surgical treatment for empty nose syndrome. *Arch Otolaryngol Head Neck Surg* 2007; 133:858–863.
- 7 Bist SS, Bisht M, Purohit JP, Saxena R. Study of histopathological changes in primary atrophic rhinitis. *ISRN Otolaryngol* 2011; 2011:269479.
- 8 Wrobel BB, Bien AG, Holbrook EH, Meyer GE, Bratey NA, Meza J, Leopold DA. Decreased nasal mucosal sensitivity in older subjects. *Am J Rhinol* 2006; 20:364–368.
- 9 Saafan ME. Acellular dermal (allograft) grafts versus silastic sheets implants for management of empty nose syndrome. *Eur Arch Otorhinolaryngol* 2013; 270:527–533.
- 10 Jiang C, Wong F, Chen K, Shi R. Assessment of surgical results in patients with empty nose syndrome using the 25-item Sino-Nasal Outcome Test Evaluation. *JAMA Otolaryngol Head Neck Surg* 2014; 140:453–458.
- 11 Leong SC. The clinical efficacy of surgical interventions for empty nose syndrome: a systematic review. *Laryngoscope* 2015; 125:1557–1562.