



## Sublingual Immunotherapy for Allergic Fungal Sinusitis

**Hesham A. Mansour**

ENT department, Cairo University

Email: heshamansour@yahoo.com

**Objective:** *Surgery for allergic fungal sinusitis in the absence of continued medical management is associated with an unacceptably high rate of recurrence. There is no agreement on the proper postoperative medical treatment*

**Method:** *Eighteen patients with allergic fungal sinusitis were treated by surgical treatment and divided into 2 groups. Nine patients received postoperative immunotherapy and the remaining 9 patients did not receive immunotherapy. Both groups received otherwise the same postoperative care and were compared regarding the symptom score, mucosal staging, and number of oral corticosteroid courses, outpatient procedures and revision surgeries.*

**Results:** *There was statistically significant difference between the symptom score of nasal obstruction in patients who received immunotherapy ( $0.67 \pm 0.5$ ) compared to patients who did not receive immunotherapy ( $1.44 \pm 0.53$ )  $P = 0.05$ . The endoscopic staging for mucosa was less in patients who received immunotherapy ( $0.78 \pm 0.67$ ) versus ( $1.78 \pm 0.67$ ) in the other group  $P = 0.05$ . The number of oral corticosteroid courses or outpatient procedures was considerably less in patients who received immunotherapy ( $1 \pm 0.71$ ) versus ( $3.2 \pm 1.2$ ) in the other group  $P = 0.005$ . Revision surgery was performed in 1 patient (11%) in the group who received immunotherapy and in 3 patients (33%) in the other group*

**Conclusion:** *Sublingual immunotherapy is safe and effective in the postoperative treatment of allergic fungal sinusitis.*

**Keywords:** *Allergic fungal sinusitis, sublingual immunotherapy.*

### INTRODUCTION

Fungal sinusitis is classified into four categories: acute invasive fungal sinusitis, chronic invasive fungal sinusitis, mycetoma (fungal ball) and allergic fungal sinusitis.(AFS)<sup>(1)</sup>

According to Bent and Kuhn, the major criteria for diagnosis of AFS are: type I hypersensitivity, nasal polyposis, characteristic CT findings, the presence of eosinophilic mucin without invasion and a positive fungal stain of sinus contents removed at the time of surgery. The minor criteria that support diagnosis include: history of asthma, unilateral predominance of the disease, radiographic evidence of bone erosion, fungal cultures,

presence of Charcot-Leyden crystals in surgical specimens and eosinophilia.<sup>(2)</sup>

Examination of the allergic fungal mucin itself and not the surrounding mucosa is the most reliable indicator of the disease. Grossly the mucin is thick, highly viscous, variably coloured and described as being similar to peanut butter or axle grease. Microscopically, the mucin shows sheets of eosinophils, frequently with the presence of eosinophilic breakdown products or Charcot-Leyden crystals.<sup>(3)</sup>

Aspergillus species are believed to be the predominant cause of allergic fungal sinusitis.<sup>(4)</sup>

It is accepted that complete removal of allergic mucin and maintenance of adequate paranasal sinus drainage is the initial step of therapy. Unfortunately, surgery in the absence of continued medical management is associated with an unacceptably high rate of recurrence.<sup>(5)</sup>

There have been anecdotal reports of the use of post-operative Itraconazole. Long-term, repeated courses of oral corticosteroids reduce symptomatic recurrence. However, such treatment must be avoided in patients with diabetes, blood dyscrasias, immunodeficiency, glaucoma, osteoporosis and hepatitis. Topical steroids also help reduce symptomatic recurrence.<sup>(4)</sup>

Immunotherapy was introduced as a treatment in the long-term control of AFS. It is the only therapeutic option that modifies the basic allergic mechanism by inducing desensitization and an anergy state for the allergen.<sup>(6)</sup>

The rationale for immunotherapy is that AFS is at least partially a result of allergen-specific IgE-mediated inflammation. Although the relative importance of type 1 hypersensitivity in AFS continues to be debated, by definition AFS patients have fungal allergy.<sup>(7)</sup>

Immunotherapy increases allergen tolerance with reorientation of allergen-specific CD4+ T-cell responses from a T helper 2 (Th2) to Th1 and regulatory T-cell profiles. Allergen exposure modifies serum levels of allergen-specific IgE and IgG, although there is considerable debate as to whether these parameters are related to clinical efficacy.<sup>(8)</sup>

The work of Mabry and colleagues suggested that injection immunotherapy to fungal allergens may be effective in the treatment of symptoms of allergic fungal sinusitis and decreases the rate of allergic fungal sinusitis exacerbations postoperatively with less revision surgeries.<sup>(9,10)</sup> However, injection immunotherapy is associated with rare but real risks of anaphylaxis and death. Injection immunotherapy must be administered in an appropriately supervised physician's office on a repeated basis, from once a week to once a month over several years.

Sublingual immunotherapy has a good safety profile that appears to be better than subcutaneous immunotherapy, and has been taken at home in Europe for 20 years.<sup>(11)</sup> In contrast to subcutaneous injection immunotherapy, sublingual immunotherapy appears to elicit mucosal IgA responses, which may contribute significantly to tolerance induction.<sup>(9)</sup>

In this study the effect of sublingual immunotherapy in treatment of allergic fungal sinusitis following surgery was assessed.

## PATIENTS AND METHODS

Eighteen patients who met the criteria of diagnosis of allergic fungal sinusitis were included in this study. These patients presented in Fakeeh Hospital and United Doctors Hospital, Jeddah, KSA, between January 2007 and December 2009.

The criteria for diagnosis were nasal polyps, allergic mucin, CT scan findings in the form of increased attenuation of the sinus contents (figure 1), positive skin prick test for fungal allergen and positive fungal stain by silver stain. The skin prick test was positive for *Aspergillus* species in all patients with or without other allergens. The skin prick test was considered positive when the wheal size for *Aspergillus* mix was >3mm, the negative control was < 3mm and the positive control was >3mm. Fourteen out of the 18 patients had positive fungal culture as well. All the patients were subjected to endoscopic sinus surgery with excision of the polyps and fungal mucin from the affected sinuses. All the patients were treated by postoperative local corticosteroids in the form of Mometazone Furoate 2 puffs once daily all through the postoperative follow up period. Nine of the patients started sublingual specific immunotherapy for *Aspergillus* species (Stallergens, Antony, Paris, France) one month postoperatively (Group 1). The other 9 patients did not receive immunotherapy for different reasons (Group 2). The first group consisted of 6 males and 3 females with the age ranging from 15 to 33 years old while the second group consisted of 5 males and 4 females with the age ranging from 14 to 31 years old. Both groups were similar demographically with regard to patient age, sex, and length of follow-up. The duration of immunotherapy was 2 years starting one month after surgery. The dose starts by 1 drop of the 10 IR/ml concentration sublingual in day one. The dose gradually increases to 2, 4, 6 and 8 drops in the following days. Once this dose is reached, the other vial with 100 IR/ml concentration is started and again the dose increases from 1 drop to 2, 4, 6 and 8 drops in the following days. Once this dose is reached, the immunotherapy is taken every other day till the end of the course. The drops should be taken in the morning and kept under the tongue for 2 minutes then swallowed.

Follow up of patients was scheduled weekly for one month postoperatively for suction of crusts and debris then every month for two years.

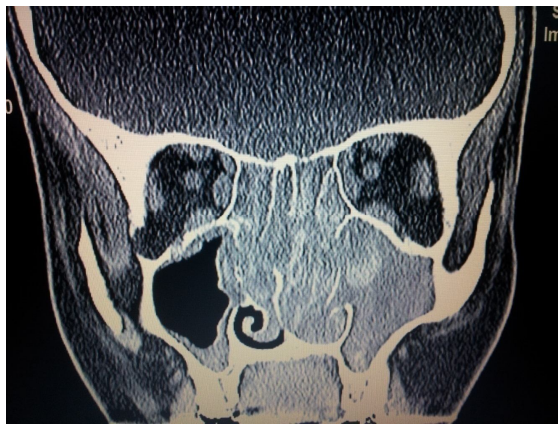When the patient had severe symptoms with recurrent polyps and fungal debris, short course of oral corticosteroid (prednisolone) 30 mg/day for 5 days was used. When there is contraindication to systemic corticosteroids, outpatient endoscopic procedures for excision of polyps and suction of fungal mucin were performed. Revision surgery was indicated if these measures did not improve the condition or the outpatient procedure was not tolerated. Both groups were compared

## Sublingual Immunotherapy for Allergic Fungal Sinusitis

regarding nasal obstruction symptom, endoscopic staging of nasal and sinus mucosa according to Kupferberg,<sup>(12)</sup> number of systemic corticosteroid therapy courses or outpatient procedures and number of revision surgery after 2 years of follow up.

Symptom score was graded from 0 to 3 with 3 being worst. In Kupferberg endoscopic staging system, stage 0 means no evidence of disease, stage 1 oedematous mucosa/allergic mucin, stage 2 polypoid mucosa/allergic mucin and stage 3 polyps and fungal debris.<sup>(12)</sup> All the patients had stage 3 nasal and sinus mucosa and symptom score of 3 before treatment.

Statistical analysis was performed using t-student test considering  $\alpha = 0.05$ . The continuous variables were expressed as mean  $\pm$  standard deviation.



**Fig 1. CT scan of a patient with allergic fungal sinusitis showing the characteristic increased attenuation of sinus contents.**

## RESULTS

Apart from localized mouth itching in 2 patients no complications of sublingual immunotherapy were recorded in this study. This itching was only transient in the beginning of immunotherapy and was treated by antihistamine tablets.

After 2 years of follow up, the symptom score of nasal obstruction in group1 was  $0.67 \pm 0.5$  and in group 2 was  $1.44 \pm 0.53$   $P < 0.05$ . (Fig. 2).

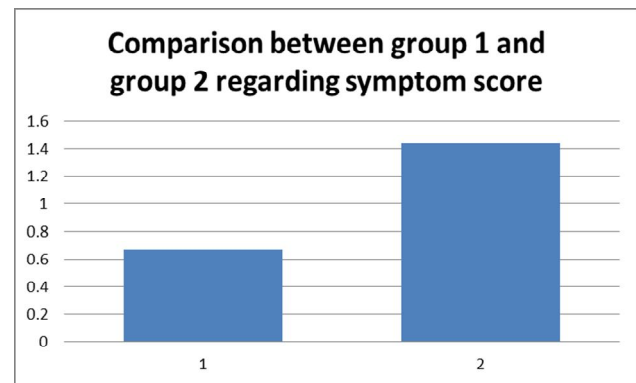
After 2 years of follow up the endoscopic staging for mucosa in group 1 was  $0.78 \pm 0.67$  and in group 2 was  $1.78 \pm 0.67$   $P < 0.05$ . (Fig. 3).

The number of oral corticosteroid courses or outpatient procedures after 2 years of follow up in group 1 was  $1 \pm 0.71$  and in group 2 was  $3.2 \pm 1.2$   $P < 0.005$ . (Fig. 4) Table 1.

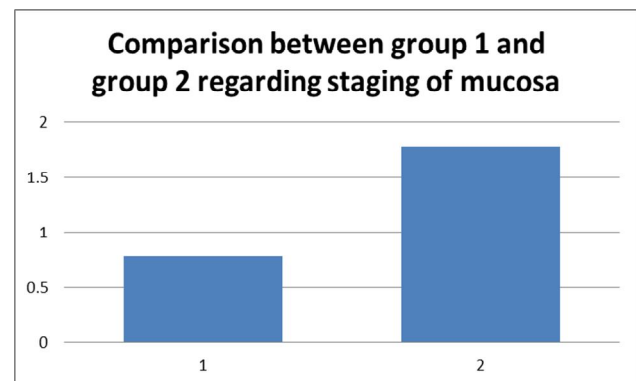
Revision surgery was performed in 1 patient (11%) in group 1 and in 3 patients (33%) in group 2.

**Table 1. The age, gender, symptom score, staging of mucosa, and the number of oral corticosteroid courses or outpatient procedures after 2 years of follow up. OCC (oral corticosteroid course), OPP (outpatient procedures).**

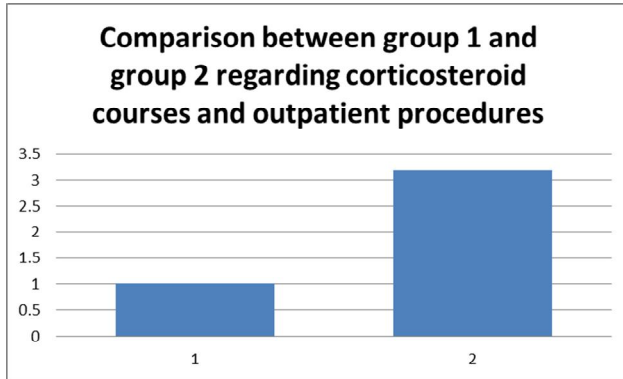
|                      | Group 1         | Group 2         |
|----------------------|-----------------|-----------------|
| Age                  | 15-33           | 14-31           |
| Male/female          | 6/3             | 5/4             |
| Symptom score        | $0.67 \pm 0.5$  | $1.44 \pm 0.53$ |
| Staging of mucosa    | $0.78 \pm 0.67$ | $1.78 \pm 0.67$ |
| Number of OCC or OPP | $1 \pm 0.71$    | $3.2 \pm 1.2$   |



**Fig 2. Symptom score in group 1 with immunotherapy and 2 without immunotherapy after 2 years of follow up.**



**Fig 3. Staging of nasal mucosa in both group 1 with immunotherapy and 2 without immunotherapy after 2 years of follow up.**



**Fig 4. Number of oral corticosteroid courses and outpatient procedures in both groups after 2 years of follow up.**

## DISCUSSION

The reasons for the high rate of recurrence in patients with AFS are not clearly understood. Inadequate surgical removal of fungal disease, re-exposure to fungi, persistent microscopic fungal colonization or factors leading to mucosal swelling and inflammation are all potential causes for recurrent AFS.<sup>(5)</sup>

Treatment with systemic steroids was used in different studies to maintain control of polypoid inflammation. It was observed that the time to revision surgery was prolonged in the group receiving steroids. However, because of the potential side effects of systemic corticosteroids, alternative forms of therapy are needed.<sup>(13)</sup>

Systemic steroids are best confined to the perioperative period and for use in short bursts to suppress recurrent polyps and acute exacerbations of disease. The anti-inflammatory effect of specific allergen immunotherapy has the potential to decrease reliance on systemic steroids in the treatment of AFS and may reduce the need for revision surgery.<sup>(7)</sup>

Mabry et al in 1997 reported the use of subcutaneous immunotherapy directed against specific fungal antigens after skin testing and preceded by definitive surgery in 9 patients. There was no control group but no side effects were reported and less allergic mucin and crusts were noted following treatment.<sup>(9)</sup>

Mabry et al in 1998 reported 23 patients with less recurrence of AFS following subcutaneous immunotherapy.<sup>(10)</sup>

In a study by Folker et al (1998) 11 patients with AFS who received subcutaneous immunotherapy were compared with a control group of 11 patients. The immunotherapy

group had a statistically significant decline in disease activity compared with control subjects as measured by AFS endoscopic mucosal staging. Mean scores of chronic sinusitis survey were significantly higher in the immunotherapy group than the control group. A dramatically reduced corticosteroid requirement was noted in the immunotherapy group.<sup>(14)</sup>

In a study by Bassichis et al (2001), 8 (33.3%) of the 24 patients without immunotherapy required revision surgery for recurrence of polyps or allergic mucin and only 4 (11.1%) of the 36 patients receiving immunotherapy required repeat surgery. The total number of visits requiring interventions averaged 4.79 visits per patient who did not receive immunotherapy versus 3.17 visits per patient for those who were receiving immunotherapy.<sup>(5)</sup>

In the current study there was statistically significant difference between the symptom score of nasal obstruction in patients who received immunotherapy compared to patients who did not receive immunotherapy. The endoscopic staging for mucosa was markedly less in patients who received immunotherapy. The number of oral corticosteroid courses or outpatient procedures was considerably less in patients who received immunotherapy. Revision surgery was performed in 1 patient in the group who received immunotherapy and in 3 patients in the other group. The sublingual immunotherapy was found to be safe, convenient to patients and was taken at home with no need to be received in a health facility.

## CONCLUSION

Sublingual immunotherapy is safe and effective in the postoperative treatment of allergic fungal sinusitis.

## REFERENCES

1. Malini PN, Kauffman CA. Invasive and allergic fungal sinusitis. *Curr Infect Dis Rep.* 2002;3:225-32.
2. Bent JP 3rd, Kuhn FA. Diagnosis of allergic fungal sinusitis. *Otolaryngol Head Neck Surg.* 1994;111:580-8.
3. Maple BF. Allergic fungal rhinosinusitis: current theories and management strategies. *Laryngoscope.* 2001;111:1006-19.
4. Daudia A, Jones NS. Advances in management of paranasal sinus aspergillosis. *J Laryngol Otol.* 2008;122:331-35.
5. Bassichis BA, Marple BF, Mabry RL, Newcomer MT, Schwade ND. Use of immunotherapy in previously treated patients with allergic fungal sinusitis. *Otolaryngol Head Neck Surg.* 2001;125:487-90.
6. Laury AM, DelGaudio JM. Aspergillus infection in the head and neck. *Curr Infect Dis Rep.* 2010;12:217-24.

## **Sublingual Immunotherapy for Allergic Fungal Sinusitis**

7. Ryan MW. Allergic fungal rhinosinusitis. *Otolaryngol Clin N Am.* 2011;44:697-710.
8. Novak N, Bieber T, Allam J----P. Immunological mechanisms of sublingual allergen-specific immunotherapy. *Allergy.* 2011;66:733-9.
9. Mabry RL, Manning SC, Mabry CS. Immunotherapy in the treatment of allergic fungal sinusitis. *Otolaryngol Head Neck Surg.* 1997;116:31-5.
10. Mabry RL, Marple BF, Folker RJ, Mabry CS. Immunotherapy for allergic fungal sinusitis: three years' experience. *Otolaryngol Head Neck Surg.* 1998;119:648-51.
11. Lin SY, Leatherman B. Sublingual immunotherapy. *Otolaryngol Clin N Am.* 2011;44:753-64.
12. Kupferberg SB, Bent JP, Kuhn FA. Prognosis for allergic fungal sinusitis. *Otolaryngol Head Neck Surg.* 1997;117:35-41.
13. Schubert MS, Goetz DW. Evaluation and treatment of allergic fungal sinusitis: treatment and follow up. *J Allergy Clin Immunol.* 1998;102:395-402.
14. Folker RJ, Marple BF, Mabry RL, Mabry CS. Treatment of allergic fungal sinusitis:a comparison trial of postoperative immunotherapy with specific fungal antigens. *Laryngoscope.* 1998;108:1623-7.