

Management and outcome of treatment modalities of cerebrospinal fluid rhinorrhea

Mustafa Tajelsir, Nazik Elfadil, Mohamed Elawad

Department of Otorhinolaryngology, Eldoha ENT Specialized Hospital, Khartoum University, Khartoum, Sudan

Correspondence to Mustafa Tajelsir, MBBS, Department of Otorhinolaryngology, Eldoha ENT Specialized Hospital, Khartoum University, Khartoum 79371, Sudan
Tel: +249 912 337 131; Fax: +82 337 462 287; e-mail: mustafa.tajelsir@gmail.com

Received 29 November 2019

Revised 17 December 2019

Accepted 21 January 2020

Published 21 January 2021

Pan Arab Journal of Rhinology
2020, 10:63–68

Background

Management of cerebrospinal fluid (CSF) rhinorrhea includes either conservative or surgical treatment. The aim of this study is to evaluate the results of management of CSF rhinorrhea in three tertiary care centers in Khartoum state.

Patients and methods

This was a prospective analysis of 40 consecutive patients who underwent management of CSF rhinorrhea between April 2016 and April 2019. Conservative management consists of a 7–30-day trial of bed rest, head elevation 15–30°, stool softeners, avoidance of straining, and diuretics. All patients were offered conservative treatment except those with meningitis and iatrogenic leak, and patients with tension pneumocephalus were managed surgically from the start.

Results

A total of 40 patients were included. Spontaneous CSF leak cases were 19 (47.5%), with female to male ratio of 3.75: 1. Posttraumatic CSF leak cases were 16 (40%), with male to female ratio of 2.2: 1. Five (12.5%) patients were iatrogenic, with female to male ratio of 4.0: 1; they were managed surgically only as well as one patient with history of meningitis. Conservative treatment was successful in 11 (32%) of 34 patients. Surgical treatment was performed for 29 patients, mainly by endoscopic approach in 26 (89.7%) patients, with success rate of 96.1%; osteoplastic flap for two (6.9%) patients, with a success rate of 100%; and intracranial (frontal craniotomy) for one (3.4%) patient, with a success rate of 100%. The success rates following first surgery for patients with posttraumatic, postprocedural, and spontaneous CSF leaks were 100, 100, and 93.3%, respectively. Four patients required second surgery, which was successful in three and failed in one with persistent leak.

Conclusion

Patients with CSF rhinorrhea were offered conservative treatment initially, except for iatrogenic leaks and past history of meningitis. Failure of conservative management warrants surgical treatment, which has high success rates. Head trauma, technical failures, lack of CSF divergence, and poor management of spontaneous leaks were responsible for recurrence of leak. Decision for surgical repair is appropriate in a teamwork between otorhinolaryngologists and neurosurgeons with attention to surgical approach, operative details, and postoperative care.

Keywords:

Management, Treatment, outcome, CSF rhinorrhea

Pan Arab J Rhinol 10:63–68
© 2021 2090-7640

Introduction

Cerebrospinal fluid (CSF) leaks result from an abnormal communication between the subarachnoid space and the extracranial space. There is usually a breach in the bone and the dural and arachnoid meningeal layers [1].

CSF rhinorrhea is classified into four categories: acute traumatic, delayed posttraumatic, operative, and spontaneous [2]. Traumatic CSF rhinorrhea is further classified into accidental and iatrogenic types and nontraumatic CSF rhinorrhea into high-pressure leaks and normal-pressure leaks [3].

Two approaches are intracranial and extracranial repair. Intracranial repair requires a bifrontal craniotomy with exposure of the bony or meningeal defect superiorly [4].

An extracranial approach is performed via external ethmoidectomy.

With the popularity of functional endoscopic sinus surgery, the endoscopic approach also has been advocated for the repair of CSF rhinorrhea [5]. Unlike the intracranial approach, the endoscopic approach provides better illumination and higher success rates with minimal morbidity [3–6]. This study is designed to shed the light on the treatment modalities used for CSF leaks in Khartoum state to determine management and outcome of treatment

This is an open access journal, and articles are distributed under the terms of the Creative Commons Attribution-NonCommercial-ShareAlike 4.0 License, which allows others to remix, tweak, and build upon the work non-commercially, as long as appropriate credit is given and the new creations are licensed under the identical terms.

modalities so as to give insight on the proper treatment.

Patients and methods

A prospective analysis was conducted on 40 consecutive patients who received different management for CSF rhinorrhea between 2016 and 2019. Details pertaining to the etiology of CSF leak, clinical presentation, surgical procedure, and hospital stay were included. Confirmation of CSF rhinorrhea was done by estimating the glucose levels in the watery discharge and beta-2 transferrin test in selected cases. Further evaluation included high-resolution computed tomography (CT) scan of the skull base and paranasal sinuses for all the cases and MRI for selected cases.

Conservative management consists of a 7–30-day trial of bed rest with the head of the bed elevated ~15–30°, stool softeners, and diuretics. Coughing, sneezing, nose blowing, and heavy lifting to be avoided was advised.

Endoscopic repair was performed by an otorhinolaryngologist, whereas osteoplastic flap and intracranial approach were done in liaison with a neurosurgeon.

Endoscopic endonasal approach was done under general anesthesia. Nasal mucosa was decongested with infiltration of 1: 200 000 adrenaline solution. After identification of leak site/s, repair was performed using fat (harvested from thigh), fascia lata, and gelfoam. A piece of nasal septal cartilage was used to cover bony defects of size more than 1 cm. During the postoperative period, measures were taken to prevent elevation of intracranial pressure.

The first follow-up visits were scheduled between 2, 4, and 12 weeks after discharge, and subsequent visits

were planned per the convenience of the patient. Telephonic interviews were carried out for patients who were not compliant with follow-up.

Results

A total of 40 patients underwent management at the hospital during the study period: traumatic ($n=16$), spontaneous ($n=19$), and postprocedural or iatrogenic ($n=5$). Male sex predilection was noted in the posttraumatic leaks (Table 1). Spontaneous leaks were more common in female patients (age group 40–59 years). The incidence of traumatic CSF leaks was highest in young adult males (20–39 years). All patients presented with a watery discharge from the nostril. Clinical presentation consistent with meningitis was noted in seven posttraumatic leaks and one postprocedural CSF leak. Postprocedural leaks were observed in four patients following endoscopic sinus surgery and one patient following craniotomy with resection of clinoidal meningioma.

The most common site of leak in patients with postprocedural CSF leak was the ethmoid roof (three out of five patients), whereas cribriform was the most common site of leak in eleven patients with spontaneous CSF leak ($n=19$). In posttraumatic CSF leaks, ethmoid sinus was frequently involved [Table 1].

Pneumocephalus was present in eight (20%) patients. Successful treatment showed improvement in all cases.

Conservative management was offered to 34 patients, with success in 11 (32.4%) patients. One to two weeks is the optimum duration of conservative treatment with the highest outcome (Table 2). Surgical treatment was performed for 29 patients (which include all the iatrogenic and most of the spontaneous cases), with 96.5% success rate (Fig. 5).

Table 1 Summary of the patients in the study ($n=40$)

	Type of skull base CSF leak		Spontaneous ($n=19$)
	Traumatic ($n=16$)	Iatrogenic ($n=5$)	
Outcome of surgery			
Successful	9	5	14
Unsuccessful	0	0	1
Sites of CSF leaks			
Frontal sinus	4	0	1
Sphenoid sinus	5	2	6
Ethmoid roof/cribriform plate	11	3	11
Posterior ethmoid	1	0	1
Multiple sites	6	0	0
Sex			
Male	11	2	4
Female	5	3	15

CSF, cerebrospinal fluid.

Table 2 Summary of the patients in the study (n=40)

	Outcome of conservative management	
	Successful	Not successful
Type of leak		
Traumatic	7	9
Iatrogenic	0	3
Spontaneous	4	11
Duration of conservative management (weeks)		
<1	4	0
1-2	5	6
2-3	0	2
3-4	1	1
>4	1	14
Site of leak		
CSF rhinorrhea	10	23
Both otorrhea and rhinorrhea	1	0

CSF, cerebrospinal fluid.

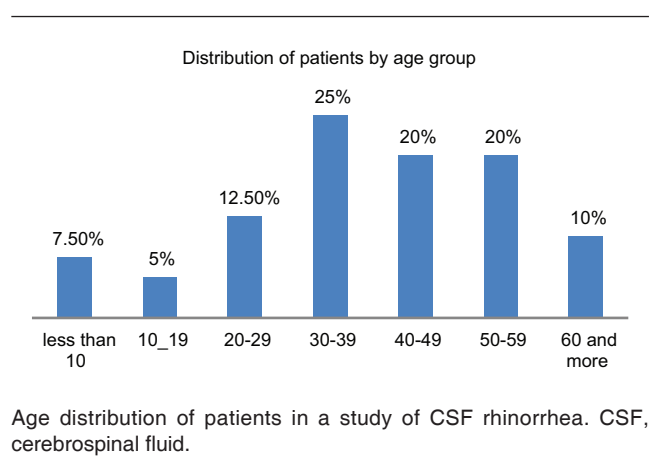
Endoscopic procedure was done for 26 cases, with 96.1% success rate. An osteoplastic flap through a bicoronal incision was performed successfully in two of the 16 posttraumatic leaks for management of associated frontal sinus defect. An intracranial approach was done successfully for one patient.

Regarding the recurrence of leak after successful treatment, two patients had recurrence of leak following successful medical treatment for spontaneous CSF leak, where one had recurrence after 2 months following persistent straining for 2 weeks, and the other one had recurrence after 4 months following head trauma, but both responded well to medical therapy. Another patient in the same group (spontaneous CSF leak), developed recurrence shortly after endoscopic repair, which was inadequately managed idiopathic intracranial hypertension, caused a CSF leak from a site different from that of the previous surgery. Another patient in the same group (spontaneous CSF leak) developed recurrence 9 months following successful endoscopic repair, which was residual cerebellopontine angle meningioma, caused a CSF leak from a site different from that of the previous surgery. Two patients in the posttraumatic group had successful endoscopic repair, where one of them had recurrence of leak from the same site 1 year following football injury, whereas the other one had recurrence of leak from the same site at 4 months following head trauma; both patients were successfully repaired with a second endoscopic approach.

Graft materials being used and supportive synthetic material are shown in Figs. 1–4.

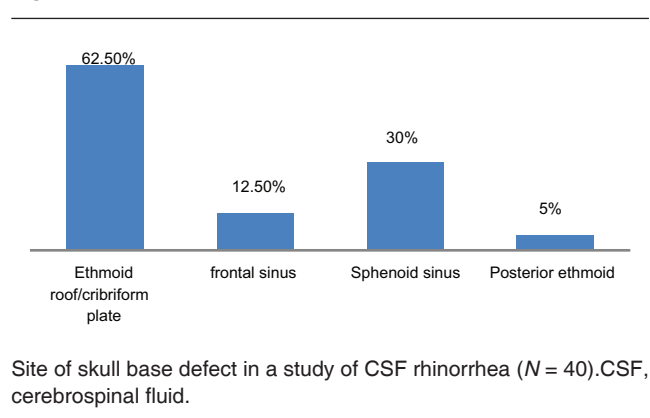
No morbidity or mortality related to the surgical procedure was noted.

Figure 1



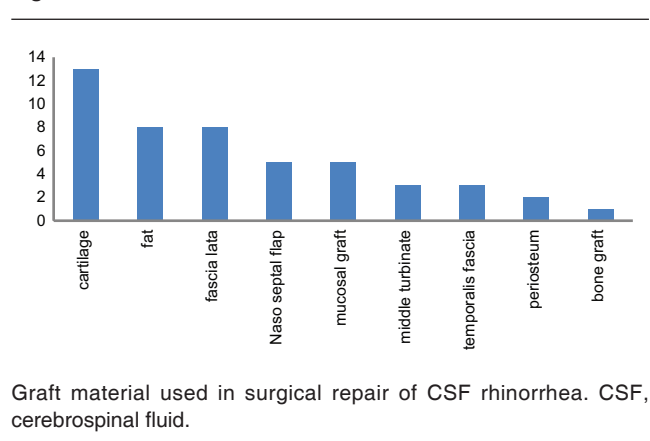
Age distribution of patients in a study of CSF rhinorrhea. CSF, cerebrospinal fluid.

Figure 2



Site of skull base defect in a study of CSF rhinorrhea (N = 40). CSF, cerebrospinal fluid.

Figure 3

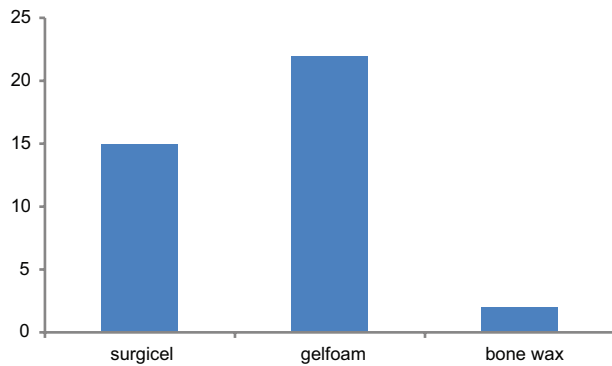


Graft material used in surgical repair of CSF rhinorrhea. CSF, cerebrospinal fluid.

Discussion

In this study, the incidence of spontaneous CSF leaks was higher than posttraumatic and postprocedural leaks, which was similar to the results of meta-analysis, where the prevalence of spontaneous leaks was high [7,8]. Posttraumatic leaks were more common in males aged 30–39 years, whereas spontaneous leaks were more common in females aged 40–49 years. Cribriform plate was the commonest sites for spontaneous CSF leaks, whereas posttraumatic patients had CSF leaks from multiple sites, with ethmoid roof/cribriform plate

Figure 4

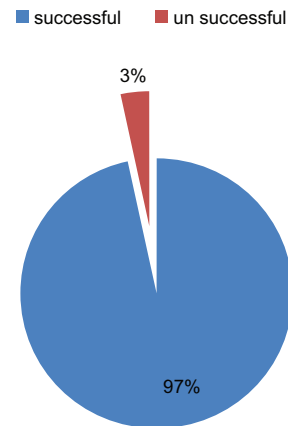


Other supportive synthetic materials used in surgical repair of CSF rhinorrhea. CSF, cerebrospinal fluid.

being common sites in the majority of them [7,9–16]. Hence, it is important to inspect all sites corresponding to skull base fractures for evidence of dural breach or CSF leak in patients presenting with traumatic CSF rhinorrhea. The key to endoscopic transnasal surgical repair of the leak is accurate preoperative location of the site of leak, meticulous preparation of the recipient bed, and accurate placement of the graft material [3,5]. In their meta-analysis, Hegazy and colleagues found no statistically significant difference among different grafting techniques and materials. Several authors have reported successful results with relatively consistent use of lumbar drain, whereas others have reported similar results without lumbar drain placement [17–19]. On the basis of a meta-analysis of 14 studies comprising 289 CSF fistulae repairs, Hegazy and colleagues advocated the use of lumbar drains for 3–5 days with idiopathic leaks, posttraumatic leaks, leaks associated with large defect (>15 mm), recurrent leaks, and leaks associated with a meningocele. None of our patient underwent lumbar drain placement.

In a meta-analysis of 55 studies involving 1778 fistula repairs, Psaltis *et al.* [7] observed a success rate of 90.6% following first endoscopic repair for CSF rhinorrhea, which improved to 96.6% following a second endoscopic procedure. The success rate in the largest series of endoscopic repair of CSF leaks reported by Kirtane *et al.* [9] was 96.63% following first surgery and 98.88% after revision surgery. Castelnuovo and colleagues reviewed the literature for 286 endoscopic CSF leak repairs and found 28 cases of failure at the first attempt. Most authors, however, failed to specify the precise site of failure and did not offer any further details. From their experience of failures, it emerged that meticulous technique with accurate preparation of the margins and graft coverage of at least 5 mm from the margins was important [20]. Factors that might predispose to failure of the treatment are the inability to identify the defect, inadequate preparation of the

Figure 5



Immediate outcome of surgical repair in a study of CSF rhinorrhea (N = 29). CSF, cerebrospinal fluid.

defect area before positioning the graft, spontaneous CSF leak, elevated BMI, location of leak in lateral sphenoid, and a massive skull base defect [20–22].

Spontaneous CSF leaks have the highest recurrence rate following surgical repair (25–87%), compared with less than 10% for most other etiologies [5,17–31]. In a retrospective analysis of 72 patients over a 10-year period, Mirza *et al.* [13] observed that 13 (46%) of 29 patients with spontaneous CSF leaks had evidence of raised intracranial pressure; six (46%) of the 13 patients with raised intracranial pressure had a recurrence of leak. Chaaban *et al.* [32], on the basis of their 5-year prospective study on 46 patients with 56 spontaneous CSF leaks, concluded that successful treatment of elevated intracranial pressure in combination with endoscopic repair can provide high success rates (93% primary and 100% secondary), approaching that of other etiologies. In our study of 19 patients with spontaneous CSF leaks, 15 patients had evidence of raised intracranial pressure and received medical therapy followed by endoscopic procedure. All were successful but one failed; this patient had high-pressure leak with multiple sphenoid sinus defects and underwent successful repair of CSF leak following a third endoscopic procedure along with the copertoneal shunt. To facilitate better visualization of the sphenoid recess during repeat surgical repair on patient with sphenoid defects, anterior and posterior ethmoidectomy were performed followed by widening of the sphenoid ostium. Mucosa of the sinus was removed, and the free graft was layered to check the dimensions and orientation for best fit.

There were four other patients (two posttraumatic and four spontaneous) in our study who developed recurrence of leak following the initial endoscopic

procedure. Unlike other series, which have relied on the use of intraoperative fluorescein dye for localization of site of leak in cases, we relied only on correlation between surgical anatomy and imaging findings. This could have resulted in the one technical failure in our study.

Multiple successful techniques for repair of complex skull base defects, ranging from simple endoscopic local mucosal flaps to complex free tissue transfer with microvascular anastomosis, have been described in the literature, like Hadad–Bassagasteguy flap and transpterygoid temporoparietal fascia flap [33,34]. The average time for recurrence in Zuckerman *et al.* [35] series was 7 months (1–25 months). In our study, recurrence was observed within 4 and 12 months of the first endoscopic repair in two patients with posttraumatic CSF leak. The remaining leak occurred at 9 months after the first procedure in the spontaneous CSF leak repair.

Conclusion

Females predominated in spontaneous CSF rhinorrhea, whereas males predominated in the posttraumatic type. Conservative (nonsurgical) treatment was successful in 32% of patients. Surgical treatment is offered as the only modality in iatrogenic and patients with history of meningitis. Spontaneous leaks failed conservative treatment considerably and most were successfully treated by surgery. Surgical modalities included endoscopic endonasal (89.7%) with a success rate of (96.1%); osteoplastic flap (6.9%), with a success rate of 100%; and intracranial (3.4%), with a success rate of 100%.

Recommendation

Teamwork between neurosurgeons and otorhinolaryngologists with attention to identification of sites of leak, surveillance for raised CSF pressure, preparation of graft bed, securing the graft in place, and postoperative care, is critical to achieve a high success rate for endoscopic repair of CSF leaks and meningoencephalocele. High-pressure leak should be checked before surgery and treated properly in a teamwork.

MR cisternography and navigation-assisted surgery should be considered.

Declaration of patient consent

The authors certify that they have obtained all appropriate patient consent forms. In the form the patient(s) has/have given his/her/their consent for his/her/their images and other clinical information to be

reported in the journal. The patients understand that their names and initials will not be published and due efforts will be made to conceal their identity, but anonymity cannot be guaranteed.

Financial support and sponsorship

Nil.

Conflicts of interest

There are no conflicts of interest.

References

- 1 Park JI, Strelzow VV, Friedman WH. Current management of cerebrospinal fluid rhinorrhea. *Laryngoscope* 1983; 93:1294–1300.
- 2 Wigand ME. Transnasalethmoidectomy under endoscopic control. *Rhinology* 1981; 19:7–15.
- 3 Kerr JT, Chu FW, Bayles SW. Cerebrospinal fluid rhinorrhoea: diagnosis and management. *Otolaryngol Clin North Am* 2005; 38:597–611.
- 4 Tolley NS. A clinical study of spontaneous CSF rhinorrhoea. *Rhinology* 1991; 29:223–230.
- 5 Schlosser RJ, Bolger WE. Nasal cerebrospinal fluid leaks: critical review and surgical consideration. *Laryngoscope* 2004; 114:255–265.
- 6 McCormack B, Cooper PR, Persky M, Rothstein S. Extracranial repair of cerebrospinal fluid fistulas: technique and results in 37 patients. *Neurosurgery* 1990; 27:412–417.
- 7 Psaltis AJ, Schlosser RJ, Banks CA, Yawn J, Soler ZM. A systematic review of the endoscopic repair of cerebrospinal fluid leaks. *Otolaryngol Head Neck Surg* 2012; 147:196–203.
- 8 Hegazy HM, Carrau RL, Snyderman CH, Kassam A, Zweig J. Transnasal endoscopic repair of cerebrospinal fluid rhinorrhea: a meta-analysis. *Laryngoscope* 2000; 110:1166–1172.
- 9 Kirtane MV, Gautham K, Upadhyaya SR. Endoscopic CSF rhinorrhoea closure: our experience in 267 cases. *Otolaryngol Head Neck Surg* 2005;132:208–212.
- 10 Banks CA, Palmer JN, Chiu AG, O Malley BW Jr, Woodworth BA. Endoscopic closure of CSF rhinorrhoea: 193 cases over 21 years. *Otolaryngol Head Neck Surg* 2009;140:826–833.
- 11 Locatelli D, Rampa F, Acchiardi I, Bignami M, De Bernardi F, Castelnovo P. Endoscopic endonasal approaches for repair of cerebrospinal fluid leaks: 9 year experience. *Neurosurgery* 2006;58:246–256.
- 12 Mc Mains KC, Gross CW, Kountakis SE. Endoscopic management of cerebrospinal fluid rhinorrhoea. *Laryngoscope* 2004; 114:1833–1837.
- 13 Mirza S, Thaper A, McClelland L, Jones NS. Sinonasal cerebrospinal fluid leaks: management of 97 patients over 10 years. *Laryngoscope* 2005; 115:1774–1777.
- 14 Ye H, Zuo J, Zhao H, Liu S, An H, Liu Y. Endonasal endoscopic repair of cerebrospinal fluid rhinorrhoea in a series of 69 patients. *Br J Neurosurg* 2010; 24:244–248.
- 15 Virk JS, Elmiyeh B, Saleh HA. Endoscopic management of cerebrospinal fluid rhinorrhoea: the charing cross experience. *J Neurol Surg B Skull Base* 2013; 74:61–67.
- 16 Marshall AH, Jones NS, Robertson IJ. CSF rhinorrhoea: the place of endoscopic sinus surgery. *Br J Neurosurg* 2001; 15:8–12.
- 17 Casiano RR, Jassir D. Endoscopic cerebrospinal fluid rhinorrhea repair: is a lumbar drain necessary? *Otolaryngol Head Neck Surg* 1999; 121:745–750.
- 18 Anand VK, Murali RK, Glasgold MJ. Surgical decisions in the management of cerebrospinal fluid rhinorrhoea. *Rhinology* 1995; 33:212–218.
- 19 Roland PS, Marple BF, Meyerhoff WL, Mickey B. Complications of lumbar spinal fluid drainage. *Otolaryngol Head Neck Surg* 1992; 107:564–569.
- 20 Castelnovo P, Mauri S, Locatelli D, Emanuelli E, Delù G, Giulio GD. Endoscopic repair of cerebrospinal fluid rhinorrhoea: learning from our failures. *Am J Rhinol* 2001; 15:333–342.
- 21 Zweig JL, Carrau RL, Celin SE, Schaitkin BM, Pollice PA, Snyderman CH, *et al.* Endoscopic repair of cerebrospinal fluid leaks to the rhinonasal tract: predictors of success. *Otolaryngol Head Neck Surg* 2000; 123:195–201.

- 22 Basu D, Haughey BH, Hartman JM. Determinants of success in endoscopic cerebrospinal fluid leak repair. *Otolaryngol Head Neck Surg* 2006; 135:769–773.
- 23 Rodney J, Wilensky, Maloney E, Grady MS, Bolger, William E. Elevated intracranial pressures in spontaneous cerebrospinal fluid leaks. *Am J Rhinol* 2003; 17:191–195.
- 24 Lindstrom DR, Toohill RJ, Loehrl TA, Smith TL. Management of cerebrospinal fluid rhinorrhoea: the medical college of Wisconsin experience. *Laryngoscope* 2004; 114:969–974.
- 25 Bolger WE, Osenbach R. Endoscopic transpterygoid approach to the lateral sphenoid recess. *Ear Nose Throat J* 1999; 78:36–46.
- 26 Alexander NS, Chaaban MR, Riley KO, Woodworth BA. Treatment strategies for lateral sphenoid sinus recess cerebrospinal fluid leaks. *Arch Otolaryngol Head Neck Surg* 2012; 138:471–478.
- 27 Hubbard JL, McDonald TJ, Pearson BW, Laws ER Jr Spontaneous cerebrospinal fluid rhinorrhea: evolving concepts in diagnosis and surgical management based on the Mayo Clinic experience from 1970 through 1981. *Neurosurgery* 1985; 16:314–321.
- 28 Har-El G. What is spontaneous cerebrospinal fluid rhinorrhea? Classification of cerebrospinal fluid leaks. *Ann Otol Rhinol Laryngol* 1999; 108:323–326.
- 29 Wang EW, Vandergrift WA, Schlosser RJ. Spontaneous CSF leaks. *Otolaryngol Clin North Am* 2011; 44:845–856.
- 30 Seth R, Rajasekaran K 3rd, Luong A, Benninger MS, Batra PS. Spontaneous CSF leaks: factors predictive of additional interventions. *Laryngoscope* 2010; 120:2141–2146.
- 31 Woodworth BA, Prince A Chiu AG. Spontaneous CSF leaks: a paradigm for definitive repair and management of intracranial hypertension. *Otolaryngol Head Neck Surg* 2008; 138:715–720.
- 32 Chaaban MR, Illing E, Railey KO, Woodworth BA. Spontaneous cerebrospinal fluid leak repair: a five year prospective evaluation. *Laryngoscope* 2014; 124:70–75.
- 33 Tabae A, Anand VK, Brown SM, Lin JW, Schwartz TH. Algorithm for reconstruction after endoscopic pituitary and skull base surgery. *Laryngoscope* 2007; 117:1133–1137.
- 34 Patel MR, Taylor RJ, Hackman TG, Germanwala AV, Sasaki-Adams D, Ewend MG, *et al*. Beyond the nasoseptal flap: outcomes and pearls with secondary flaps in endoscopic endonasal skull base reconstruction. *Laryngoscope* 2014; 124:846–852.
- 35 Zuckerman J, Stankiewicz JA, Chow JM. Long-term outcomes of endoscopic repair of cerebrospinal fluid leaks and meningoencephaloceles. *Am J Rhinol* 2005; 19:582–587.