

Intercarotid distance variations in pituitary adenomas: a cone-beam computed tomographic study

Omar Abd El-Moneam El-Banhawy^a, Ayman El-Sayed Abd El-Aziz^a, Ahmed N. M. Taha^b, Wael M. Safwat^c, Magdi El-Sayed Abd El-Ghafar^d

Departments of ^aOtolaryngology, ^bNeurosurgery and ^cDentomaxillofacial Radiology, Faculty of Dentistry, Mansoura University, Menoufia, ^dDepartment of Otolaryngology, El-Hamoul General Hospital, Kafr El-Sheikh, Egypt

Correspondence to Magdi El-Sayed Abd El-Ghafar, Dakahlia, Mansoura, Ahmed Maher Street, El-Mansoura, Daqahlya, Egypt.
Tel: +20 100 878 7944; Postal Code 7650131
e-mail: magdi_abdelghafar@yahoo.com

Received 28 November 2019

Revised 23 December 2019

Accepted 28 December 2019

Published 21 January 2021

Pan Arab Journal of Rhinology

2020, 10:58–62

Introduction

Transnasal trans-sphenoidal surgery has become the most popular procedure to approach different sellar lesions. Internal carotid artery injury during this approach could be minimized by accurate preoperative assessment of its course and detection of anatomical variations.

Patients and methods

This study was conducted on 24 cases with pituitary adenomas. The intercarotid distance (ICD) was measured by cone-beam computed tomography, and defined as the minimal distance between the inner walls of the carotid sulcus of the horizontal parasellar internal carotid artery. Comparison of measurements in the study group with that of healthy individuals of the control group was done.

Aim

The aim of this study was to detect variations in ICD with pituitary adenomas.

Results

This study showed that ICD was statistically significantly higher in the study than control groups ($P=0.01$). A statistically significant correlation between lesion size and ICD was found ($P=0.04$). A statistically significant difference between the ICD with the type of sellar pathology was found. The widest distance was found with suprasellar lesions (mean = 8.93 ± 2.09 , $P_1=0.009$) and the least in sellar lesions (mean = 16.58 ± 1.94).

Conclusion

Preoperative measurement of ICD is applicable and helpful in operative planning for the trans-sphenoid approach to pituitary lesions. The size of the adenomas directly affects the ICD with larger adenomas showing wider distance.

Keywords:

adenoma, intercarotid distance, internal carotid artery, trans-sphenoid

Pan Arab J Rhinol 10:58–62

© 2021 2090-7640

Introduction

Transnasal endoscopic surgeries became the method of choice for approaching different lesions affecting the skull base, the clivus, and cranio-cervical junction [1]. The method has gained popularity from its advantages of good visualization with angled visualization, minimal tissue handling, and more cosmetic outcomes [2]. Nowadays, endoscopic transnasal trans-sphenoidal surgery is the most popular approach for sellar lesions, with possibility for more extensions to approach more lateral lesions [3].

Prevention of injury to vital structures during endoscopic skull base surgeries is the core for successful and safe intervention. Internal carotid artery (ICA) injury is the most dangerous and even disastrous complication that may be encountered during the trans-sphenoid surgery. Thorough anatomical knowledge of the surgeons is the key for prevention of this complication [4]. A risk of ICA injury is related to its close relation with the sphenoid sinus, with thin bony covering, which may be less than 0.5 mm [5]. Also, the dehiscence lateral

sphenoid wall was reported to be about 22% with higher risk of ICA injury [6].

Arterial injuries during endoscopic endonasal surgery is about 0.1–0.9% in which ICA injury represents about 0–0.26% [7]. Besides its high mortality effect, the injured ICA may be sequenced by vasospasm, pseudoaneurysm formation, thrombosis, caroticoavernous fistula, and embolic brain infarction [8].

The intercarotid distance (ICD) showed variable measurements in different literatures. It is important to be aware of its anatomical variations during trans-sphenoidal surgery to avoid potential catastrophic injury to ICA [9]. This study aimed to analyze ICD measurements in cases with pituitary adenomas in comparison with measurements in controls.

This is an open access journal, and articles are distributed under the terms of the Creative Commons Attribution-NonCommercial-ShareAlike 4.0 License, which allows others to remix, tweak, and build upon the work non-commercially, as long as appropriate credit is given and the new creations are licensed under the identical terms.

Patients and methods

This study was conducted on 48 individuals: 24 cases with pituitary adenomas represented the study group and 24 healthy individuals represented the control group. Patients were recruited from Menoufia University hospitals.

Inclusion criteria

Patients with pituitary adenomas are included in this study: eight patients are with pituitary adenomas confined to sella, eight with suprasellar extension, and eight with parasellar extension.

Exclusion criteria

Patients with conditions that disturb the normal configuration of sphenoid sinuses and the bony sella were excluded. As those with craniofacial anomalies, sphenoid sinus lesions, history of sino-nasal or trans-sphenoid surgeries, and history of skull base trauma affect its bony structures. In addition, patients who showed radiological artifacts/distortion in the area of study were excluded.

Cone-beam computed tomographic examination protocol

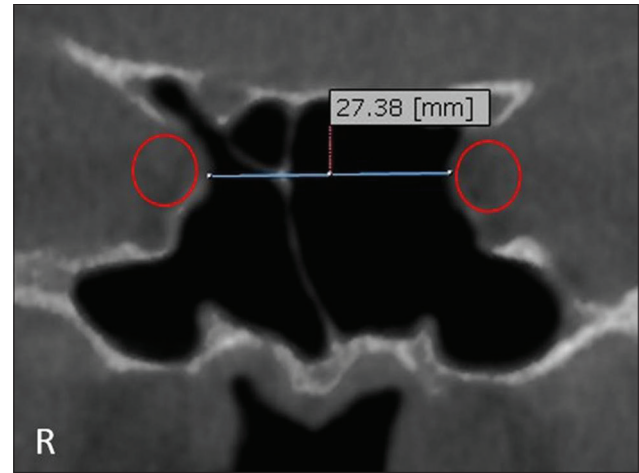
Both the study and control groups were subjected to cone-beam computed tomography scanning using iCAT next-generation cone-beam computed tomography machine (Imaging Science International, ISI, Hatfield, PA, USA). Selected imaging protocol was 16 cm diameter \times 11 cm height field of view and resolution of 0.25 mm voxel size. Exposure parameters were 120 KVP, 5 mA, with an exposure time of 14.7 s. Raw images were imported into specific image analysis software (on-demand 3D App, Cybermed, Seoul, Korea). Digital images were analyzed properly in both orthogonal and reconstructed planes. Images are taken in sitting position without contrast injection.

The ICD is measured as the smallest distance between the inner walls of the carotid sulci of the horizontal parasellar ICA in millimeters (Fig. 1). Measurements were evaluated in coronal views and compared in both study and control groups. In the study group, the minimum measured ICD is 13.87 mm and the maximum measured ICD is 30.40 mm (Fig. 2).

Statistical analysis and data interpretation

Data were fed to the computer and analyzed using SPSS software package version 22.0 (IBM, USA). Qualitative data were described using

Figure 1



Intercarotid distance measurement of parasellar internal carotid artery, cone-beam computed tomography coronal image.

number and percentage. Quantitative data were described using median (minimum and maximum) for nonparametric data and mean, SD for parametric data after testing normality using the Shapiro–Wilk test. Significance of the obtained results was judged at the (0.05) level.

Data analysis

Qualitative data

Monte Carlo test as a correction for χ^2 test when more than 25% of cells have a count of less than five in tables ($>2 \times 2$).

Quantitative data

Parametric tests: Student's *t*-test was used to compare two independent groups.

One-way analysis of variance test was used to compare more than two independent groups with post-hoc Tukey test to detect pairwise comparison.

Nonparametric tests: Mann–Whitney *U* test was used to compare two independent groups.

Kruskal–Wallis test was used to compare more than two independent groups with Mann–Whitney *U* test to detect pairwise comparison.

Correlation

Spearman's correlation

Spearman's rank-order correlation is used to determine the strength and direction of a linear relationship between two non-normally distributed continuous variables and/or ordinal variable.

Results

The study group included 24 cases (18 women and six men). The sex ratio is three: The patients' ages ranged between 20 and 60 years (minimum–maximum: 27.0–57.0), with a mean age of 41.29 ± 8.17 (Table 1).

The ICD is statistically significantly higher in the study group than the control group ($P=0.01$) (Table 2 and Fig. 3).

There was statistically significant correlation between adenoma size and the ICD ($P=0.04$) (Table 3).

Statistically significant difference between ICD and the type of sellar pathology was seen. The highest distance was in suprasellar lesions (mean = 8.93 ± 2.09), which was of statistical significance ($P_1=0.009$) and the least distance was in sellar lesions (mean = 16.58 ± 1.94) (Table 4 and Fig. 4).

Discussion

Endoscopic trans-sphenoid surgery has become the standard approach for the removal of pituitary adenomas. This is achieved by minimal trauma to the surrounding tissues with no brain retraction [10]. The most dangerous complication during this approach is ICA injury and its catastrophic outcomes [11].

Table 1 Demographic characteristics of the study group

	n=24 [n (%)]
Age (years)	
20-	2 (8.3)
30-	8 (33.3)
40-	9 (37.5)
50-60	5 (20.8)
Mean±SD	41.29±8.17
Minimum-maximum	27.0-57.0
Sex	
Male	6 (25.0)
Female	18 (75.0)

Table 2 Comparison of intercarotid distance between the study and control groups

	Study group (n=24)	Control group (n=24)	Test of significance
Intercarotid distance	23.70±4.86	20.29±4.39	t=2.55 P=0.01*

*Statistically significant.

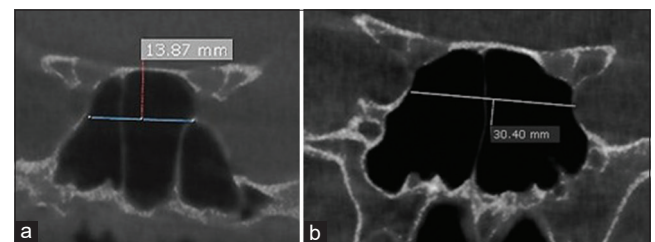
Table 3 Correlation between adenoma size and intercarotid distance among the study group

	Adenoma size	
	r_s	P
Intercarotid distance (mm)	0.43	0.04*

* $P<0.05$. r_s , Spearman's correlation coefficient

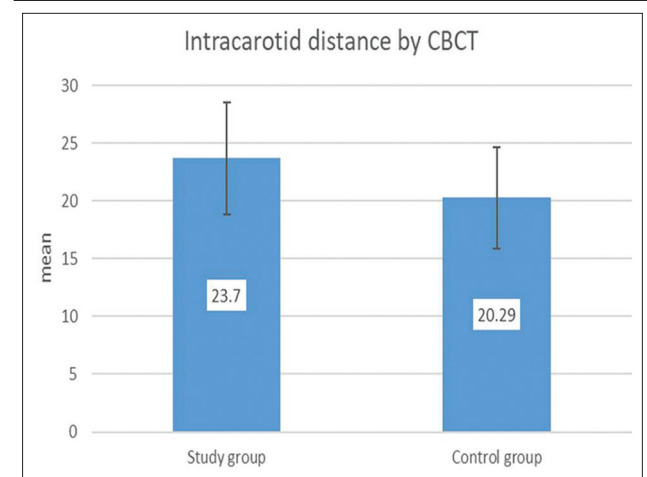
Different literatures studied the variation of ICD of parasellar ICA in pituitary adenomas. Hamid *et al.* [12] in their study on patients with pituitary adenomas reported that the mean of MRI measurements was about 23 mm. Sasagawa *et al.* [13] in their study showed that the ICD average was about 20.09 mm. Lin *et al.* [14] in their MRI study in cases with nonfunctioning adenomas reported ICD

Figure 2



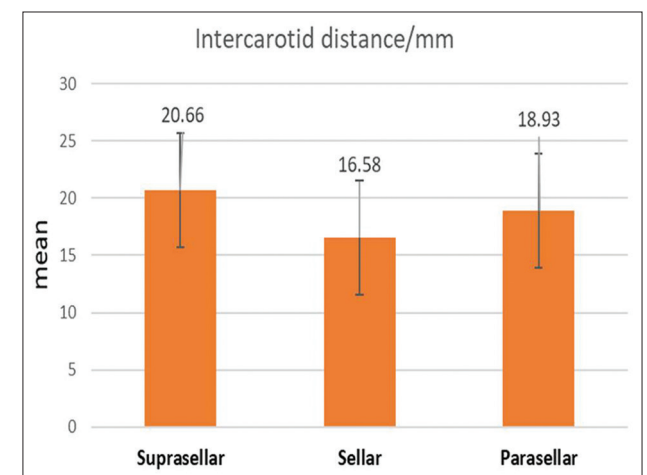
(a) Minimum and maximum measured intercarotid distance in the study group. (b) Horizontal segment of intracavernous ICA

Figure 3



Intercarotid distance in the study and control groups.

Figure 4



Association between adenoma extension and intercarotid distance among the study group.

Table 4 Association between adenoma extension and intercarotid distance among the study group

	Adenoma extension			Test of significance
	Suprasellar (n=8)	Sellar (n=8)	Parasellar (n=8)	
Intercarotid distance (mm)	20.66±4.02 ^a	16.58±1.94 ^a	18.93±2.09	F=4.15 P=0.03* P ₁ =0.009* P ₂ =0.24 P ₃ =0.11

Similar superscripted letters denote significant difference between groups. *F*, one-way analysis of variance test. *Statistically significant (if $P < 0.05$).

measurements of about 23.69 mm. Nunes *et al.* [15] reported measurements of about 24.3 mm. The results of the present study found that the measurement range was about 23.70 ± 4.86 mm with minimal variations from previous studies.

In controls with no sellar lesions, literatures studied the ICD reported convergent measures. Knappe *et al.* [16] in their MRI study found the ICD was about 17.8 mm. Perondi *et al.* [17] in their study on fresh cadaveric heads reported that the measurements was about 18 mm. Nunes *et al.* [15] reported measurements of about 19.4 mm. Ismaila *et al.* [18] reported in their cadaveric study that the ICD range was about 18–20 mm. Farımaz *et al.* [19] in their study on Turkish individuals reported measurements of 16.5 mm. The present study showed that the ICD measurements were about 20.29 ± 4.39 . The results of the present study support the findings of the previous study.

The present study reported that the ICD was higher in the study group (23.70 ± 4.86) than the control group (20.29 ± 4.39), with a difference of statistical significance ($P=0.01$). This highly supports the findings of Nunes *et al.* [15], who reported high statistical difference between cases and controls ($P=0.001$). These data document significantly the lateral displacement of parasellar ICA in sellar and peri-sellar lesions.

Lin *et al.* [14] and Nunes *et al.* [15] reported linear relationship between the size of adenomas and ICA lateral displacement and thereby increase in ICD. They reported higher measurements of ICD in patients with larger pituitary adenomas than those with smaller lesions. These findings are supported by the findings of this study, as the present study found a statistically significant difference between ICD and adenoma size ($P=0.04$). These data denotes the direct effect of lesion size on the ICA which will be displaced laterally with more increase in the intervening distance.

In this study, wider ICD is found in lesions with suprasellar extension of high statistical difference ($P_1=0.009$). This is in agreement with Hamid *et al.* [12], who reported that cases with macroadenomas with extrasellar extension showed higher ICD than those with microadenomas. This can be explained by adenomas with suprasellar extension usually presenting larger than those with parasellar extension

as the craniocaudal extension of sellar lesions is easier and more silent. So, these lesions usually present with a larger size. The growing lesion will be limited by the diaphragma sellae at certain stage making the expansion effect direct laterally. Displacement of the ICA will be encountered, while the lesion is still asymptomatic.

Conclusion

The measurement of ICD and its variations is feasible preoperatively and reproducible for operative planning in trans-sphenoidal approach. Patients with pituitary adenomas have wider ICD than normal individuals. The size of the adenomas directly affects the ICD with larger adenomas showing a wider ICD.

Declaration of patient consent

The authors certify that they have obtained all appropriate patient consent forms. In the form the patient(s) has/have given his/her/their consent for his/her/their images and other clinical information to be reported in the journal. The patients understand that their names and initials will not be published and due efforts will be made to conceal their identity, but anonymity cannot be guaranteed.

Financial support and sponsorship

Nil.

Conflicts of interest

There are no conflicts of interest.

References

- García-Garrigós E, Arenas-Jiménez JJ, Monjas-Cánovas I, Abarca-Olivas J, Cortés-Vela JJ, De La Hoz-Rosa J, *et al.* Transsphenoidal approach in endoscopic endonasal surgery for skull base lesions: what radiologists and surgeons need to know. *Radiographics* 2015; 35:1170–1185.
- Varshney R, Zawawi F, Tewfik MA, Frenkiel S, Varshney, Rickul, *et al.* Endoscopy-an Advancement in Sinus and Skull Base Surgery. *Endoscopy* 2013:121.
- Selim SM. Endoscopic endonasal transsphenoidal surgery for management of pituitary macroadenomas with suprasellar and parasellar extensions. *Al-Azhar Assiut Med J* 2015; 13:2.
- Padhye V, Valentine R, Wormald PJ. Management of carotid artery injury in endonasal surgery. *Int Arch Otorhinolaryngol* 2014; 18(S 02):S173-S178.
- Fujii K, Chambers S, Rhoton J. Neurovascular relationships of the sphenoid sinus. A microsurgical study. *J Neurosurg* 1979; 50:31–39.
- Weidenbecher M, Huk W, Iro H. Internal carotid artery injury during

- functional endoscopic sinus surgery and its management. *Eur Arch Otorhinolaryngol* 2005; 262:640–645.
- 7 Evans MD, James J, Amenta MD, Peter S, Mansouri MD, Farrell MD, *et al.* Prevention and management of bleeding during endoscopic approaches to skull base pathologies. *JHN J* 2015; 10:6.
 - 8 Berker M, Aghayev K, Saatci I, Palaoğlu S, Önerci M. Overview of vascular complications of pituitary surgery with special emphasis on unexpected abnormality. *Pituitary* 2010; 13:160–167.
 - 9 Gupta T. An anatomical study of inter carotid distances in the sellar region with a surgical perspective. *Brazil J Morphol Sci* 2009; 26:23–26.
 - 10 Cavallo LM, Messina A, Cappabianca P, Esposito F, de Divitiis E, Gardner P, *et al.* Endoscopic endonasal surgery of the midline skull base: anatomical study and clinical considerations. *Neurosurg Focus* 2005; 19:1–4.
 - 11 Romero AD, Ial Gangadharan J, Bander ED, Gobin YP, Anand VK, Schwartz TH. Managing arterial injury in endoscopic skull base surgery: case series and review of the literature. *Oper Neurosurg* 2016; 13:138–149.
 - 12 Hamid O, El Fiky L, Hassan O, Kotb A, El Fiky S. Anatomic variations of the sphenoid sinus and their impact on trans-sphenoid pituitary surgery. *Skull Base* 2008; 18:009–15.
 - 13 Sasagawa Y, Tachibana O, Doai M, Akai T, Tonami H, Iizuka H. Internal carotid arterial shift after transsphenoidal surgery in pituitary adenomas with cavernous sinus invasion. *Pituitary* 2013; 16:465–470.
 - 14 Lin BJ, Chung TT, Lin MC, Lin C, Hueng DY, Chen YH, *et al.* Quantitative analysis of anatomical relationship between cavernous segment internal carotid artery and pituitary macroadenoma. *Medicine* 2016; 95:e5027.
 - 15 Nunes CF, Cabral GA, Mello Junior JO, Lapenta MA, Landeiro JA. Pituitary macroadenoma: analysis of intercarotid artery distance compared to controls. *Arqu Neuropsiquiatr* 2016; 74:396–404.
 - 16 Knappe UJ, Jausch-Hancke C, Schönmayr R, Lörcher U. Assessment of normal perisellar anatomy in 1.5 T T2-weighted MRI and comparison with the anatomic criteria defining cavernous sinus invasion of pituitary adenomas. *Central Eur Neurosurg* 2009; 70:130–136.
 - 17 Perondi GE, Isolan GR, de Aguiar PH, Stefani MA, Falcetta EF. Endoscopic anatomy of sellar region. *Pituitary* 2013; 16:251–259.
 - 18 Ismaila M, Abdelhakb B, Michela O. Endoscopic sphenoid sinus anatomy in view of transsphenoidal surgery. *Egypt Soc Ear Nose Throat Allied Sci* 2018; 19:38–44.
 - 19 Farımaz M, Çelik HH, Ergun KM, Akgöz A, Urfalı B. The morphometry of the cavernous part of the internal carotid artery. *Folia Morphol* 2019; 78:54–62.