

Role of static MRI in assessment of velopharyngeal insufficiency

Tarek M. Y. El Banoby^a, Fawzy A. Hamza^a, Mahmoud I. Elshamy^b, Amro M. A. Ali^c, Ahmed A. Abdelmonem^d

Departments of ^aPlastic and Reconstructive Surgery and ^bDiagnostic Radiology, Al-Azhar University, ^cDepartment of Plastic Surgery, Egyptian Ministry of Health, Beni-Suef, ^dDepartment of Phoniatics, Beni-Suef University, Beni-Suef, Egypt

Correspondence to Ahmed A. Abdelmonem, 13th Mostafa Galal Street, Beni-Suef 62511, Egypt
Tel: +20 122 222 7210; Fax:- 0822351570;
e-mail: dr_ahmed_speech@yahoo.com

Received 27 October 2019

Accepted 07 May 2020

Published 30 June 2020

Pan Arab Journal of Rhinology
2020, 10:21–26

Aim

The purpose of this study was evaluation of static MRI in assessment of VPI and correlation to auditory perceptual assessment (APA) and nasoendoscopy.

Background

Velopharyngeal insufficiency (VPI) occurs owing to insufficient tissues of the velopharyngeal valve.

Patients and methods

This was a multidisciplinary prospective study conducted at Al-Azhar and Beni-Suef University Hospitals, Egypt. The study group consisted of 20 children with VPI postpalatoplasty, aged from 3 to 9 years. Normal MRI values were obtained from Ruotolo et al, and Perry et al. Patients were evaluated by history taking, Gutzman's and Czermark's tests, APA, nasoendoscopy, and static palatal MRI.

Results

APA revealed that most of the patients had bad speech scales. Nasoendoscopy revealed that most of patients had concave velum, absent posterior pharyngeal wall movement, and circular velopharyngeal gap. MRI revealed that patients' velopharyngeal parameters were significantly lower than normal values, and most of patients had symmetrical muscle limbs. Velar length and thickness had a significant positive linear correlation with degree of velar movement. Effective velar length had a moderate negative correlation with degree of velar movement and degree of open nasality.

Conclusion

Static MRI is an important tool in assessment of VPI but should be accompanied by dynamic tools in cases with relatively normal ranged anatomy.

Keywords:

nasoendoscopy, static palatal magnetic resonance image, velopharyngeal insufficiency

Pan Arab J Rhinol 10:21–26

© 2020 2090-7640

Introduction

During the closure of velopharyngeal valve, there must be a coordination of all structures, like a sphincter [1]. Normal velopharyngeal valve serves to close off the nasal cavity from the oral cavity during utterance of oral sounds, and it is open during utterance of nasal sounds like /m/, /n/ [2]. Dysfunction of this mechanism leads to velopharyngeal dysfunction (VPD). Velopharyngeal insufficiency (VPI) is the first major diagnostic category of VPD, and this term denotes an anatomic defect causing inadequate closure of the valve, and it needs surgical repair [3].

There are many procedures used in the diagnosis of speech abnormalities of patients of VPI: first, auditory perceptual assessment; second, simple clinical tests: (a) Czermark's test (Cold Mirror test) and (b) Gutzmann test (A/I test); and third, nasoendoscopy [4].

In Czermark's test (Cold Mirror test), the phoniatician should place a small dental mirror under the patient's nares during his/her utterance of pressure-sensitive oral sounds. If the mirror fogs, it indicates nasal air emission. A problem with this test is that the mirror needs to be placed under the nose after the individual

starts speaking and removed before the individual stops speaking to avoid fogging as a result of nasal breathing.

In the Gutzmann test, the patient is asked to produce series of /a/ and /i/ sounds alternately with the nares held open and closed. A change in vowel quality when the patient produced the vowels with the nares closed was considered indicative of the existence of hypernasality, in which case a score of 1 was assigned. Absence of change was assigned a score of 0.

Magnetic resonance imaging is one of the common tests in medicine and surgery. The exact position of the muscle and the efficient muscle mass are important factors regarding the reconstructed musculature for speech purposes [5].

This study aims to evaluate the validity of static MRI in assessment of postpalatoplasty VPI and correlation of MRI data with auditory perceptual assessment (APA) and nasoendoscopy.

This is an open access journal, and articles are distributed under the terms of the Creative Commons Attribution-NonCommercial-ShareAlike 4.0 License, which allows others to remix, tweak, and build upon the work non-commercially, as long as appropriate credit is given and the new creations are licensed under the identical terms.

Materials and methods

This cross-sectional study was conducted in Egypt in Al-Azhar and Beni-Suef University Hospitals, from February 2019 to November 2019, on 20 cases who had VPI post palatoplasty, performed by a multidisciplinary team, involving plastic surgeons, radiologist, and phoniatrician.

All participants in the study group were included according to the following inclusion criteria: first, repaired cleft soft palate (by intravelar veloplasty technique) and second, age at least 3 years old. Exclusion criteria were first, velopharyngeal incompetency, for example, motor neuron disease, myotonias, and dysarthria; second, mentally retarded uncooperative patients; and third, hypernasality owing to non-VPI (patients with functional nasality or oronasal fistula).

Patients who had postoperative hypernasality were evaluated by the following:

- (1) Patient and parents' interview and history taking: the first tool to get full history about medical history, surgical history, and speech assessment
- (2) Speech evaluation:
 - (a) Auditory perceptual speech assessment: the speech sample included syllables, single words, sentences, and automatic speech. It was documented by high-fidelity audio recording and analyzed as follows: first, degree of open nasality (graded from 0 to 4, where 0 means no hypernasality, and 4 is the maximum hypernasality); second, imprecision of consonants (graded from 0 to 4, where 0 means no imprecision of consonants, and 4 is the maximum imprecision of consonants); third, compensatory glottal articulation (graded from 0 to 4, where 0 means no glottal articulation, and 4 is the maximum glottal articulation); fourth, pharyngealization of fricatives (graded from 0 to 4, where 0 means no pharyngealization, and 4 is the maximum pharyngealization); fifth, audible nasal emission of air (graded from 0 to 4, where 0 means no audible nasal air emission, and 4 is the maximum audible nasal air emission); sixth, overall intelligibility (graded from 0 to 4, where 0 means the least intelligibility, and 4 is the best speech intelligibility); and seventh, nasal grimace (graded from 0 to 4, where 0 means no nasal grimace, and 4 is the maximum nasal grimace)
 - (b) Simple clinical tests: Czermark's (cold mirror) test and Gutzman's (A/I) test.
- (3) Flexible nasopharyngeal endoscopic evaluation of the velopharyngeal valve: it was done based on

the following parameters: first, velar morphology, either concave, convex, or flat; second, degree of velar movement (graded from 0 to 4; 4 is the best); third, right pharyngeal wall movement (graded from 0 to 4; 4 is the best); fourth, left pharyngeal wall movement (graded from 0 to 4; 4 is the best); fifth, posterior pharyngeal wall movement, either present or absent; sixth, adenoids, either present or absent; and seventh, velopharyngeal gap shape, either coronal, circular, or sagittal

- (4) Static palatal MRI: sedation was given to children who cannot tolerate MRI procedure. Chloral hydrate was used (as a dose of 50–75 mg/kg/dose 30–60 min before the procedure). A 1.5T MRI imaging system was used to perform the procedure. A commercially available head coil was used to acquire more accurate images. Each patient was placed in the standard supine position with his/her head perpendicular to the table. T2-weighted sagittal scan images were initially included to confirm the field of oblique coronal images and accurate analysis of measurements from sagittal plane. T2-weighted oblique coronal images were obtained with angle perpendicular to the velar plane obtained from sagittal images to view levator veli palatini (LVP) muscle measurements. T2-weighted coronal scan images were finally obtained to view coronal measurements.

MRI analysis

The results of this study were compared with normal MRI values, which was obtained from previous literatures [6,7], and the data were analyzed to obtain the following measures:

- (1) Sagittal measures: first, cranial measures, which included face height, anterior cranial base angle, nasion to sella, sella to basion, sagittal angle, and hard palate length; and second, velar measures, which included velar length, velar thickness, osseous pharyngeal depth, pharyngeal depth, effective velar length, and adenoid thickness
- (2) Oblique coronal view: it included velar measures, such as LVP muscle length, LVP muscle thickness, angle of origin, and origin to origin distance
- (3) Coronal measures: it included cranial measures, such as maximum head diameter, face width, palate width, and palate height.

Intra-rater reliability was used by the same physician across multiple instances to ensure the consistency of scores. Parents of participants provided informed consent. This research received Research Ethical Committee Approval from Faculty of Medicine, Beni-Suef University (FMBSUREC/01102019/Abdel

Monem), and also it received the Ethical Committee Approval of Al-Azhar University.

Statistical analysis

Description of quantitative variables was in the form of mean, SD, minimum and maximum. Description of qualitative variables was in the form of numbers and percentage. One sample *t*-test was used to detect difference between the normal parameters and patient parameters. Pearson’s correlation was used to correlate between scale data, and (*r*) correlation coefficient was either positive (+) or negative - and ranged from 0 to 1, where **r* = 0 to less than or equal to 0.3 is weak correlation. **r* = 0.3 less than or equal to 0.6 is moderate correlation. **r* greater than 0.6 is strong correlation. The significance of the results was assessed in the form of *P* value and was differentiated into the following: non-significant when *P* value greater than 0.05, significant when *P* value less than or equal to 0.05, or highly significant when *P* value less than or equal to 0.001.

Results

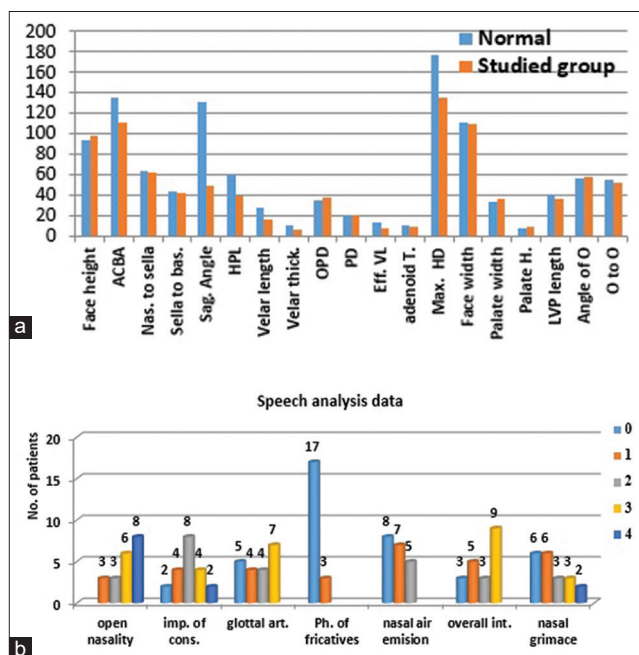
The results of Czermak’s test and Gutzman’s test were positive in all patients in the study. APA revealed

that most of the patients had bad speech scales, as in Fig. 1a (Table 1), and flexible nasoendoscopic examination revealed that most of patients had concave velar morphology, absent posterior pharyngeal wall movement, and circular velopharyngeal gap shape, as shown in Table 2.

Static MRI revealed that patients’ MRI parameters were significantly lower than normal values, except face height, nasion to sella, ossified pharyngeal depth, pharyngeal depth, adenoid thickness, face width, palate width, and angle of origin, which did not differ significantly from normal values (*P* > 0.05), as shown in Fig. 1b. Most patients in the study had symmetrical muscle limbs, as shown in Fig. 2a. There were nine patients with intact central muscle insertion and 11 patients with defective central muscle insertion, as shown in Fig. 2b.

Regarding correlation data between MRI and speech analysis and nasoendoscopy (Table 3), the velar length

Figure 1



(a) Comparison between the normal values [6,7] and the studied values of MRI parameters. (b) Description of speech parameters for patients in this study. ACBA, anterior cranial base angle; art., articulations; bas., Basion; Eff. VL, effective velar length; HPL, hard palate length; imp., imprecision; int., intelligibility; nas., nasion; O, origin; OPD, osseous pharyngeal depth; PD, pharyngeal depth; ph., pharyngealization; Sag., sagittal; Th., thickness.

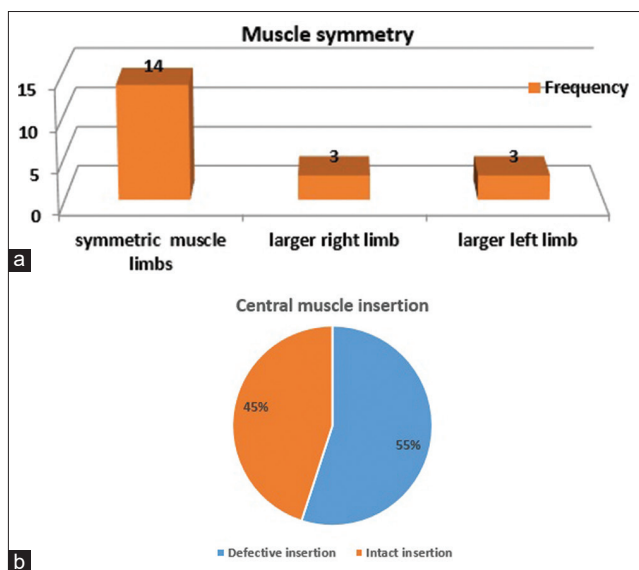
Table 1 Description of age and sex of patients

	Mean	SD	Minimum	Maximum	Median
Age (years)	5.45	1.76	3	9	5
Sex		Male		Female	
%		45%		55%	

Table 2 Distribution of flexible nasoendoscopic parameter grades of patients in the study

Flexible nasoendoscopy	Frequency	%
Velar morphology		
Concave	10	50.0
Convex	1	5.0
Short	9	45.0
Degree of velar movement		
0	2	10.0
1	7	35.0
2	8	40.0
3	3	15.0
Right pharyngeal wall movement		
0	1	5.0
1	7	35.0
2	12	60.0
Left pharyngeal wall movement		
1	7	35.0
2	13	65.0
Posterior pharyngeal wall movement		
Absent	15	75.0
Present	5	25.0
Adenoids		
Absent	6	30.0
Present	14	70.0
Velopharyngeal gap shape		
Circular	13	65.0
Coronal	2	10.0
Sagittal	5	25.0

Figure 2



(a) Description of muscle symmetry state detected by MRI. (b) Percentage of central muscle insertion state detected by MRI.

Table 3 Significant correlation between MRI data and speech and nasoendoscopic data

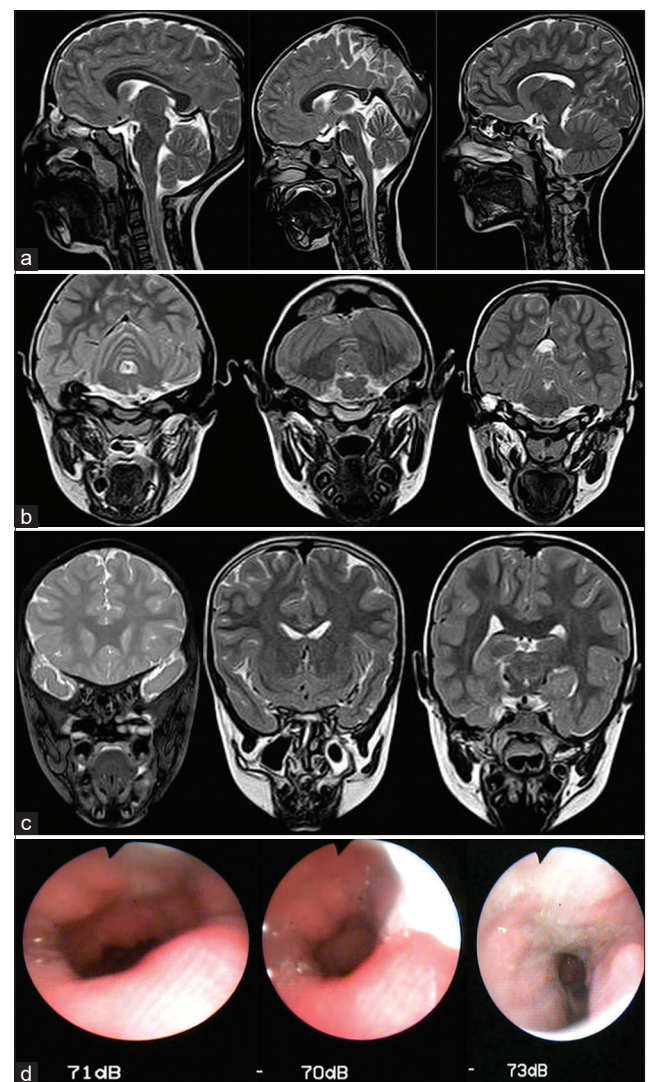
	Velar thickness	Velar length	Effective velar length
Degree of open nasality			
<i>r</i>	-0.289	-0.386	-0.489*
<i>P</i>	0.216	0.092	0.029
Overall intelligibility			
<i>r</i>	0.459*	0.437	0.270
<i>P</i>	0.042	0.054	0.249
Degree of velar movement			
<i>r</i>	0.515*	0.741**	0.552*
<i>P</i>	0.020	<0.001	0.018

*Correlation is significant at the 0.05 level. **Correlation is significant at the 0.01 level.

had a significant strong positive linear correlation with degree of velar movement, and velar thickness had a significant moderate positive linear correlation with degree of velar movement and the overall intelligibility. There was no significant linear correlation between the pharyngeal depth and speech or nasoendoscopic parameters. There was no significant linear correlation between (the LVP length, LVP thickness) and speech or nasoendoscopic parameters. There was no significant linear correlation between the LVP center defect and speech or nasoendoscopic parameters. Effective velar length had a moderate negative correlation with degree of velar movement and degree of open nasality.

The mean nasal grimace was statistically significant higher in patients who had symmetric muscles (1.93 ± 1) than who had asymmetric muscles (0.33 ± 0.16). Figure 3 showing MRI views comparing to pharyngeal gap shape obtained by nasoendoscopy; for some cases conducted in the study.

Figure 3



Examples of some cases in the study. *(I, II, III) Number of patients in the study; (a) Midsagittal view by MRI. (b) Oblique coronal views by MRI. (c) Coronal views by MRI. (d) Velopharyngeal gap shape by nasoendoscopy.

Discussion

MRI offers an imaging method that is noninvasive and non-radiating; there are static and dynamic types of palatal MRI. Dynamic MRI procedures have many limitations like sedation that is given to uncooperative children. Therefore, in this study, we discuss the validity of static palatal MRI in assessment of VPI compared with the most popular traditional procedure, nasoendoscopy. Approximately 30% of postpalatoplasty patients require secondary surgery for VPD repair [8], and according to Al-Azhar University Departmental technique in soft palate repair (intravelar veloplasty), the same percent of postpalatoplasty patients need secondary procedures for VPI; the same surgical outcomes explain the importance of evaluation by MRI.

Ettema *et al.* [9] explored the role of MRI in evaluation of patients with cleft palate before and after primary

palatoplasty with attention focused on the LVP muscle. This study included one female infant with normal anatomy and three male and four female infants with cleft palate of varying severity, and they found that MRI is a viable imaging modality for the evaluation of the anatomy of the LVP muscle. Ruotolo *et al.* [6] assessed VP structure in patients with 22q11.2 deletion syndrome by using MRI analysis, and they found that these patients demonstrated significant alterations in VP anatomy that may contribute to VPD. Perry *et al.* [7] examined differences in velopharyngeal structures between adults with repaired cleft palate and normal resonance and adults without cleft palate, and they found that despite significant differences were evident in the cleft palate group, they displayed normal resonance. Perry *et al.* [10] detected the growth of the various craniofacial and velopharyngeal structures and examined sex and race effects in normal children, so, there was a need for a study to evaluate validity of static palatal MRI with many characters; more children included than previous studies, more MRI parameters, and correlation between the static MRI data and speech data obtained by APA and nasopharyngoscopy.

In this study, patients' age ranged from 3 to 9 years, with a median of 5 years, that is, this is the suitable age for VPD repair procedures, as younger than 3 years children cannot articulate properly, and above 9 years, they cannot correct the mislearning. Gutzmann's test (A/I test) and Czermark's test (cold mirror) were positive in all patients in the study. Most of the patients had speech abnormality as detected by APA. Therefore, Gutzmann and Czermark's tests are simple clinical tests and are significant in diagnosis of hypernasality. Patients' MRI parameters, in particular, velopharyngeal parameters were significantly lower than normal MRI values [6,7], whereas they were not differing significantly from normal values in most of craniofacial values, so it means that static MRI can detect properly the defective velopharyngeal structures in patients with VPI. Most of the patients in the study had symmetrical muscle limbs, so it means that patient may have speech abnormality despite symmetrical muscle limbs, and this explains the importance of dynamic procedures (Nasoendoscopy) in these cases. There were nine patients who had intact central muscle insertion and also had speech abnormality, so this also ensures the importance of dynamic procedures in these cases.

Regarding the correlation between MRI data and speech analysis and nasoendoscopic data, the velar length had a significant strong positive linear correlation with degree of velar mobility, which means that velar length is a strong factor in velar mobility, that is, increasing velar length will make velar mobility

powerful, whereas velar thickness had a significant moderate positive linear correlation with degree of velar movement and the overall intelligibility, which means that velar thickness is a strong factor in velar mobility and hence speech articulation, that is, increasing velar thickness will make velar mobility more powerful.

There was no significant linear correlation between the pharyngeal depth and speech analysis or nasoendoscopic parameters. It means that pharyngeal depth is a cofactor in speech mechanism, and it may be compensated by many mechanisms as velar stretch, adenoids hypertrophy, and/or lateral pharyngeal walls. There was no significant linear correlation between the levator muscle length and thickness and speech or nasoendoscopic parameters and no significant linear correlation between the LVP center defect and speech analysis or nasoendoscopic parameters, which means that static muscle length, thickness, and center insertion state are not strong factors in speech articulation. The mean nasal grimace was statistically significantly higher in patients who had symmetric muscle limbs than who had asymmetric muscles. Therefore, in patients with average levator muscle dimensions, this also ensures the importance of dynamic procedures in these cases.

There was a significant linear moderate negative correlation between degree of velar movement with the effective velar length but a moderate negative correlation between the effective velar length and degree of open nasality. It means that exact position of levator muscle is a strong factor in powerful velar mobility and hence speech articulation.

This study proves that static MRI is an important radiological tool in diagnosis of structural disorders in patients with VPI, especially as it is a magnetic noninvasive tool, but should be accompanied by dynamic tool (nasopharyngoscopy) in cases of speech abnormality with relatively normal ranged anatomy.

In this study, MRI was a very safe procedure, but occasional complications have occurred, as metal objects (such as jewelry) worn during the scan have caused injury; moreover, some sedation complications have occurred, such as temporary confusion, nausea, shivering, and delayed recovery, and some nasoendoscopic complications have occurred like discomfort and bruising.

There were many restrictions to this study like patient's age group and choosing patients of isolated VPI.

Dynamic MRI is used commonly in adults, and we hope to expand the use of dynamic MRI for children to assess the muscles dynamically.

Financial support and sponsorship

Nil.

Conflicts of interest

There are no conflicts of interest.

References

- 1 MacNeilage PF. *The Origin of Speech*. Oxford, England: Oxford University Press; 2010.
- 2 Marchal A. *From Speech Physiology to Linguistic Phonetics*. New Jersey, USA: John Wiley & Sons; 2010.
- 3 Naran S, Ford M, Losee JE. What's new in cleft palate and velopharyngeal dysfunction management? *Plast Reconstr Surg* 2017; 139:1343e–1355e.
- 4 Kummer AW. *Cleft Palate & Craniofacial Anomalies: Effects on Speech and Resonance*. Toronto, Canada: Nelson Education 2013.
- 5 Perry JL, Kuehn DP, Sutton BP. Morphology of the levator veli palatini muscle using magnetic resonance imaging. *Cleft Palate Craniofac J* 2013; 50:64–75.
- 6 Ruotolo RA, Veitia NA, Corbin A, McDonough J, Solot CB, McDonald-McGinn D, *et al*. Velopharyngeal anatomy in 22q11. 2 deletion syndromes: a three-dimensional cephalometric analysis. *Cleft Palate Craniofac J* 2006; 43:446–456.
- 7 Perry JL, Kotlarek KJ, Sutton BP, Kuehn DP, Jaskolka MS, Fang X, *et al*. Variations in velopharyngeal structure in adults with repaired cleft palate. *Cleft Palate Craniofac J* 2018; 55:1409–1418.
- 8 Rodriguez ED, Losee JE, Neligan PC. *Plastic Surgery E-Book: Volume 3: Craniofacial, Head and Neck Surgery and Pediatric Plastic Surgery*. New York, USA: Elsevier Health Sciences 2017.
- 9 Ettema SL, Kuehn DP, Goldwasser MS, Barkmeier JC. Magnetic resonance imaging of the levator veli palatini muscle before and after primary palatoplasty. *Cleft Palate Craniofac J* 2004; 41:584–592.
- 10 Perry JL, Kollara L, Kuehn DP, Sutton BP, Fang X. Examining age, sex, and race characteristics of velopharyngeal structures in 4- to 9-year-old children using magnetic resonance imaging. *Cleft Palate Craniofac J* 2018; 55:21–34.