

Challenges and controversies in endoscopic management of cerebrospinal fluid rhinorrhea

Mostafa ElTaher^a, Mohamed Ahmed^a, Ahmad Ismail^a, Usama Taya^b

^aDepartment of ENT, Sohag University, Sohag,
^bDepartment of ENT, South Valley University,
Qena, Egypt

Correspondence to Mostafa ElTaher, MD,
Department of ENT, Sohag University, Sohag
University Hospitals, Sohag, Egypt
Tel: +20 103 271 3236; Fax: +20 934 602 963;
e-mail: mostafaent@yahoo.com

Received 01 December 2019

Accepted 07 May 2020

Published 30 June 2020

Pan Arab Journal of Rhinology
2020, 10:17–20

Introduction

Endoscopic management of cerebrospinal fluid (CSF) rhinorrhea is considered by many as the ideal approach due to its low morbidity and higher closure rate. However, many challenges and controversies are still reported.

Objective

The aim was to discuss the challenges of endonasal repair of CSF leaks and controversies regarding the use of intrathecal fluorescein (ITF) and the number of graft layers.

Materials and methods

This retrospective study included 30 patients who had had endoscopic repair for their CSF rhinorrhea in our institute between July 2015 and June 2017. Fifteen (50%) patients were managed using the two-layer repair without ITF injection (group I), while the remaining were managed using three or more graft layers and ITF (group II).

Results

The study included 30 patients: 17 (57%) women and 13 (43%) men. Their age ranged from 4 to 68 years with mean \pm SD = 38 ± 15.86 years. Eighteen cases presented with spontaneous leaks (nine of them had normal CSF pressure). Four (13.3%) cases had defects in the posterior wall of the frontal sinus while other defects involved the fovea ethmoidalis, lateral lamella, and the cribriform plate of the ethmoid. Success rate was equal in both groups (93%).

Conclusion

Endoscopic management of CSF rhinorrhea has many challenges including repair in the pediatric population and anatomical areas with difficult accessibility, for example, frontal sinus leaks. It requires good endoscopic visualization and endoscopic instrumentation facilities in addition to experienced surgical hands. Double-layer repair and avoidance of ITF show the same success rate as other more time-consuming strategies with life-threatening complications.

Keywords:

CSF, Endoscopic, Challenges, rhinorrhea

Pan Arab J Rhinol 10:17–20
© 2020 2090-7640

Introduction

Endoscopic management of cerebrospinal fluid (CSF) rhinorrhea is known to provide accurate repair and least operative morbidity; however, several factors including the site, size, and cause of the leak together with overall medical condition may affect the results and prognosis [1].

Endoscopic skull base surgeons may be confronted with many challenges during the repair of CSF leak; localizing the leakage site may be difficult even for experienced surgeons, dealing with large defects, operating in anatomic areas with difficult accessibility while keeping patency of sinus drainage and managing pediatric patients [2–4].

Controversies are present as regards the safety of intrathecal fluorescein (ITF), management of associated benign intracranial hypertension if present, and number of graft layers needed for efficient repair [5–8].

In this study, we compare between our present strategy for endoscopic treatment of CSF leakage using simple

steps without ITF injection and only two-layer repair of the skull base on simple or anatomically challenging cases in comparison to endoscopic endonasal approaches using ITF injection and multilayer repair. We also present our challenging pediatric case and frontal sinus leaks.

Materials and methods

The current retrospective study included 30 patients who had endoscopic repair for their CSF rhinorrhea in our institute between July 2015 and June 2017. Fifteen (50%) patients were managed without ITF injection for defect localization (with fluorescein available for topical use in case of difficult identification of the defect [9].) and two-layer repair (group I) while patients of the other

This is an open access journal, and articles are distributed under the terms of the Creative Commons Attribution-NonCommercial-ShareAlike 4.0 License, which allows others to remix, tweak, and build upon the work non-commercially, as long as appropriate credit is given and the new creations are licensed under the identical terms.

group (group II) were managed using ITF and three or more graft layers for repair.

Diagnosis was done depending on the clinical history, ENT, and detailed endoscopic examination, chemical analysis of the discharged fluid and imaging studies in the form of high-resolution computed tomography, and MRI. After careful analysis of clinical data, laboratory data, and imaging findings all patients underwent endoscopic repair of CSF rhinorrhea by senior authors. Polymeric silicone sheet was used for stenting the frontal sinus ostium to keep its patency when the sinus drainage is compromised by surgical maneuver. Postoperative intravenous antibiotic was given to all cases (third-generation cephalosporin) for 7 days starting from the day of surgery. Patients and their guardians were instructed against straining or nose blowing for a minimum period of 1 month and measures to decrease intracranial tension were followed especially in patients with diagnosed benign intracranial hypertension. Postoperative follow-up using nasal endoscopy was carried out on regularly increasing intervals till the first year and then every year. We considered no need for radiological follow-up as long as no new events are encountered. Institutional Ethics Committee approval was obtained. Quantitative data were expressed as percentages and quantitative data were expressed as mean \pm SD. (Data were analyzed by SPSS Inc. Released 2008. SPSS Statistics for Windows, Version 17.0. Chicago: SPSS Inc). χ^2 test and Fischer's exact test with a *P* value of less than 0.05 is considered to be significant.

Results

This study included 30 patients; 17 (57%) were women and 13 (43%) were men. Their age ranged from 4 to 68 years (mean \pm SD = 38 \pm 15.86 years) with a predominance in the age group of 31–40 years (30%), followed by 41–50 years (26.7%), and the least frequent age group being 11–20 years (3.3%); postoperative follow-up is extended for 2 years. Causes of CSF rhinorrhea included accidental trauma, iatrogenic trauma, and spontaneous CSF leakage.

Meningoencephalocele was encountered in seven (23.3%) cases, while meningocele was encountered in 10 (33.3%) cases. Data about etiology and site and size of skull base defect are illustrated in Tables 1–3, respectively. Twenty-nine of our cases were presented with unilateral CSF rhinorrhea; only one case was presented with bilateral CSF rhinorrhea due to bilateral skull base defect. Among the unilateral cases, 18 cases were right sided, and 11 cases were left sided. Among the 18 cases with spontaneous leaks, after measuring CSF pressure, we found nine cases with normal CSF

pressure. Seven cases with high CSF pressure received medical treatment for lowering CSF pressure and two cases necessitated the use of frequent lumbar drainage. There was no need for use of ventriculoperitoneal shunt in our cases. The size of the defect in cases managed by two-layer repair ranged from about 4 to 16 mm in diameter. Fibrofatty tissue from the ear lobule or nasal septal cartilage was used as the underlay graft according to the size of the defect with cartilage needed for larger defects while either mucosa from the lateral nasal wall or the fascia lata was used as the overlay second layer graft. Materials used in multilayer grafting included fat, nasal septal bone, nasal septal cartilage, fascia lata, middle turbinate, and nasoseptal mucosal flaps. The encountered postoperative complications are listed in Table 4.

The study included challenging cases: a 4-year-old child with a history of falling from height (Fig. 1) and

Table 1 Patient's distribution as regards etiology of cerebrospinal fluid leak

Etiology	Group I [n (%)]	Group II [n (%)]	Total [n (%)]
Spontaneous	11 (73.33)	7 (46.7)	18 (60.0)
Accidental trauma	3 (20.0)	3 (20.0)	6 (20.0)
Iatrogenic trauma	1 (6.66)	3 (20.0)	4 (13.3)
Tumor	0	2 (13.3)	2 (6.7)
Total	15 (100)	15 (100)	30 (100)

P=0.27.

Table 2 Defect site in the studied cases

Site of skull base defect	Group I [n (%)]	Group II [n (%)]	Total [n (%)]
Cribriform plate	8 (53.3)	3 (20)	11 (36.6)
Fovea of ethmoidalis	4 (26.6)	7 (46.6)	11 (36.6)
Lateral lamella	1 (6.6)	1 (6.6)	2 (6.6)
Frontoethmoid (roof of the ethmoid and posterior table of the frontal sinus)	2 (13.3)	3 (20)	5 (16.6)
Frontal sinus		1 (6.6)	1 (3.3)

P=0.37.

Table 3 Size of the defect in millimeters

Size of defect in mm	Group I [n (%)]	Group II [n (%)]	Total [n (%)]
0-5	7 (46.7)	12 (80)	19 (63.3)
6-10	2 (13.3)	2 (13.3)	4 (13.3)
>10	6 (40)	1 (6.7)	7 (23.3)
Total	15 (100)	15 (100)	30 (100)

P=0.087%.

Table 4 List of postoperative complications

Postoperative complication	Group I [n (%)]	Group II [n (%)]	Total [n (%)]
Headache	5 (33.3)	5 (33.3)	10 (33.3)
Temporary anosmia	8 (53.3)	6 (40)	14 (46.6)
Fever	1 (6.6)	1 (6.6)	2 (6.6)
Hemorrhage	0	1 (6.6)	1 (3.3)

cases with defects involving the posterior table of the frontal sinus (Fig. 2).

After initial endoscopic repair, one case that was managed by the multilayered technique repair (3.5%) failed to stop CSF rhinorrhea, while one case in group I (3.5%) had recurrence of leak after 20 months of follow-up and stopped by measures to decrease CSF pressure.

Discussion

Endoscopic management of CSF rhinorrhea has proved to be an efficient approach with decreased operative and postoperative morbidity. Identification of the leakage site is considered the most important step for successful management [1,10].

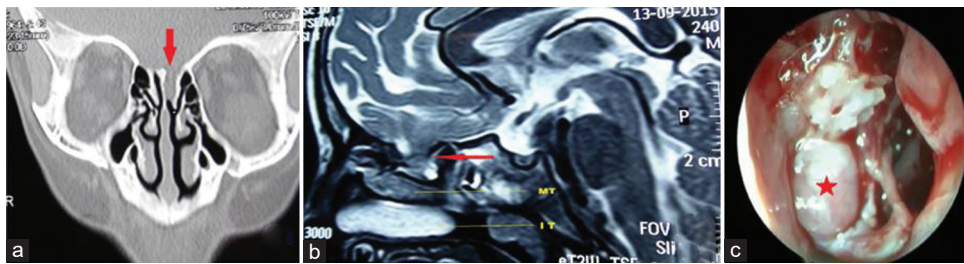
Localizing the defect through ITF injection which is elicited endoscopically from the site of the leak is well known in current practice; however, reported complications associated with ITF include headache, lower limb paresis/numbness, cranial nerve palsies, convulsions, and even death. Although many studies provided certain criteria for the safe use of ITF, it appears that there is still no guarantee for avoiding such complications [11,12]. Not only safety, but also the efficacy of ITF is debated. In addition to lengthening the operative time and the need for special anesthetic considerations, limitations in detecting the

defect and false negative results of the fluorescein test were reported in the literature. Topical application of fluorescein was recently introduced as a method for safe localization of the defect [8,13,14].

In group I cases, we relied on preoperative imaging studies in the form of high-resolution CT scans and MRI for localizing the defect site with topical fluorescein prepared for use when needed. We were able to perfectly localize the defect in all cases without the use of either intrathecal or topical fluorescein. Fortunately, ITF injection did not cause any complications and fluorescein was detected easily from the defect.

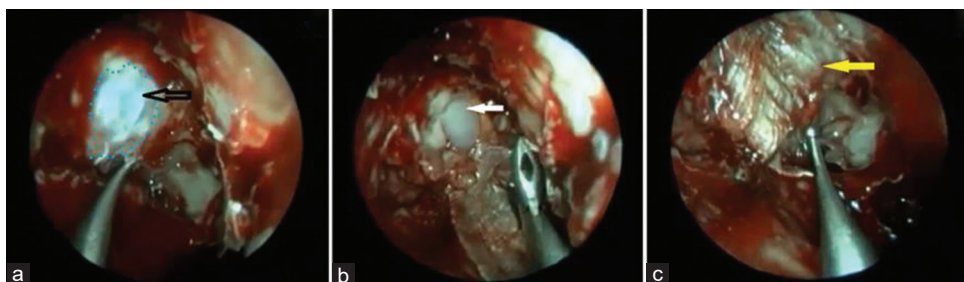It is reported that most cases of spontaneous CSF leak are associated with idiopathic intracranial hypertension (IIH). Frequent recurrences following surgical repair of spontaneous CSF leak is a challenging problem and controversies are present in literature reports as regards early and long-term management of increased intracranial pressure. Some authors recommended adjuvant use of lumbar drains for 3–5 days in cases of idiopathic leaks, posttraumatic leaks, and in cases with large meningocele. Others have advocated acetazolamide to decrease CSF production in the early postoperative period. Recurrence in such cases was claimed to occur late after 14 months. ElFiky and colleagues in 2015 argued that long-term management through CSF diversion is needed in patients with diagnosed IIH [15–17].

Figure 1



Posttraumatic cerebrospinal fluid leak in a 4-year-old child. (a) Coronal computed tomography shows defect in the (CP) cribriform plate opposite to the superior turbinate; (b) T2-weighted MRI in the sagittal plane showing meningoencephalocele; (c) endoscopic view showing the defect after resection of the meningoencephalocele, red asterisk: dura.

Figure 2



Endoscopic view. (a) Defect in the posterior table of the frontal sinus marked with blue dots and black arrow points to the dura; (b) white arrow points to cartilage graft applied between the dura and the bone; (c) yellow arrow indicates on-lay fascia lata graft.

In this study, we had 18 patients with spontaneous CSF leak; two of them had strong clinical and radiological evidence of IIH (obese middle-aged women with BMI ≥ 35 and imaging evidence of empty sella) [15]. All cases were managed by acetazolamide or frequent lumbar tapping. We avoided lumbar drains due to their potential complications and due to the need for prolonged hospital stay. Failure of repair occurred in one case from group II with persistent postoperative leak and recurrence was detected in one case from group I after a 20-month period.

Another challenging problem is the diagnosis and repair of posttraumatic CSF leaks in the pediatric population. The only presentation may be recurrent attacks of meningitis which should raise the suspicion for diagnosis. The narrow nasal fossa and limited surgical field in pediatric patients add to the technical difficulty of endoscopic CSF repair [18]. In this study, a 4-year-old child patient presented by recurrent attacks of meningitis and 1-year past history of falling from height was diagnosed to have posttraumatic meningoencephalocele with skull base defect located in the posterior half of the cribriform plate. The patient was successfully managed through the endoscopic approach. Defects involving the frontal sinus or frontal recess are not common but when present they need efficient anatomical knowledge and surgical skills for their endoscopic repair and simultaneously keeping patency of the sinus drainage pathway [3]. This study involved four cases of frontoethmoidal meningoencephalocele with defect extending to the posterior table of the frontal sinus; endoscopic approach was successful as regards defect repair and preserved sinus patency.

Some authors have described multilayer repair and using five layers of graft materials; they assume this promotes better healing in the postoperative period and mimic the natural barriers intervening between the nasal cavity and the cranial cavity [18]. We used only two layers in group I patients aiming to decrease donor site morbidity and to preserve the anatomical structure of the compromised nasal region as well as to decrease the operative time. There was no more benefit obtained from the multilayer repair as that conducted in group II as they had similar success rate. There was no difference in the outcome of double and multilayer repair of CSF leaks. However, the first technique has less operative time and less donor site morbidity.

Conclusion

Endoscopic management of CSF rhinorrhea has many challenges including repair in the pediatric population and anatomic areas with difficult accessibility, for

example, frontal sinus leaks. It requires good endoscopic visualization and endoscopic instrumentation facilities in addition to experienced surgical hands. Double-layer repair and avoidance of ITF show the same success rate as other more time-consuming strategies with life-threatening complications.

Financial support and sponsorship

Nil.

Conflicts of interest

There are no conflicts of interest.

References

- 1 Locatelli D, Rampa F, Acchiardi I, Bignami M, De Bernardi F, Castelnovo P. Endoscopic endonasal approaches for repair of cerebrospinal fluid leaks: nine-year experience. *Neurosurgery* 2006;58(4 Suppl 2): 246-255.
- 2 Friedberg SA, Galloway TC. Spontaneous cerebrospinal fluid rhinorrhea. *Ann Otol Rhinol Laryngol* 1938; 47:792-794.
- 3 Becker SS, Duncavage JA, Russell PT. Endoscopic endonasal repair of difficult to access cerebrospinal fluid leaks of the frontal sinus. *Am J Rhinol Allergy* 2009; 23:181-184.
- 4 Ma J, Huang Q, Li X, Huang D, Xian J, Cui S, Li Y, Zhou B. Endoscopic transnasal repair of cerebrospinal fluid leaks with and without an encephalocele in pediatric patients: from infants to children. *Childs Nerv Syst* 2015; 31:1493-1498.
- 5 Steven RA, Rothera MP, Tang V, Bruce IA. An unusual cause of nasal airway obstruction in a neonate: trans-sellar, trans-sphenoidal cephalocele. *J Laryngol Otol* 2011; 125:1075-1078.
- 6 Schlosser RJ, Woodworth BA, Wilensky EM, Grady MS, Bolger WE. Spontaneous cerebrospinal fluid leaks: a variant of benign intracranial hypertension. *Ann Otol Rhinol Laryngol* 2006; 115:495-500.
- 7 Chaaban MR, Illing E, Riley KO, Woodworth BA. Spontaneous cerebrospinal fluid leak repair: a five-year prospective evaluation. *Laryngoscope* 2014; 124:70-75.
- 8 Seth R, Rajasekaran K, Benninger MS, Batra PS. The utility of intrathecal fluorescein in cerebrospinal fluid leak repair. *Otolaryngol Head Neck Surg* 2010; 143:626-632.
- 9 Jones ME, Reino T, Gnoy A, Guillory S, Wackym P, Lawson W. Identification of intranasal cerebrospinal fluid leaks by topical application with fluorescein dye. *Am J Rhinol* 2000; 14:93-96.
- 10 Senior BA, Jafri K, Benninger M. Safety and efficacy of endoscopic repair of CSF leaks and encephaloceles: a survey of the members of the American Rhinologic Society. *Am J Rhinol* 2001; 15:21-25.
- 11 Keerl R, Weber RK, Draf W, Wienke A, Schaefer SD. Use of sodium fluorescein solution for detection of cerebrospinal fluid fistulas: an analysis of 420 administrations and reported complications in Europe and the United States. *Laryngoscope*. 2004;114:266-272.
- 12 Felisati G, Bianchi A, Lozza P, Portaleone S. Italian multicentre study on intrathecal fluorescein for craniocervical fistulae. *Acta Otorhinolaryngol Ital* 2008; 28:159-163.
- 13 Schlosser RJ, Bolger WE. Nasal cerebrospinal fluid leaks: critical review and surgical considerations. *Laryngoscope* 2004; 114:255-265.
- 14 Saafan ME, Ragab SM, Albirmawy OA. Topical intranasal fluorescein: the missing partner in algorithms of cerebrospinal fluid fistula detection. *Laryngoscope* 2006; 116:1158-1161.
- 15 Hegazy HM, Carrau RL, Snyderman CH, Kassam A, Zweig J. Transnasal Endoscopic Repair of Cerebrospinal Fluid Rhinorrhea: A Meta-Analysis. *The Laryngoscope*, 2000; 110: 1166-1172.
- 16 Schlosser RJ, Wilensky EM, Grady MS, Palmer JN, Kennedy DW, Bolger WE. Cerebrospinal fluid pressure monitoring after repair of cerebrospinal fluid leaks. *Otolaryngol Head Neck Surg*. 2004;130:443-448.
- 17 El Fiky L, Kotb A, Mostafa B. A unified management for spontaneous CSF leak. *Int J Otolaryngol Head Neck Surg* 2015; 4:141-147.
- 18 Ibrahim AA, Magdy EA, Eid M. Endoscopic endonasal multilayer repair of traumatic ethmoidal roof cerebrospinal fluid rhinorrhea in children. *Int J Pediatr Otorhinolaryngol* 2012; 76:523-529.