

# Role of Preoperative Computed Tomography in proper selection of surgical modality for nasal obstruction caused by the inferior turbinate

Khaled A, Said A. H., Reda R, Fawaz M, Hassan S

Otorhinolaryngology, Faculty of Medicine, Beni-Suef University

Correspondence to Hassan S  
Otorhinolaryngology, Faculty of Medicine, Beni-Suef University

E-mail: sara\_nesma@yahoo.com  
Tel: 01003324773

**Pan Arab Journal of Rhinology**  
2019, 10:28-34

**Background:** Computed tomography (CT) is used to assess the anatomical configuration of inferior nasal turbinate (IT).

**Patients and Methods:** The study was conducted between 2016 and 2018 on 30 patients (60 nasal sides) with bilateral moderate or severe nasal obstruction (due to IT hypertrophy and/or abnormal shape) as study group and 15 normal individuals (30 nasal sides) as control group. Based on preoperative CT findings of study group the cause of obstruction was identified as follow; 39 sides showed medial mucosal hypertrophy all through and underwent shaving using microdebrider, 15 sides showed all through medial mucosal hypertrophy + abnormal curvature and underwent shaving + outfracture, 3 sides showed hypertrophy at 1 or 2 sites + abnormal curvature and underwent selective submucosal diathermy + out fracture, and 3 sides showed medial mucosal hypertrophy at 1 or 2 sites and underwent selective submucosal diathermy only. Assessment of nasal obstruction was done by using visual analogue scale (VAS) and CT pre and postoperatively.

**Results:** Improvement of nasal obstruction occurred in all patients with variable degrees according to postoperative CT and VAS score.

**Conclusion:** Preoperative CT scan can precisely detect the main site (s) of nasal obstruction caused by IT hypertrophy (either mucosa or bone or both) and/or abnormal curvature. Accordingly the proper surgical technique is selected to deal with the site (s) of hypertrophy without the drawbacks of over surgery.

**Keywords:** Computed tomography; inferior turbinate; surgery: hypertrophied inferior turbinate.

Pan Arab Journal of Rhinology 2019, 10:28-34

## Introduction

Inferior turbinate hypertrophy (ITH) is one of the most common causes of nasal obstruction. Nasal obstruction has bad consequences on patient's general condition. ITH is commonly attributed to nasal allergy. [1-2]

Reduction of the size of IT is the main line of treatment. Different surgical modalities have been used to achieve sufficient nasal airflow. The surgical modalities include; partial inferior turbinectomy, submucous diathermy, radiofrequency ablation, cryotherapy, sub mucosal electrocautery, and laser-assisted or ultrasound reduction. Each of these modalities has its benefits and drawbacks. Selection of the proper surgical technique is mandatory to obtain the best results. [3-4]

Inferior turbinate hypertrophy is diagnosed by history, nasal endoscopy and (CT). The role of CT is crucial in diagnosis. Nasal obstruction due to ITH may be caused by mucosa or bone hypertrophy or abnormal shape. CT helps in selection of the proper surgical technique depending on what is the main cause of nasal obstruction. [5-6]

The aim of this work is to study the role of CT to identify the type of ITH (mucosal hypertrophy, osseous hypertrophy and/or abnormal shape) and to locate the site of maximum obstruction (anterior middle or posterior hypertrophy). So it can guide the surgeon to select the proper surgical intervention.

## Materials and Methods

The study was conducted at otorhinolaryngology and

radiology departments, Beni-Suef University Hospital after approval of the Internal Ethical Committee, between July 2016 and November 2018. The study included 30 patients (60 nasal sides) and 15 individuals (30 nasal sides) without any nasal symptoms as control group. The aim of inclusion of the control group (normal individuals) in the study was to obtain a cut off values which were considered an average for normal; medial mucosal thickness, bony thickness, distance from bony inferior turbinate to nasal septum and distance from bony inferior turbinate to lateral nasal wall. A written informed consent was obtained from patients prior to surgery. All patients were subjected to history taking, endoscopic nasal examination and CT scan of nose and paranasal sinuses. The study group included patients complaining of bilateral HIT. Visual Analogue Scale (VAS) [7] was used to assess severity of nasal obstruction pre-operatively and the degree of post-operative improvement;

- (0) no obstruction.
- (1-3) mild obstruction.
- (4-7) moderate obstruction.
- (8-10) severe obstruction.

## Inclusion criteria included

- Patients with moderate nasal obstruction (VAS 4-7).
- Patients with severe nasal obstruction (VAS 8-10).
- Age more than 15 years old.
- Patients with failed medical treatment.

## Exclusion criteria included

- Patients with bilateral nasal obstruction due to other pathologies e.g. sinonasal polypsis or deviated nasal

septum etc.

- Patients with mild nasal obstruction (VAS1-3).
- Patients with previous turbinate or nasal surgery.
- Age less than 15 years old.
- Patients with coagulopathy, diabetes, cardiovascular or renal diseases.

The receiver operating characteristic (ROC) curve was used to measure a cut off values (from CT findings of both study and control groups) which were considered an average for normal; medial mucosal thickness, bony thickness, distance from bony inferior turbinate to nasal septum and distance from bony inferior turbinate to lateral nasal wall (**Table 1**).

According to CT and ROC curve results, Patients with medial mucosal thickness above normal cut off values (**Table 1**) were selected for turbinoplasty using microdebrider (if all mucosa hypertrophied) or selective sub mucosal diathermy respectively (at site of hypertrophy only). While those with abnormal IT curvature underwent out fracture (if ratio between medial distance from bony inferior turbinate to nasal septum and lateral distance from bony inferior turbinate to lateral bony nasal wall was less than ratio between their normal cut-off values anterior (2.05), Middle (2.75) or posterior (2.87). According to CT findings and ROC curve results, the type of surgical technique was designed separately. Based on preoperative CT of the study group (60 nasal sides); it was sectioned into: 39 sides with medial mucosal hypertrophy all through underwent shaving using microdebrider, 15 sides with all through medial mucosal hypertrophy and abnormal

IT curvature underwent shaving + outfracture, 3 sides with hypertrophy at 1 or 2 sites + abnormal IT curvature underwent selective submucosal diathermy + out fracture and 3 sides with medial mucosal hypertrophy at 1 or 2 sites underwent selective submucosal diathermy.

Nasal pack was inserted at the end of surgery and removed 48 hrs after surgery. All patients received I.V antibiotic and analgesic during the first 48 hours. Patients were discharged 2 days after surgery.

Patients were informed to continue on medications in the form of oral antibiotic and analgesic for one week, alkaline nasal wash and steroid nasal spray for one month.

All patients were followed up in our outpatient clinic; weekly during the first month then every month till the end of the follow up period (minimum 6 months). Evaluation included CT scan and VAS score that were done one year postoperative.

### Statistics

Analyses of the data were performed using Statistical Package for the Social Sciences SPSS for Mac, version 23. Data are expressed as the mean values (with standard deviations [SDs]), and all statistical tests are 2-tailed. Nonparametric tests were applied to the data. Comparisons between pre- and post-operative measurements were done by Paired Sample T Test. Values of p \_ less than 0.05 were considered to indicate statistical significance.

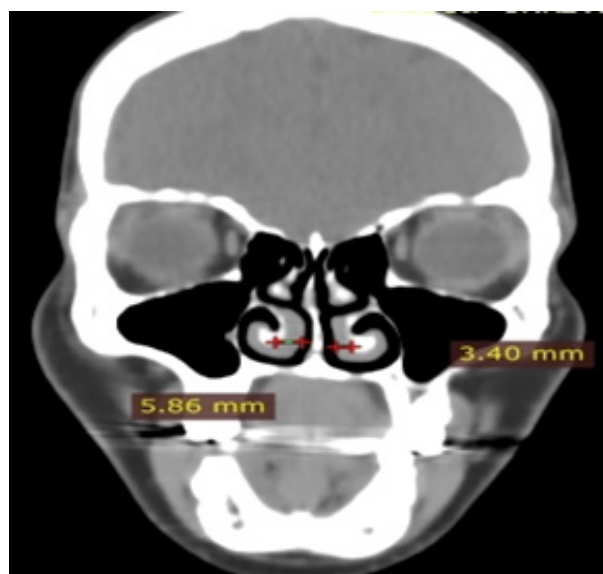**Table 1: Normal cut-off values according to ROC curve results**

| Cut-off value in mm | Medial mucosa thickness | Bony thickness | Medial distance | Lateral distance |
|---------------------|-------------------------|----------------|-----------------|------------------|
| <b>Anterior</b>     | 2.02                    | -              | 6.51            | 3.51             |
| <b>Middle</b>       | 2.50                    | -              | 5.07            | 4.01             |
| <b>Posterior</b>    | 2.50                    | -              | 6.28            | 4.02             |

### Results

The study included 30 participants (60 nasal sides); 13 males and 17 female. The mean age of patients was (30.75 ± 9.50).

According to CT findings, all 60 sides were sectioned into; 39 sides (65%) with all through medial mucosal hypertrophy underwent shaving using microdebrider (**Figs. 1,2**). 15 sides (25%) with all through medial mucosal hypertrophy and abnormal IT curvature underwent shaving using microdebrider + out fracture (**Figs. 3,4**). 3 sides (5%) with medial mucosal hypertrophy at 1 or 2 sites + abnormal IT curvature underwent selective submucosal diathermy + out fracture (**Figs. 5,6**). 3 sides (5%) underwent selective submucosal diathermy only at the site of medial mucosal hypertrophy (**Figs. 7,8**).



**Fig 1: All through medial mucosal hypertrophy (preoperative).**

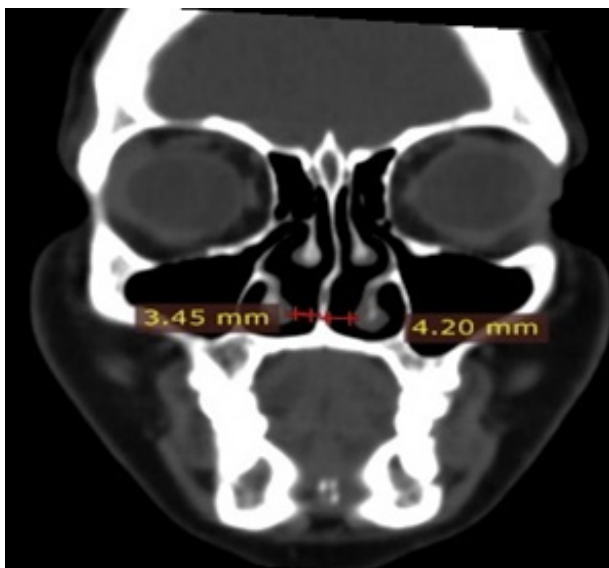

Fig 2: Postoperative diameter after shaving using microdebrider.

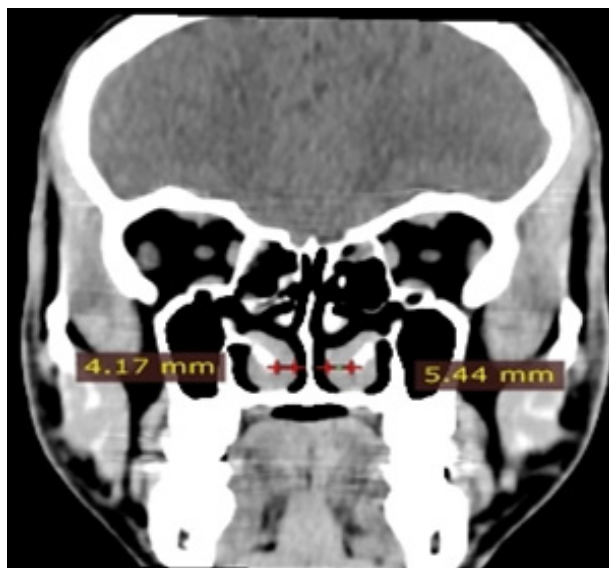


Fig 5: Medial mucosal hypertrophy + abnormal IT curvature (preoperative).

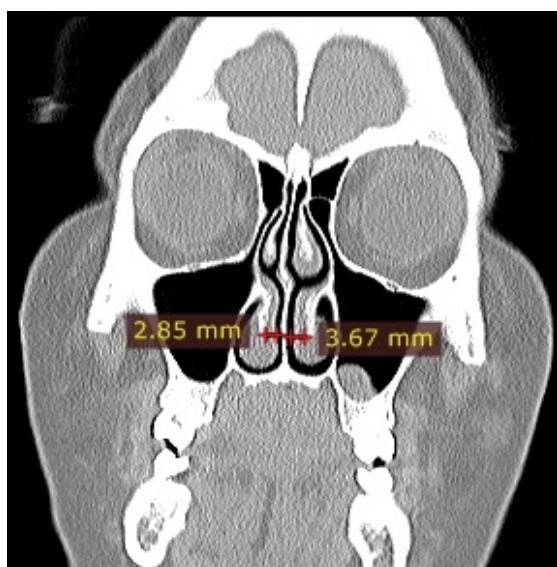


Fig 3: All through medial mucosal hypertrophy and abnormal IT curvature (preoperative).

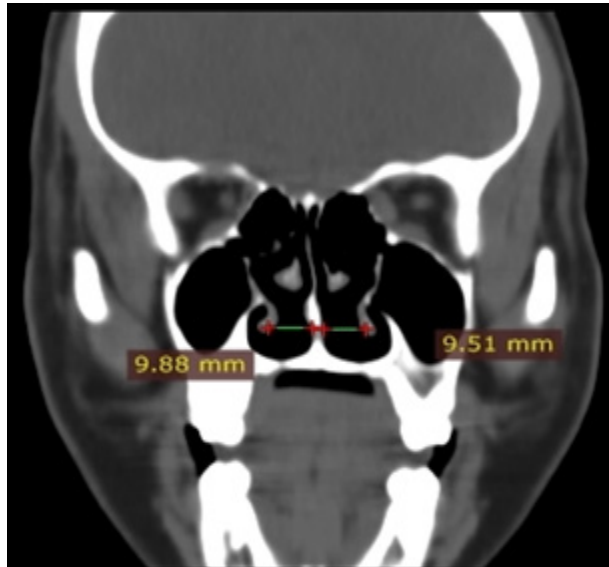


Fig 6: Postoperative after selective submucous diathermy + out fracture.

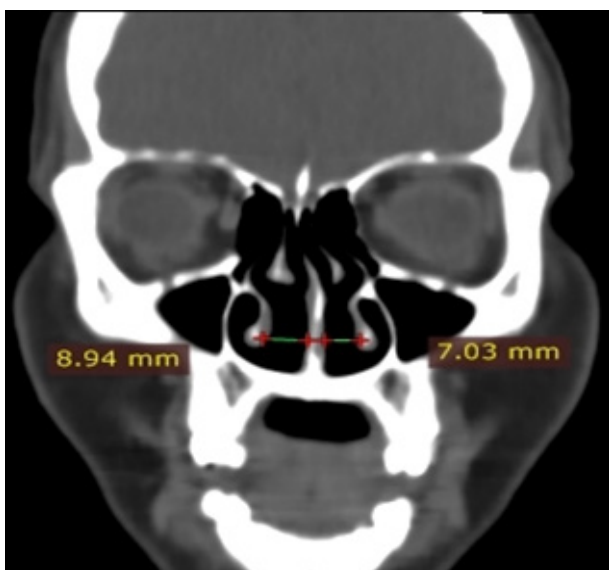


Fig 4: Postoperative improvement after shaving using microdebrider + out fracture.

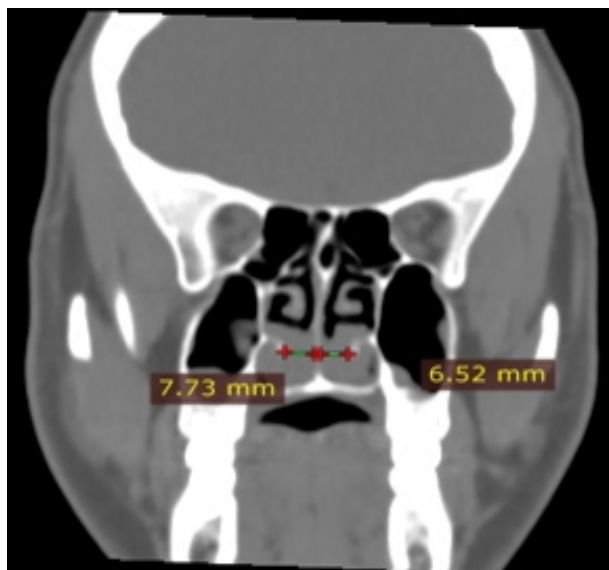
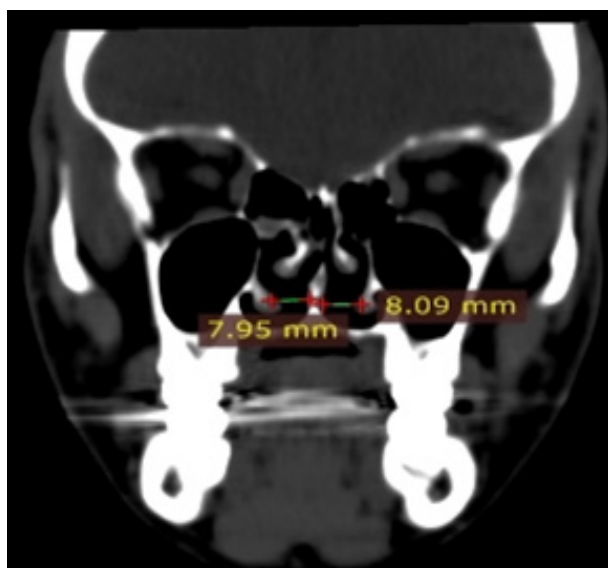


Fig 7: Medial mucosal hypertrophy (preoperative).



**Fig 8: Postoperative after selective submucosal diathermy.**

Improvement of nasal obstruction of study group was evidenced by using VAS score (**Table 2**) and postoperative CT (**Tables 3,4**).

Regarding complications, unilateral nasal adhesions occurred in 2 patients who underwent microdebrider shaving of medial mucosa at anterior one third of IT and nasal septum one month postoperatively. Release of adhesions was done in our outpatient clinic using turbinate scissor with insertion of nasal pack for 2 days. Both patients showed no recurrence of adhesions during follow up period.

**Table 2: Comparison of VAS scores pre and post-operative**

| Type of surgery according to computed tomography data                          | VAS scores preoperative  | VAS scores postoperative | P - value |
|--|--------------------------|--------------------------|-----------|
|  | Mean± SD (Min-max) in mm | Mean± SD (Min-max) in mm |           |
| All medial mucosa shaving only<br>n= 39 sides (65%)                            | 9.17±1.022<br>(7-10)     | 0.076±0.269<br>(0-1)     | 0.045     |
| Out fracture+all medial mucosa shaving<br>n= 15 sides (25%)                    | 8.86±0.911<br>(8-10)     | 0.2±0.414<br>(0-1)       | 0.015     |
| Outfracture+ selective submucosal diathermy of medial mucosa<br>n=3 sides (5%) | 8.66±0.577<br>(8-9)      | 0.66±0.577<br>(0-1)      | 0.041     |
| Selective submucosal diathermy of medial mucosa<br>n=3 sides (5%)              | 9.00±0.636<br>(5-9)      | 1.333±1.527<br>(0-1)     | 0.047     |

**Table 3: Comparison between Pre and Post-Operative medial Mucosal Thickness of study group**

| Parameters                              | Mean ±SD            | (Minimum-Maximum in mm) | P-value     |
|---|---------------------|-------------------------|-------------|
| Preoperative Medial Mucosa (Anterior)   | 3.8368<br>±1.34124  | (1.45-6.58)             | <b>0.00</b> |
| Postoperative Medial Mucosa (Anterior)  | 1.7303<br>±0.82790  | (0.5-1.59)              |             |
| Preoperative Medial Mucosa (Middle)     | 4.2153<br>±1.34560  | (2.04-9.00)             | <b>0.00</b> |
| Postoperative Medial Mucosa (Middle)    | 0.1855<br>± 0.73125 | (0.00-3.92)             |             |
| Preoperative Medial Mucosa (Posterior)  | 4.8180<br>±1.43596  | (1.55-8.00)             | <b>0.00</b> |
| Postoperative Medial Mucosa (Posterior) | 0.1983<br>±0.78394  | (0.00-4.02)             |             |

**Table 4: Comparison between Pre and Post-Operative medial Distance from bony inferior turbinate to nasal septum of 18 (30%) ITS with abnormal curvature**

|                  | Mean<br>±SD                         | (Minimum- Maximum in mm) | P-value       |
|------------------|-------------------------------------|--------------------------|---------------|
| <b>Anterior</b>  | Preoperative distance; N=60 sides   | 2.4030<br>±1.21237       | (0.00-6.12)   |
|                  | Postoperative distance; N=60 sides  | 4.5768<br>±1.10315       | (2.30 -7.76)  |
| <b>Middle</b>    | Preoperative distance; N=60 sides   | 2.2492<br>±1.13824       | (0.00 -5.03)  |
|                  | Postoperative distance; N= 60 sides | 6.0655<br>±1.73537       | (2.88 -10.57) |
| <b>Posterior</b> | Preoperative distance; N=60 sides   | 1.9662<br>±1.39613       | (0.00-5.61)   |
|                  | Postoperative distance; N= 60 sides | 6.8577<br>±1.80396       | (2.80 -10.51) |

## Discussion

Nasal obstruction is a disabling condition for many patients. Hypertrophy of IT caused by allergic rhinitis is found to be the most frequent cause of nasal obstruction. [8]

Different surgical techniques can treat nasal obstruction caused by HIT. These include total or partial turbinectomy, turbinoplasty, electrocautery, cryosurgery; laser cautery, sub mucosal resection, and sub mucosal resection with outfracture. Each surgical modality has its benefits and drawbacks. None of them has been proved to be the most effective treatment which deals with IT as one unit, as most of reduction techniques aim to decrease the size of IT irrespective of site of hypertrophy. [9]

CT is a noninvasive technique that can help to assess the anatomical configuration of IT and can help in deciding the type of turbinate surgery depending upon the type and site of hypertrophy (anterior, middle or posterior 1/3). CT is used also to detect whether HIT is due to mucosal hypertrophy, bone hypertrophy and/or abnormal shape. [10,11]

Akoglu et al., [13] documented a significant bony and mucosal enlargement in the anterior and middle segments of the inferior turbinate in 72 (100%) patients with septal deviation and compensatory hypertrophy of the IT by the use of CT, compared to the control group (14 patients). They recommended performing bony and mucosal reduction in the anterior and middle two thirds of IT to maximize the nasal airway. So CT is considered a useful tool in diagnosing ITH and helps in selection of type of surgery. These results are consistent with our results.

Similar results was obtained by Mrig et al., [5] who studied the role of preoperative CT in evaluation of compensatory IT hypertrophy and in deciding surgical treatment modality in patients with deviated nasal Septum. They concluded that CT can assess the anatomical composition of IT and helps in

deciding the type of turbinoplasty depending upon the type of hypertrophy. Also this was consistent with our results.

According to CT findings; 60 nasal sides were sectioned into; 39 sides with all through medial mucosal hypertrophy underwent shaving using microdebrider (**Figs. 1, 2**). 15 sides with all through medial mucosal hypertrophy and abnormal IT curvature underwent shaving using microdebrider + out fracture (**Figs. 3,4**). 3 sides with hypertrophy at 1 or 2 sites + abnormal IT curvature underwent selective submucosal diathermy at the sites of medial mucosal hypertrophy + out fracture [fig 5, 6]. 3 sides underwent selective submucosal diathermy only at the site of hypertrophy of the IT medial mucosa (**Figs. 7,8**). All showed significant improvement of nasal obstruction with postoperative VAS 0-1 (**Table 2**).

In this work; abnormal IT curvature also had been observed together with hypertrophy of medial mucosa in 18 (30%) ITS. Postoperative CT results (**Table 4**) showed successful displacement of bony IT in above 18 (30%) ITS. So out fracture can be used as an ancillary procedure to improve nasal patency. This result was compatible with the results of Passali et al., [3] [who stated that lateral displacement and submucosal resection of the IT improved the long-term results when compared with submucosal resection alone. Nassiffi et al., [14] compared the effects of submucosal cauterization of the inferior turbinate with or without outfracture and reported that outfracture was an effective and safer technique.

No bony hypertrophy was reported in our cases and so we couldn't obtain a cut off value of its normal thickness, and couldn't signify its role in bilateral inferior turbinate hypertrophy or its contribution to nasal obstruction. This was consistent with results of Israfil et al., [15] who reported that bone hypertrophy is less important than medial mucosa in patients with compensatory hypertrophy of IT with nasal septum deviation.

Eric and Eugene et al., [12] reported secondary atrophic rhinitis in 197 (81.4%) patients of study group (242 patients) after destructive nasal surgery, 110 patients had history of partial inferior turbinectomy and/or middle turbinectomy and 47 patients had total resection of inferior and middle turbinates.

One of the limitations of our study is the limited number of patients (30 patients) and the shorter follow up period (6 months up to 2 years) compared to other studies as a study by Passali et al., [3] which included 457 patients over a 6-year follow-up period. So a larger number of patients and longer follow up period is recommended for more accurate results.

### Conclusion

IT hypertrophy is a multifactorial disease. Many surgical techniques can be used according to the causative factor of hypertrophy. CT is a noninvasive technique that helps in assessing the site (s) of IT hypertrophy and abnormal curvature so helps in selection of proper type of turbinoplasty that can deal with that site (s) to avoid unnecessary invasive surgery.

### References

1. Perazzo, P., Martin, L. and Almeida, W. Infrared: Uma Nova Opção Terapêutica na Rinite. *Arc Int Otorrinolaringol.* 2004;8:261-267.
2. Korkut, A., Islim, F. and Gulsevenciftci, S.: Evaluation of inferior turbinate hypertrophy in patients with congenital and traumatic nasal septum deviation. *Journal of Laryngology and Otology.* 2012;126:784-8.
3. Passali, D.: Rhinosinonasal Inflammation and Infections in Modern Thinking and Current Treatment. In: Bellussi, L., Kern, E., chapter 2, volume 1, 3rd edition, *Academiei Romane (Bucharest).* 2013;101-167.
4. Bhandarkar, N. and Smith, T.: Outcomes of surgery for inferior turbinate hypertrophy. *Curr Opin Otolaryngol Head Neck Surg.* 2010;18:49-53.
5. Mrig, S. Agarwal, A. and Passey, J.: Preoperative computed tomographic evaluation of inferior turbinate hypertrophy and its role in deciding surgical treatment modality in patients with deviated nasal septum. *International Journal of Morphology.* 2009;27:503-506.
6. Egeli, E., Demirci, L., Yazycy, B. and Harputluoglu, U. (2004): Evaluation of the inferior turbinate in patients with deviated nasal septum by using computed tomography. *Laryngoscope.* 2004;114:113-117.
7. Sajad, A., Hasanain, F. and Ahmed, J.: Powered endoscopic inferior turbinoplasty: clinical study. *International Journal of Otorhinolaryngology and Head and Neck Surgery.* 2018;4:24-31.
8. Berger, G., Hammel, I., Berger, R., Avraham, S. and Ophir, D.: Histopathology of the inferior turbinate with compensatory hypertrophy in patients with deviated nasal septum. *Laryngoscope.* 2000;110:2100-2105.
9. Larrabee, Y. and Kacker, A.: Which Inferior Turbinate Reduction Technique Best Decreases Nasal Obstruction? *Laryngoscope.* 2014;124:814-815.
10. Ashok, K., Bhumika, G., Neha, G. and Nishikanata, T.: Computerized Tomography of Paranasal Sinuses: A Roadmap to Endoscopic Surgery. *International Journal of Clinical Rhinology.* 2012;5:1-10.
11. Mrig, S. Agarwal, A. and Passey, J.: Preoperative computed tomographic evaluation of inferior turbinate hypertrophy and its role in deciding surgical treatment modality in patients with deviated nasal septum. *International Journal of Morphology.* 2009;27:503-506.
12. Eric, J. and Eugene, B.: Atrophic Rhinitis: A Review of 242 Cases. *American Journal of Rhinology.* 2001;355-361.
13. Akoglu, E., Karazincir, S. and Balci, A.: Evaluation of the turbinate hypertrophy by computed tomography in patients with deviated nasal septum. *Otolaryngology Head and Neck Surgery.* 2002;136:380-384.
14. Nassif Filho, A., Ballin, C., Maeda, C., Nogueira, G., Moschetta, M. and De Campos, D.: Comparative study of the effects of submucosal cauterization of the inferior turbinate with or without outfracture. *Brazilian Journal of Otorhinolaryngology.* 2006;72:89-95.
15. Israfil, O., Salih, A., Tugrul, O. and Fahrettin, Y.: Radiological Analysis of Inferior Turbinate in Patients with Deviated Nasal Septum by Using Computed Tomography. *American Journal of Rhinology and Allergy.* 2014;28:68-72.