

Mometasone furoate aqueous nasal spray in management of adenoidal hypertrophy in children

Fahd Alharbi,^{1,2} Mohammed Rifaat Ahmed³

¹Department of Otorhinolaryngology-Head and Neck Surgery, Faculty of medicine, Jazan University, Jazan, Saudi Arabia, ²Department of Otorhinolaryngology-Head and Neck Surgery, Prince Mohammad bin Nasser, Jazan, Saudi Arabia, ³Department of Otolaryngology-Head & Neck Surgery, Faculty of Medicine, Suez University, Egypt

Corresponding address is to: Fahd Alharbi

E-mail: fahdalharbi3@gmail.com
Tel: 00966543043452

Pan Arab Journal of Rhinology
2018, 8:88-94

Background: Nasal obstruction is a frequently encountered problem in the pediatric age group obstructs the nasopharyngeal airway and Eustachian tube orifice resulting in a conductive hearing loss. Topical nasal corticosteroid spray reduced adenoid size and improved symptoms of nasal airway obstruction and obstructive sleep apnea.

Aim of the study: To evaluate the efficacy of Mometasone furoate aqueous nasal spray in management of adenoidal hypertrophy in children.

Methodology/Principal: A double randomized clinical trial was performed on 168 adenoid hypertrophy patients divided randomly into two equal groups: study group (received Mometasone furoate aqueous nasal spray for 6 weeks) and control group (received nasal normal saline drops for the same period).

Results: The study group patients show significant improvement in nasal obstruction from 60.7% to 27.4% after treatment, mouth breathing from 84.2% to 25%, snoring from 72.6% to 31% and nasal discharge from 64.2% to 22.6%.

Conclusion: Intranasal Mometasone furoate aqueous nasal spray may obtain some successful results in some cases of adenoid hypertrophy to improve nasal obstruction symptoms and may be associated with a reduction in adenoid size.

Keywords: Corticosteroids; Obstruction; Adenoid; Mometasone; Randomized controlled trial.

Pan Arab Journal of Rhinology 2018, 8:88-94

Introduction

Nasal obstruction is a frequently encountered problem in the pediatric age group associated with a variety of etiological factors mainly attributable to adenoid hypertrophy results from chronic and/or recurrent infection of the upper respiratory tract or allergies. [1,2] Adenoid hypertrophy obstructs the nasopharyngeal airway, particularly at night when the patient is supine. Classically, the symptoms and physical signs considered indicative of nasal airway obstruction in children are mouth breathing, nasal voice and nocturnal snoring. [3] Delayed diagnosis and treatment of these diseases may result in consequences such as behavior alterations, low growth and weight gain, craniofacial alterations secondary to mouth breathing, mastication and swallowing disorders, in addition to cor pulmonale and left heart failure. [4] In addition, enlarged adenoids may also obstruct the Eustachian tube orifice leading to middle ear effusion and resulting in a conductive hearing loss. [5]

The lateral neck radiograph remains a widely used diagnostic modality in some countries for diagnosing children with suspected adenoid hypertrophy. The low cost, widespread availability, non-invasive nature and good correlation with symptoms and fiberoptic nasopharyngeal endoscopic findings are the main advantages of this diagnostic test. [6] Adenoidectomy can reduce both nasal obstructions and upper respiratory infections. However, some patients display clinically significantly persistent nasal symptoms even after surgery. Symptoms, such as nasal obstruction or recurrent upper respiratory infections, persist in 19–26% of patients. [7] There are two difficulties that have been described to prevent complete adenoid removal. Firstly, lymphoid tissue in the pharyngeal recess is considered by all authors as difficult to remove, [8] the second difficulty is the bulging adenoid

tissue into the posterior choanae, which was addressed by Pearl and Manoukian as they found choanal adenoids in 9% of their study group. [9]

As adjunctive treatments, medical methods for reduction of adenoid size are limited. However, recent studies showed that topical nasal corticosteroid spray reduced adenoid size and improved symptoms of nasal airway obstruction and obstructive sleep apnea. [10] Therefore, we found it is important to assess the efficacy of Mometasone furoate aqueous nasal spray in management of adenoidal hypertrophy in children.

Materials and Methods

Design, setting and participants

A double randomized clinical trial was performed in the Department of Otolaryngology-Head and Neck Surgery, Jazan University between June 2015 and March 2016. The study protocol was approved by the local ethical committee and written informed consent was obtained from all patients.

Patient eligibility and enrolment

Patients of both sexes aged (5-12 years old) and attending the ENT outpatient clinic and with adenoid hypertrophy were included in the study.

Patients were excluded if they had nasal masses, hypersensitivity to Mometasone furoate aqueous nasal spray, craniofacial abnormality or congenital anomalies.

Study plan

Assessment of each child upon entering the study included the following: history and physical examination, parental questionnaire, lateral nasopharyngeal radiograph.

The lateral view X-ray of the nasopharynx, the size of the adenoids was graded according to the palatal airway measured from the most convex point of the adenoid tissue to the soft palate, the narrowest distance between the narrowest distance between the nasopharyngeal soft tissue and the soft palate was taken. Grading was as follows, Grade 1: >6 mm; Grade 2: 4–6 mm; Grade 3: 0–3 mm. [11]

All patients included in the study had complete head and neck examination, including rigid fiberoptic nasal endoscopy. Topical anaesthesia in the form of a mixture of lidocaine/phenylephrine was applied prior to endoscopic examination. Patients were asked to maintain a supine position without restraint during the examination; but in some patients it was necessary to immobilize the head.

Patients were graded as follow grade 1 <50% of choanal space was occupied by the adenoid tissue, grade 2 50–75% grade 3 >75% choanal obstruction. [12] Tympanometry performed for patients diagnosed clinically with otitis media with effusion.

Randomization

Patients with adenoid hypertrophy were divided randomly into two equal groups: study group (received Mometasone furoate aqueous nasal spray 100 mcg/day for 6 weeks) and control group (received nasal normal saline drops for same period) All patients included in the study were assessed by history and physical examination, parental questionnaire, lateral nasopharyngeal radiograph, rigid fiberoptic nasal endoscopy and tympanometry.

Objective and outcome measurement assessment

The objective was to verify clinically the improvement subjectively using another questionnaire after 6 weeks from initiation the treatment in both groups and objectively by performing another lateral nasopharynx X-ray view of all participants in the study and rigid fiberoptic nasal endoscopy to compare the finding before and after the treatment.

Data collection, allocation concealment and blinding

At study enrolment (day 0), each parent's participant underwent a brief interview with the physician to complete a questionnaire, and provide demographic and disease-related information. The outcomes were assessed by another interview, which was conducted at the end of treatment.

Statistical analysis

Data collected were processed using SPSS version 22 (SPSS Inc., Chicago, IL, USA).

Ethical considerations

Written informed consent was obtained from all parent's patients. The local ethical committee approved the study.

Results

168 adenoid hypertrophy patients with the previous inclusion criteria (mean age 6.3 years, 74 females and 94 males) attended to outpatient clinic in Suez Canal university hospital included to our study. All patients' relatives were required to complete a questionnaire assessing their nasal symptoms, pre-treatment and 6 weeks after treatment.

Patients were randomly divided into 2 groups: Study group (n=84), 35 females and 49 males received Mometasone furoate aqueous nasal spray 100 mcg/day for 6 weeks and control group (n=84), 39 females and 45 males received sodium chloride 7.4mg/ml nasal drops for the same period.

The main symptom among the study group patients was nasal obstruction either alone in 51 patients (60.7%) or in

combination with other symptoms in 79 patients (94%). the second most common symptom was mouth breathing in 71 patients (84.2%), snoring in 61 patients (72.6%), nasal discharge in 54 patients (64.2%), Hearing loss was presenting the symptom in 9 patients (10.7%), persistent cough in 5 patients (5.9%) and Nocturnal enuresis in 3 patients (3.5%) - **(Table 1)**.

On the other hand, the distribution of signs in order of frequency was adenoid facies in 34 patients (40.5%), postnasal discharge in 28 patients (33.3%), tympanic membrane retraction in 14 patients (16.7%), and hypertrophied inferior turbinate in 8 patients (9.5%) - **(Table 2)**. In lateral nasopharynx X-ray view, we find that 64 patients (76.2%) were in grade 2, 13 patients (15.5%) were in grade 3 while 7 patients (8.3%) were in grade 1 - **(Table 3)**. In endoscopic examination of the nasopharynx, we find that 49 patients (58.3 %) were in grade 2, 26 patients (31%) were in grade 1 while 9 patients (10.7%) were in grade 3. **(Table 4)**.

After 6 weeks from Mometasone furoate aqueous nasal spray administration, nasal obstruction found in 23 patients (27.4%) mouth breathing in 21 patients (25%), snoring in 26 patients (31%), nasal discharge in 19 patients (22.6 %), no documentations for hearing loss, cough and nocturnal enuresis - **(Table 5)**. Follow-up by lateral nasopharynx X-ray view showed that 55 patients (65.5%) were in grade 3, 25 patients (29.8 %) were in grade 2 while 4 patients (4.7%) were in grade 1 - **(Table 6)**.

Follow-up by endoscopic examination of the nasopharynx revealed 59 patients (70.3 %) were in grade 1, 21 patients (25%) were in grade 2, while 4 patients (4.7%) were in grade 3 - **(Table 7)**.

The main symptom among the control group patients was nasal obstruction either alone in 49 patients (58.3%) or in combination with other symptoms in 77 patients (91.7%). the second most common was mouth breathing in 68 patients (80.9%), snoring in 63 patients (75%), nasal discharge in 51 patients (60.7%), Hearing loss was presenting symptom in 11 patients (13.1%), persistent cough in 3 patients (3.5%) and nocturnal enuresis in 3 patients (3.5%) - **(Table 1)**. The signs were adenoid facies in 36 patients (42.8%), postnasal discharge in 26 patients (31%), tympanic membrane retraction in 15 patients (17.8%), and hypertrophied inferior turbinate in 10 patients (11.9%) - **(Table 2)**.

The degree of adenoid enlargement according to lateral nasopharynx X-ray view: 60 patients (71.5%) were in grade 2, 14 patients (16.6%) were in grade 3 while 10 patients (11.9%) were in grade 1 - **(Table 3)**. Endoscopic examination revealed that 51 patients (60.7 %) were in grade 2 adenoid enlargement, 23 patients (27.4%) were in grade 1 while 10 patients (11.9%) were in grade 3 - **(Table 4)**.

After 6 weeks from placebo administration in form of sodium chloride 7.4mg/ml nasal drops, nasal obstruction found in 47 patients (55.9%) mouth breathing in 63 patients (75%), snoring in 59 patients (70.2 %), nasal discharge in 50 patients (59.5 %), hearing loss was presenting symptom in 9 patients (10.7%), persistent cough in 3 patients (3.5%) and Nocturnal enuresis in 3 patients (3.5%). **(Table 5)**.

Follow up lateral nasopharynx X-ray view showed that 60 patients (71.5%) were in grade 2, 14 patients (16.6%) were in grade 3 while 10 patients (11.9%) were in grade 1 - **(Table 6)**. Endoscopic examination of the nasopharynx revealed that 51 patients (60.7 %) were in grade 2 adenoid enlargement, 23 patients (27.4%) were in grade 1 while 10

patients (11.9%) were in grade 3 -(Table 7).

From point of view for the previous results we could realized that the study group who subjected to Mometasone furoate aqueous nasal spray administration for 6 weeks revealed a

statistically significant improvement subjectively in the nasal symptoms compared with the control group who received sodium chloride 7.4mg/ml nasal drops for same period and objectively statistically significant improvement in both radiological and endoscopic evaluation follow up (Figs. 1-3).

Table 1 Adenoid enlargement symptoms in both groups

Symptoms	Study group		Control group		t-test	P value
	N (84)	%	N (84)	%		
Nasal obstruction+ other symptoms	79	94%	77	91.7%	0.55	0.754
Mouth breathing	71	84.2%	68	80.9%	0.78	0.639
Snoring in patients	61	72.6%	63	75%	0.18	0.581
Nasal discharge	54	64.2%	51	60.7%	0.35	0.709
Hearing loss	9	10.7%	11	13.1%	0.76	0.764
Persistent cough	5	5.9%	3	3.5%	0.43	0.617
Nocturnal enuresis	3	3.5%	3	3.5%	0.19	0.516

Insignificant P value>0.05.

Table 2 Adenoid enlargement signs in both groups

Signs	Study group		Control group		t-test	P value
	N (84)	%	N (84)	%		
Adenoid facies	34	40.5%	36	42.8%	0.9	0.943
Postnasal discharge	28	33.3	26	31%	0.7	0.759
Tympanic membrane retraction	14	16.7%	15	17.8%	0.9	0.843
Hypertrophied inferior turbinate	8	9.5%	10	11.9%	0.9	0.843

Insignificant P value>0.05.

Table 3 X ray adenoid enlargement size in both groups

X ray adenoid size	Study group		Control group		t-test	P value
	N (84)	%	N (84)	%		
Grade 1	7	8.3%	10	11.9%	0.18	0.581
Grade 2	64	76.2%	60	71.5%	0.34	0.607
Grade 3	13	15.5%	14	16.6%	0.27	0.529

Insignificant P value>0.05

Table 4 Endoscopic adenoid enlargement size in both groups

Endoscopic adenoid size	Study group		Control group		t-test	P value
	N (84)	%	N (84)	%		
Grade 1	26	31%	23	27.4%	0.49	0.542
Grade 2	49	58.3 %	51	60.7 %	0.41	0.559
Grade 3	9	10.7%	10	11.9%	0.33	0.611

Insignificant P value>0.05

Table 5 Nasal symptoms after 6 weeks from treatment

Symptoms	Study group		Control group		t-test	P value
	N (84)	%	N (84)	%		
nasal obstruction	23	27.4%	47	55.9%	2.47	0.023*
mouth breathing	21	25%	63	75%	2.52	0.019*
snoring in patients	26	31%	59	70.2 %	2.08	0.05*
Nasal discharge	19	22.6 %	50	59.5 %	2.38	0.028*
Hearing loss	0	0	9	10.7%	7.03	0.008*
persistent cough	0	0	3	3.5%	2.08	0.05*
Nocturnal enuresis	0	0	3	3.5%	2.08	0.05*

*Significant p <0.05.

Table 6 X ray adenoid enlargement size after 6 weeks from treatment

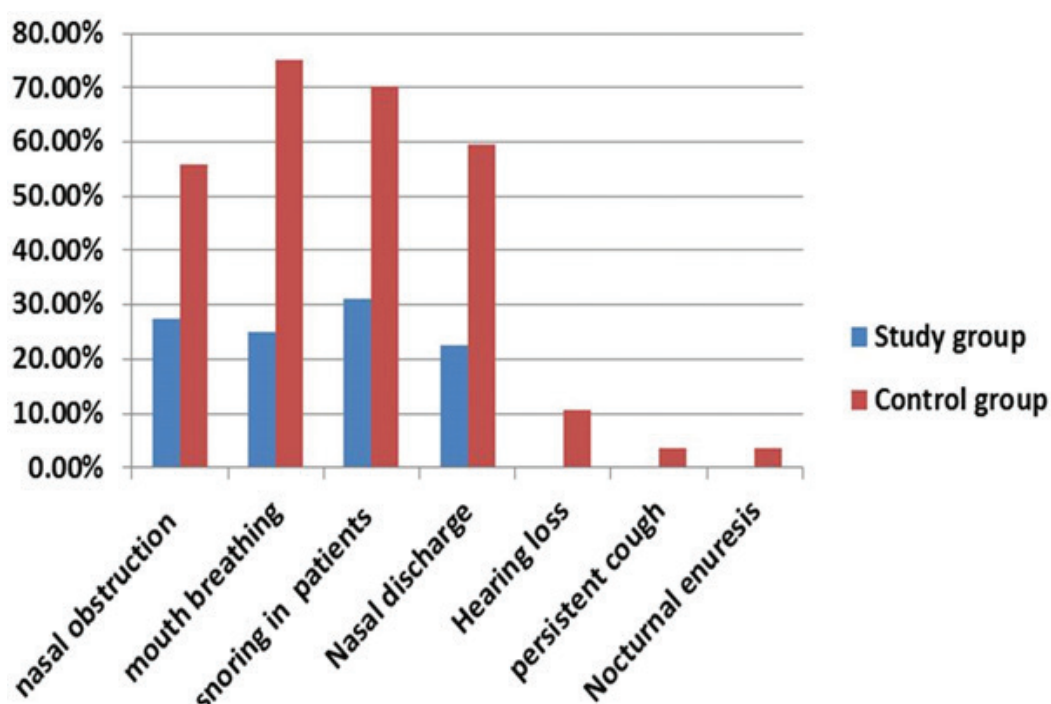
X ray adenoid size	Study group		Control group		t-test	P value
	N (84)	%	N (84)	%		
Grade 1	4	4.7%	10	11.9%	2.37	0.02*
Grade 2	25	29.8 %	60	71.5%	2.11	0.04*
Grade 3	55	65.5%	14	16.6%	2.76	0.03*

*Significant p <0.05.

Table 7 Endoscopic adenoid enlargement size after 6 weeks from treatment

Endoscopic evaluation adenoid size	Study group		Control group		t-test	P value
	N (84)	%	N (84)	%		
Grade 1	59	70.3 %	23	27.4%	2.09	0.045*
Grade 2	21	25%	51	60.7 %	2.14	0.029*
Grade 3	4	4.7%	10	11.9%	2.44	0.041*

*Significant p <0.05.

**Fig 1. Nasal symptoms after 6 weeks from treatment**

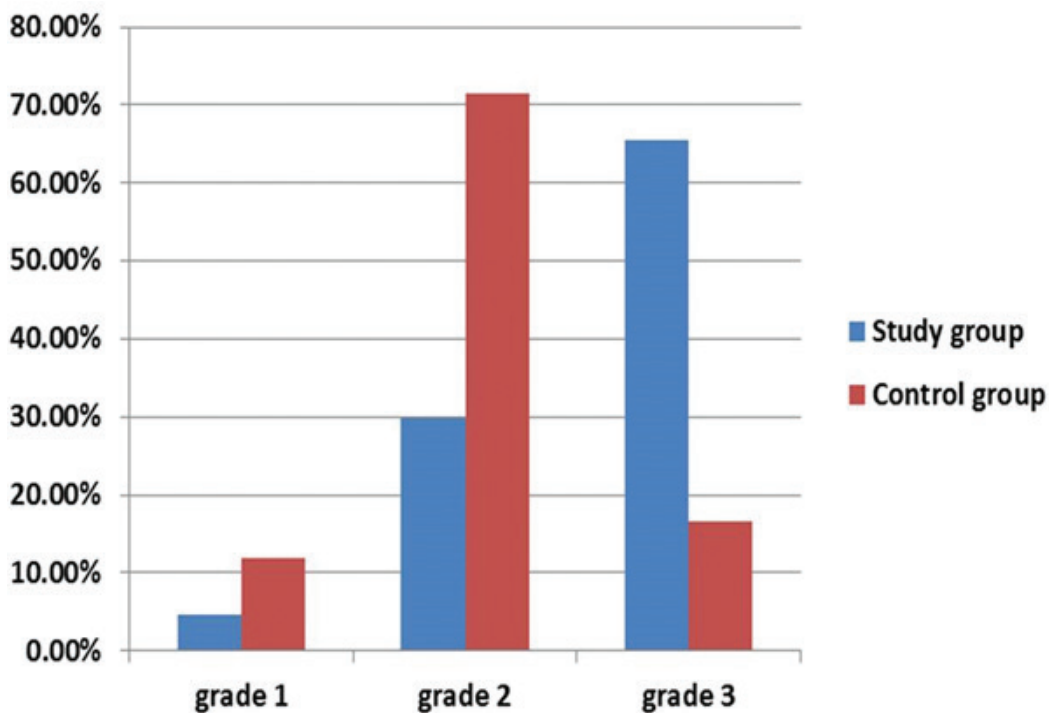


Fig 2. X ray adenoid enlargement size after 6 weeks from treatment

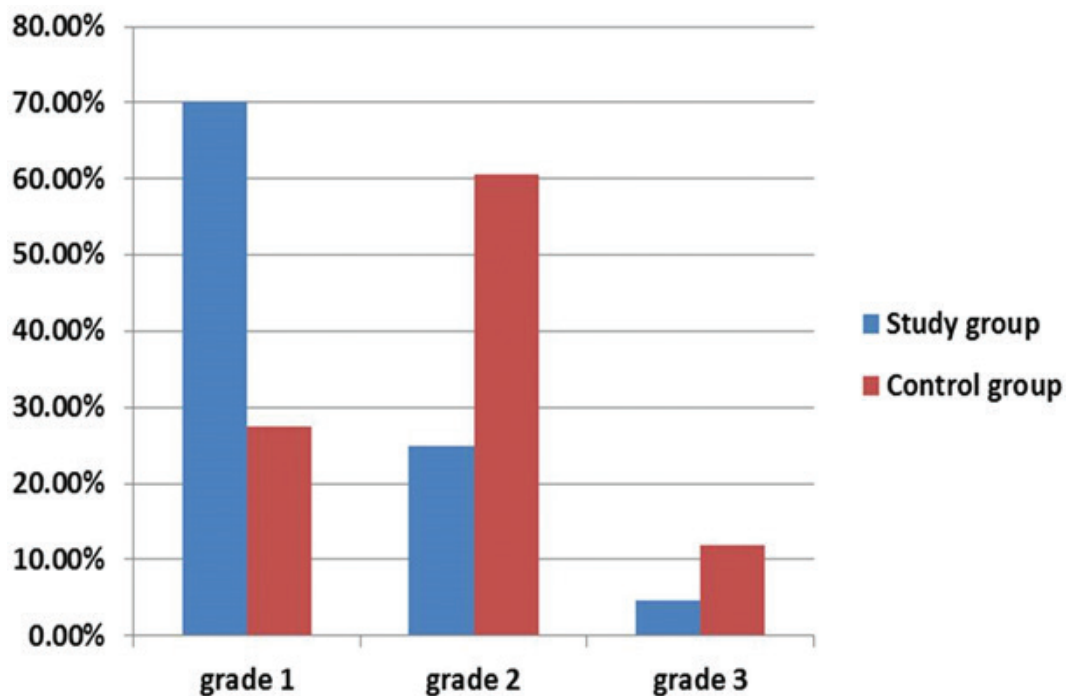


Fig 3. Endoscopic adenoid enlargement size after 6 weeks from treatment

Discussion

Adenoid hypertrophy has major impact in airway as a common cause of upper-airway obstruction in children and in severe cases may result in cor pulmonale, pulmonary vascular hypertension, alveolar hypoventilation, excessive snoring, and symptoms of chronic sinusitis with enlarged adenoid pads blocking the choana. [13] Chronic mouth-breathing secondary to adenoid hypertrophy and upper-airway obstruction has been shown to affect craniofacial growth patterns in children with features of adenoid facies. [14] Relation between adenoid hypertrophy and recurrent middle ear effusion with hearing impairment has been established. [15]

Lateral nasopharynx X-ray view may be helpful in assessing adenoid hypertrophy as still the main imaging study to evaluate the adenoid over the years. Various dimensions of the nasal cavity and nasopharynx have been measured to assess the degree of obstruction caused by adenoid hypertrophy and the aim is to correlate the measurements with the clinical manifestations with many techniques focus on the size of the nasopharyngeal stripe, which indicates the amount of airflow through the nasopharynx. [16]

This measurement seems to be most accurate when the nasopharyngeal stripe is half the size of the soft palate, significant obstruction occurs determine that the adenoid-nasopharyngeal ratio, measured by lateral neck closely correlated with clinical symptomatology related to adenoid hypertrophy. [17]

Serious postoperative complications related to surgery for the tonsils and adenoids have been reported. [18]

Fiberoptic nasopharyngeal endoscopy is considered the gold standard for the diagnosis and evaluation of adenoidal hypertrophy. This diagnostic method allows direct visualization of the nasal cavity and the nasopharynx providing a dynamic evaluation of the magnitude of nasal airway obstruction over the requirement of costly equipment and the need for child co-operation limit this diagnostic approach. [19] Our study data shows much improvement in the study group received Mometasone furoate after 6 weeks from initiation treatment subjectively as reduction in most of the nasal symptoms compared with it prior to the treatment.

The mechanism by which topical steroids would improve nasal airway obstructive symptoms remains unclear. [20] Criscuoli 2003 et al stated that there is improvement of nasal obstruction symptoms due to decrease adenoid size. after the application of nasal beclomethasone after two weeks. In spite of the short-term effect of intranasal corticosteroids, the long term outcome in patients who respond to therapy remains unclear. [21] Intranasal corticosteroids have been generally well tolerated and cause only mild side effects, even in the pediatric population. [22]

Zhang et al mentioned that intranasal corticosteroids may significantly improve nasal obstruction symptoms in children with moderate to severe adenoid hypertrophy, and this improvement is due to reduction of adenoid size. The long-term effect of intranasal corticosteroids in these patients remains to be defined. [23] Although it is not yet clear by which mechanisms the steroids reduce the nasal airway obstruction, however, there are some theories such as the anti-inflammatory effect of steroids that help to reduce adenoid size. [24]

Among several commercially available nasal steroid sprays, we select mometasone furoate for this study. This drug had report no adverse effects on growth and hypothalamic pituitary

adrenal axis. Also, the systemic availability of the drug after topical administration is lower than that of other steroids. [25] A recent study provided evidence that treatment with nasal steroids can be an effective management for adenoid hypertrophy and help in avoiding adenoidectomy as there was significant reduction in the size of the adenoid in lateral X-ray of the nasopharynx after 1 year with a p-value=.003. [11]

In this study, we do not replace the adenoidectomy operation, as it is the standard management for adenoid hypertrophy, but we search for another modality of management for cases that refused the surgical intervention or have a major contraindication for surgery.

Conclusion

Intranasal Mometasone furoate aqueous nasal spray may give some successful results in some cases of adenoid hypertrophy to improve nasal obstruction symptoms due to reduction of adenoid size.

Conflict of Interest

We conclude that there is no conflict of interest in writing this manuscript.

References

1. Bitar MA, Birjawi G, Youssef M, Fuleihan N. How frequent is adenoid obstruction? Impact on the diagnostic approach. *Pediatric Int.* 2009;51:478-483.
2. Javadyan A, Papadopoulos NG, Kafetzis DA. Rhinovirus infections and adenoidal hypertrophy: do they interact with atopy in children?. *Expert Review of Anti-infective Therapy.* 2003;1:223-9.
3. Kenna MA. Tonsils and adenoids. In: Behrman RE, Kliegman RM, Jenson HB editor(s). *Nelson Textbook of Pediatrics.* 16th Edition. Philadelphia: W.B. Saunders. 2000:1267-8.
4. Waitrak BJ, Woolley AL. Pharyngitis and adenotonsillar disease. Em: Cummings CW, Flint PW, editors. *Cummings otolaryngology head and neck surgery.* 4th ed. Philadelphia: Elsevier Mosby. 2005:4135-4139.
5. Grimmer JF, Poe DS. Update on Eustachian tube dysfunction and the patulous Eustachian tube. *Current Opinion in Otolaryngology and Head and Neck Surgery.* 2005;13:277-82.
6. Mary K, Anjali L, John M, Arif A, Jeyaseelan L. X-rays in the evaluation of adenoid hypertrophy: its role in the endoscopic era. *Journal of Indian Association of Pediatric Surgeons.* 2005;57:45-7.
7. Joshua B, Bahar G, Sulkes J, Shpitzer T, Raveh E, "Adenoidectomy: long-term follow-up," *Otolaryngology.* 2006;135:576-580.
8. Buchinsky FJ, Lowry MA, Isaacson G. Do adenoids regrow after excision? *Otolaryngol Head Neck Surg.* 2000;123:576-81.
9. Ark N, Kurtaran H, Ugur KS, Yilmaz T, Ozboduroglu AA, Mutlu C. Comparison of adenoidectomy methods: examining with digital palpation vs. visualizing the placement of the curette. *Int J Pediatr Otorhinolaryngol.* 2010;74:649-51. doi: 10.1016/j.ijporl.2010.03.012. Epub 2010 Apr 3.
10. Alexopoulos EI, Kaditis AG, Kalampouka E, Kostadima E,

- Angelopoulos NV, Mikraki V, et al. Nasal corticosteroids for children with snoring. *Pediatr Pulmonol.* 2004;38:161-167.
11. Sobhy TS. Role of intranasal steroid in the prevention of recurrent nasal symptoms after adenoidectomy. *Int J Otolaryngol.* 2013;2013:603493. doi: 10.1155/2013/603493. Epub 2013 Aug 4.
 12. Sharifkashani S, Dabirmoghaddam P, Kheirkhah M, Hosseinzadehnik R. A new clinical scoring system for adenoid hypertrophy in children. *Iran J Otorhinolaryngol.* 2015;27:55-61.
 13. Brown OE, Manning SC, Ridenour B. Cor pulmonale secondary to tonsillar and adenoidal hypertrophy: management considerations. *Int J Pediatr Otorhinolaryngol.* 1988;16:131-9.
 14. Oulis C.J, Vadiakas G.P, Ekonomides J, Dratsa J. The effect of hypertrophic adenoids and tonsils on the development of posterior cross bite and oral habits. *J. Clin. Pediatr. Dent.* 1994;18:197-201.
 15. Szalmás A, Papp Z, Csomor P, Kónya J, Sziklai I, Szekanecz Z, Karosi T. Microbiological profile of adenoid hypertrophy correlates to clinical diagnosis in children. *Biomed Res Int.* 2013;2013:629607.
 16. Feres MF, Hermann JS, Sallum AC, Pignatari SS. Radiographic adenoid evaluation: proposal of an objective parameter. *Radiol Bras.* 2014;47:79-83.
 17. Acar M, Kankilic ES, Koksai AO, Yilmaz AA, Kocaoz D. Method of the diagnosis of adenoid hypertrophy for physicians: adenoid-nasopharynx ratio. *J Craniofac Surg.* 2014;25:e438-40.
 18. De Luca Canto G, Pachêco-Pereira C, Aydinoz S, Bhattacharjee R, Tan HL, Kheirandish-Gozal L, Flores-Mir C, Gozal D. Adenotonsillectomy Complications: A Meta-analysis. *Pediatrics.* 2015;136:702-18.
 19. Neri G, Mennucci E, Ortore R, Leone O, Croce A. Rhinopharynx endoscopy in the diagnosis of chronic otitis media with effusion in infancy. *Acta Otorhinolaryngologica Italica.* 2004;24:63-7.
 20. Berlucchi M, Salsi D, Valetti L, Parrinello G, Nicolai P. The role of mometasone furoate aqueous nasal spray in the treatment of adenoidal hypertrophy in the pediatric age group: preliminary results of a prospective randomized study. *Pediatrics.* 2007;119:e1392-7.
 21. Criscuoli G, D'Amora S, Ripa G, Cinquegrana G, Mansi N, Impagliazzo N, et al. Frequency of surgery among children who have adenotonsillar hypertrophy and improve after treatment with nasal beclomethasone. *Pediatrics.* 2003;111:e236-8.
 22. Al Sayyad JJ, Fedorowicz Z, Alhashimi D, Jamal A. Topical nasal steroids for intermittent and persistent allergic rhinitis in children. *Cochrane Database of Systematic Reviews* 2007, Issue 4. [Art. No.: CD003163. DOI: 10.1002/14651858.CD003163.pub4]
 23. Zhang L, Mendoza-Sassi RA, César JA, Chadha NK. Intranasal corticosteroids for nasal airway obstruction in children with moderate to severe adenoidal hypertrophy. *Cochrane Database Syst Rev.* 2008 Jul 16;(3): CD006286.
 24. Lepcha A, Kurien M, Job A, Jeyaseelan L, Thomas K. Chronic adenoid hypertrophy in children — is steroid nasal spray beneficial? *Indian Journal of Otolaryngology and Head & Neck Surgery.* 2002;54:280-284. doi:10.1007/BF02993743.
 25. Jung YG, Kim HY, Min J-Y, Dhong H-J, Chung S-K. Role of Intranasal Topical Steroid in Pediatric Sleep Disordered Breathing and Influence of Allergy, Sinusitis, and Obesity on Treatment Outcome. *Clinical and Experimental Otorhinolaryngology.* 2011;4:27-32.