

Role of gel-films application versus middle meatal packing in maintenance of middle meatus patency after endoscopic middle meatal surgery

Khaled Mohamed Bofares

Professor of otorhinolaryngology, Omar Al-moukhtar University, Elbyda, Libya

E-mail: bofaresstat2012@yahoo.com

Pan Arab Journal of Rhinology
2018, 8:7-13

Background and Objectives: Functional endoscopic sinus surgery (FESS) is based mainly upon the intervention with the middle meatus. As it is well-established that the almost of the paranasal sinus groups are draining into middle meatus therefore the outcomes of FESS are depending mainly upon the post-operative maintenance of middle meatal patency. Although there are many clinical trials which described to achieve the sufficient patency of middle meatus after FESS but after performance of these established modalities the outcomes for some extent are still not satisfied therefore the idea of gel-film application at the interfered middle meatus was introduced and studied via this serial study just to confirm its effectiveness regarding maintenance of middle meatal patency as compared to middle meatal packing after FESS.

Patients and Methods: 105 patients aged 13-63 years of chronic sinusitis, presented with clinical as well as radiological evidences of solitary maxillary sinusitis, and maxillo-ethmoidal sinusitis with or without frontal and sphenoidal involvement at ENT OPD –Al-tarahom private center Elbyda city- Libya at period in between July 2013 to January 2017 who operated by FESS, and the patients divided into two groups; group-A (n=25) and group-B (n=80), which include those patients who proceeded after middle meatal endoscopic surgery by the middle meatal gel-films application and middle meatal packing consecutively. The two groups were compared in relation to post-operative patency persistence of ipsilateral middle meatus and correlated to the incidence of sinusitis recurrence after the surgery.

Results and Conclusion: Around 49% of the patients who underwent just medialization of ipsilateral middle turbinate followed by middle meatal packing developed recurrence of sinusitis due to re-obliteration of middle meatus either by synechia between middle turbinate and lateral wall or by extreme lateralization of the middle turbinate as compared to the other group among which one patient (4%) got evidences of recurrence of sinusitis due to re-obliteration of middle meatus by synechia between ipsilateral middle turbinate and opposite lateral wall after approximately one year of follow up. Thus we can conclude to that the gel-films application at middle meatus after middle meatal endoscopic surgery maintains significantly the postoperative middle meatal patency as compared to middle meatal packing.

Keywords: Middle meatal packing, middle meatal gel-film application, and middle meatal patency.

Pan Arab Journal of Rhinology 2018, 8:7-13

Introduction

The functional endoscopic sinus surgery (FESS) is considered as one of widely performed procedures in rhinology. Hence the middle meatus is the site for drainage of all para-nasal sinuses either directly or indirectly therefore the outcomes of FESS will depend mainly upon the middle meatal patency. On long run, main aims of FESS are the maintenance of proper drainage as well as sufficient ventilation to the drained para-nasal sinuses. This based critically on the achievement of enough and persistent middle meatal patency. Although the ethmoidal infundibulectomy is considered as the cornerstone to provide a sufficient drainage as well as ventilation to drained para-nasal sinuses and this can be obtained by complete uncinectomy in addition to partial de-bulking of middle turbinate in contrary the postoperative lateralization

of middle turbinate may result in re-obliteration of middle meatus thus there must adjuvant techniques for fixation and stabilization of the middle turbinate at medial position to maintain the postoperative well-controlled middle meatal patency. [1-10,16]

In fact there are many clinical reports that claimed the description of variable patterns of techniques to reach the preserved optimum stability of middle turbinate at medial position after FESS. [1-17] One of these techniques which recommended by Michael and Marple is the conchopexy of middle turbinate this performed by the stitch fixation of middle turbinate into the nasal septum using vicryl 4/0 of needle size P3 thus there is no need for middle meatal packing after performance of this technique. In accordance,

Hicks, Jebeles, and Marple described other simple technique which conducted just by medialization of middle turbinate with the maintenance of its stability by avoidance of its fracture and the middle meatal pack is inserted for 48 hours just to keep the middle turbinate at medial position. On the other hand, Bolger and Kennedy postulated the controlled synechia technique this procedure is depending mainly upon the creation of synechia between middle turbinate and nasal septum this is performed by making four shallow incision using sickle knife on the mucosal surface of both middle turbinate as well as corresponding nasal septum, the violated mucosal surfaces are abutted to each other by middle meatal packing for 24-48 hours and after its remove the gel-film is applied at middle meatus to prevent the possible adhesions between middle turbinate and lateral wall. In accordance Friedman and Schalch authorized other manner of controlled synechia technique that performed by violating the mucosal surfaces on both middle turbinate as well as nasal septum using micro-debrider in spite of sickle knife and after denuding of mucosa the bovine serum albumin tissue adhesive (Bio-glue) is applied on each violated surface furtherly the middle meatal ribbon gauze pack is inserted just for three minutes to allow the fixation and adhesion of both surfaces to each other. In addition Koppersmith and Atkins cited that the middle meatal patency can be maintained by application of bio-resorbable implant which made by L- lactide- CO- glycolide biochemical substance this implant has four barbs, three toward the middle turbinate and one toward the nasal septum. [8]

All previously described techniques are dealing with the maintenance of middle turbinate position. Hence the middle turbinate constitutes one of important components of ostio-meatal complex and as middle turbinate position is significant also its bulk considered as important factor that affect the middle meatal patency thus for achievement of sufficient ethmoidal infundibulectomy the middle turbinate mass need to be interfered too. [1-25] The partial middle turbinectomy is considered as significant step toward the keeping of enough middle meatal patency this can be done by reducing the middle turbinate bulk at its lateral side as well as at its lower part using micro-debrider. [1,3-26] During the medialization of middle turbinate, its in-fracture must be avoided because this makes the middle turbinate more unstable at its shoulder and subsequent lateralization may occur resulting in postoperative re-obliteration of middle meatus. In accordance it becomes very necessary to interfere with the abnormal conditions of middle turbinate that may affect its position and/or its bulk as concha bullosa, floppy middle turbinate, paradoxical middle turbinate and duplicated middle turbinate therefore the preoperative endoscopic as well as radiological assessment of middle turbinate is mandatory. [1-26,32-36]

Although there are several studies that tried to evaluate the effect of these previously mentioned techniques on the middle meatal patency and thus on the FESS outcomes but at this moment and through the reviewing of literatures we feel that there is no data regarding the effect of the intraoperative middle meatal applied gel-films on outcomes of FESS, for this reason we planned this serial study to reach to these aims:

- I. To confirm the significance of intraoperative middle meatal applied gel-films as one of important steps for FESS.
- II. To postulate a comparative elucidation between this technique and other different middle turbinate intervention techniques namely the medialization of middle turbinate with middle meatal packing to conclude which technique has the best results after FESS.

Patients and Methods

105 patients aged 13-63 years of chronic sinusitis, presented with clinical as well as radiological evidences of solitary

maxillary sinusitis, and maxillo-ethmoidal sinusitis with or without frontal and sphenoidal involvement at ENT OPD –Al-tarahom private center Elbyda city- Libya at period in between July 2013 to January 2017 who operated by FESS, and the patients divided into two groups; group-A (n=25) and group-B (n=80), which include those patients who proceeded after middle meatal endoscopic surgery by the middle meatal gel-films application and middle meatal packing consecutively. All patients were adequately assessed pre-operatively by complete history, local endoscopic evaluation, and coronal, axial as well as sagittal CT scan demonstrations. The patients who decided for surgery had been proved with failed medical treatment or recurrence after insufficient previous surgery. There were four adult patients who confirmed with high suggestion of eosinophilic nasal polyposis with co-morbid bronchial asthma. The internationally recommended steps of basic FESS were followed as: a) the medialization of ipsilateral middle turbinate just to get access to middle meatus, b) partial uncinectomy, c) anterior ethmoidectomy which was done by complete exentration of bulla ethmoidalis, d) posterior ethmoidectomy which was done by resection of vertical portion of basal lamella of middle turbinate and further exentration of posterior ethmoidal air cells, e) accordingly this may be associated with further non-cutting Draf-I frantostomy and\ or sphenoidotomy. The non-cutting Draf-I frantostomy was performed as preserved as well as non-preserved bullar techniques, and f) middle meatal antrostomy was done subsequently. At beginning of surgery the contour of middle turbinate with most lateral part of uncinuate process were preserved just to be used as significant anatomical landmarks for finishing of safe and proper further resection steps. Finally the maintenance of medial position of middle turbinate had been done accordingly either by middle meatal gel-films application or middle meatal packing followed by the resection of residual part of uncinuate process.

All patients followed-up postoperatively for six weeks to elucidate for any occurrence of post-operative middle meatal obliteration by synechia or lateralization of ipsilateral middle turbinate. The patients at both groups were compared with each other regarding the post-operative improvement in relation to patients' symptomology, endoscopic findings, as well as radiological findings.

An informed consent was taken from the patients involved in the research prior to their participation.

Data were expressed by using descriptive analysis as means + standard error of mean (s. e. m) and percentages, test of significance was carried out, using Chi-square test and two way analysis of variance. A probability less than 0.05 was considered as significant, the degree of significance was determined by using level of standard deviation test. Student -t- test was used for dependent sample, as well as contingency coefficient was calculated as measurement of association between nominal variables.

Results

As demonstrated in (Fig. 1) the rate of post-operative improvement regarding patients' symptomology is significantly increased among group-A as compared to group-B (P<0.05). On the other hand, as illustrated in (Fig. 2) the incidence of post-operative obliteration of middle meatus by synechia as well as lateralization of middle turbinate was significantly higher among group-B as compared to group-A (P<0.01). In accordance the (Fig. 3) postulated the non-significant difference of post-operative local mucosal healing among group-A as compared to group-B (P>0.5). By further observations, (Fig. 4) elucidated the significant raising of adverse effects incidence rate after middle meatal packing as compared to middle meatal gel-films application (P<0.01).

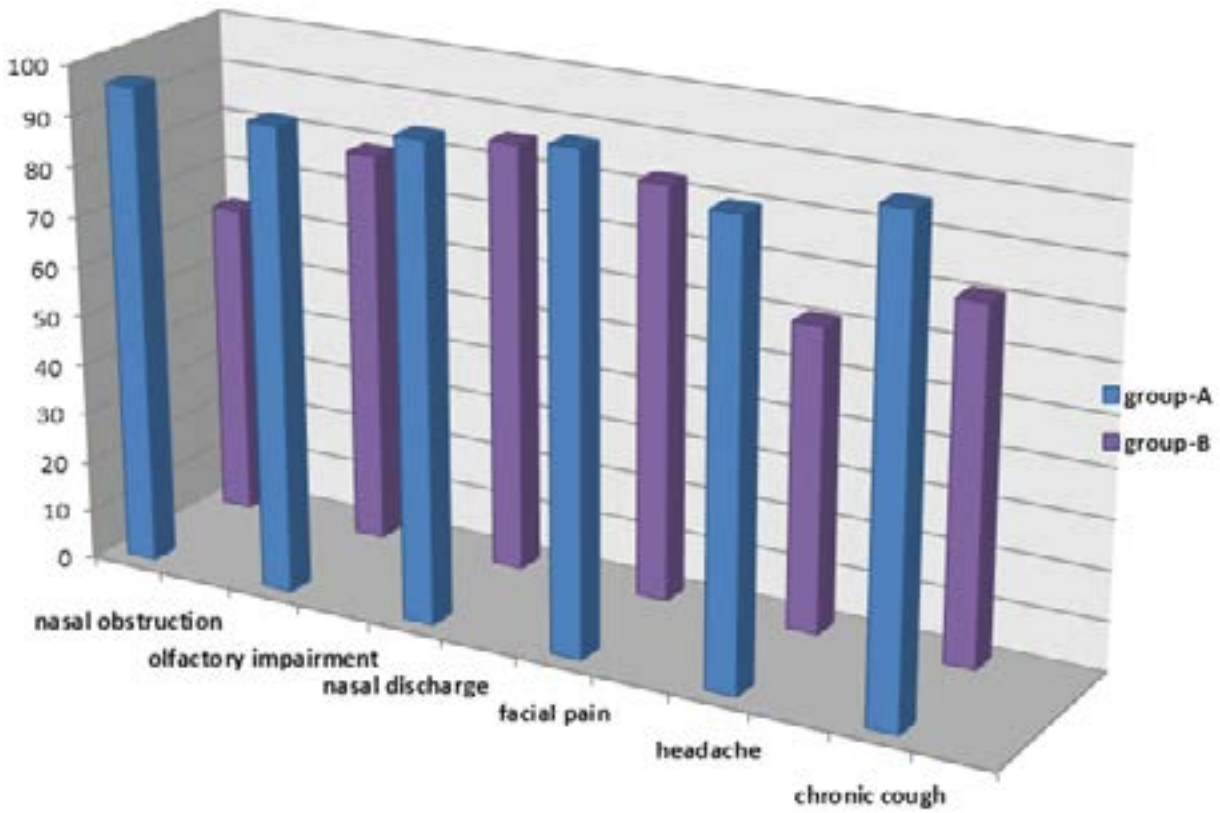


Fig 1 The rate of post-operative improvement (%) regarding symptomology among chronic rhino-sinusitis patients in relation to different middle meatal applications after middle meatal endoscopic surgery ($P < 0.05$)

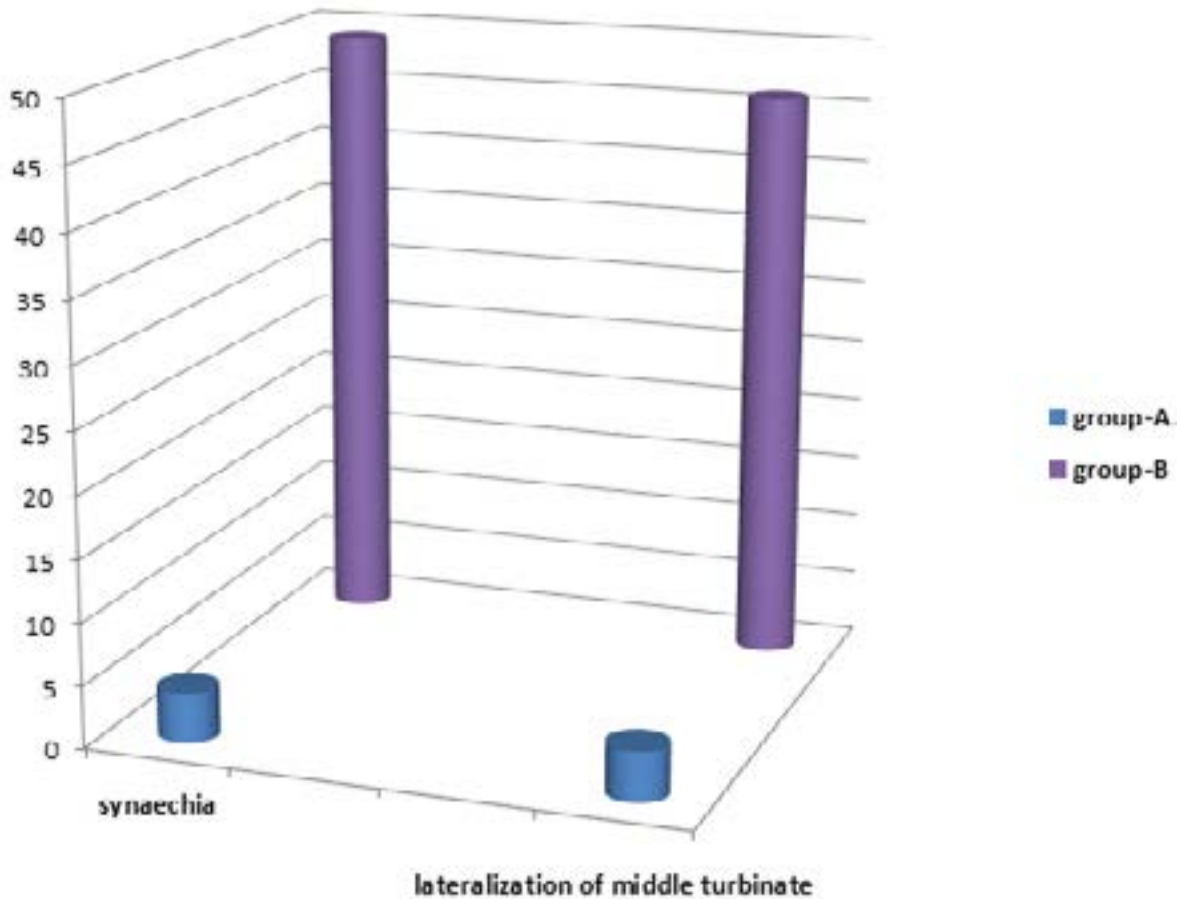


Fig 2 The incidence of post-operative middle meatal obliteration (%) by synecchia and middle turbinate lateralization in relation to different middle meatal applications after middle meatal endoscopic surgery ($P < 0.01$)

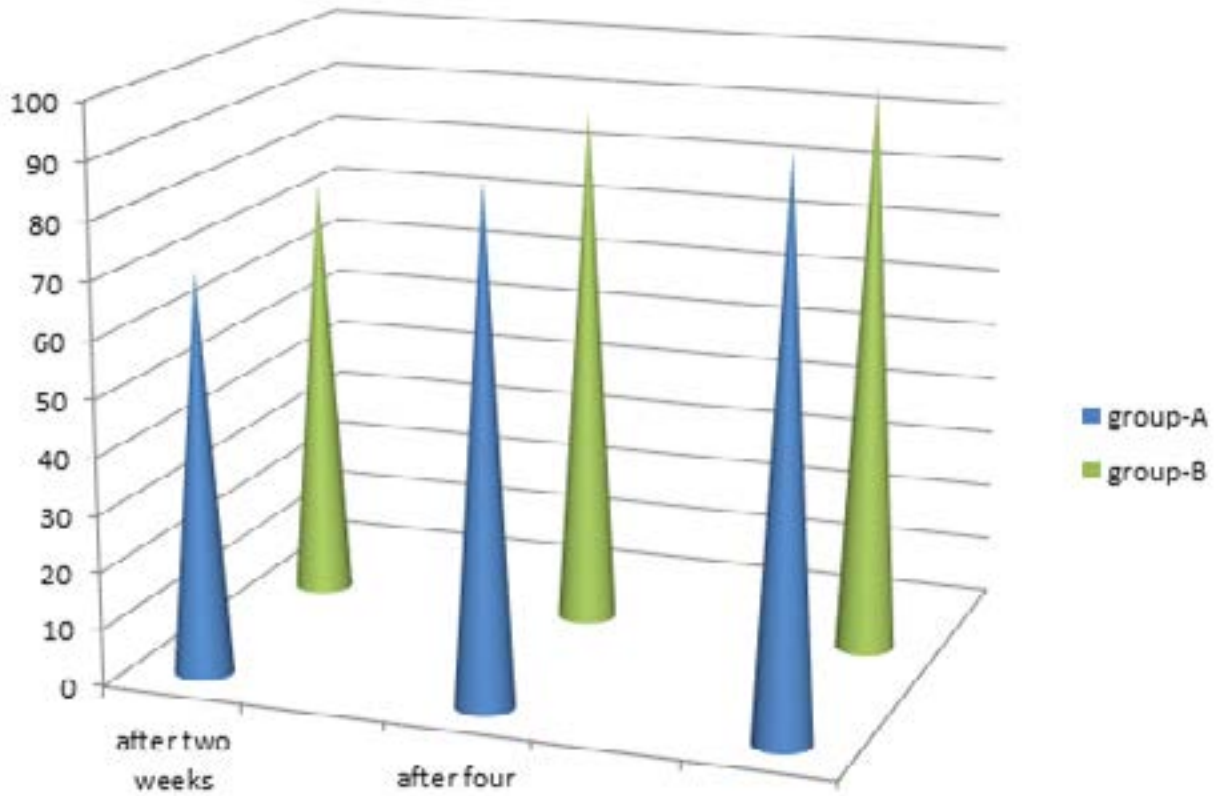


Fig 3 The rate of post-operative local mucosal healing (%) in correlation with different middle meatal applications after middle meatal endoscopic surgery ($P > 0.5$)

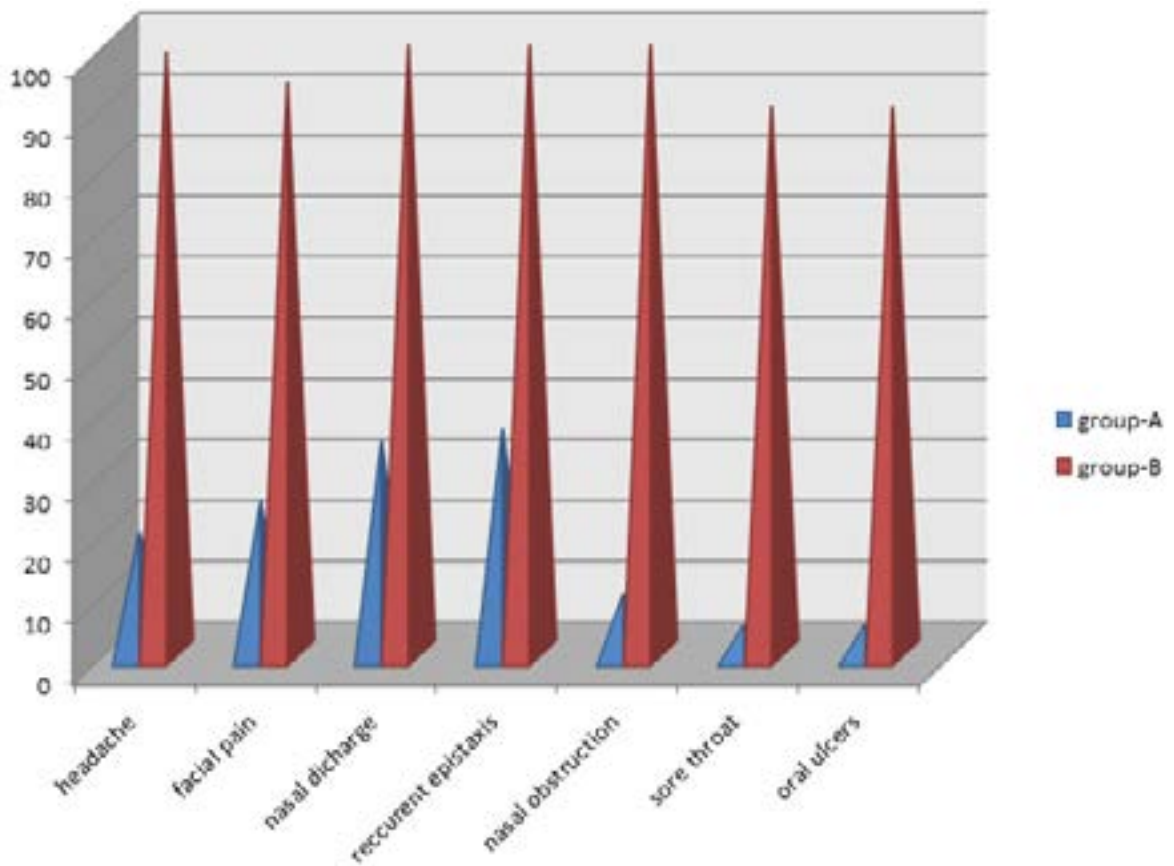


Fig 4 The incidence of adverse effects of middle meatal gel-films application as compared to middle meatal packing after middle meatal endoscopic surgery ($P < 0.01$)

Discussion

The cornerstone of FESS is the providing of sufficient drainage, ventilation, and enough accessibility through the middle meatus. Thus any technique is introduced and claimed to be the ideal technique for middle turbinate intervention must deserve this goal. However the conchopexy is considered as effective technique because the middle turbinate is fixed to the nasal septum by stitch but technically speaking this procedure can be described as difficult modality of middle turbinate interventions. [1-36]

On the other hand, the solitary medialization of middle turbinate can be considered as insufficient procedure because there is high risk of postoperative lateralization of middle turbinate and thus subsequent re-obliteration of middle meatus. In addition in this procedure the middle turbinate position is maintained by application of middle meatal pack for at least 48 hours this will be accompanied with the packing related problems as headache, facial pain, recurrent epistaxis, persistent nasal discharge, nasal obstruction with mouth breathing, oral cavity dryness, and oral ulcers. [1-36]

In accordance the controlled synechia technique which authorized by Bolger and Kennedy is associated with same previously mentioned packing related adverse effect although the risk of re-lateralization of middle turbinate is lower because of the created adhesions between violated middle turbinate and nasal septum. [1-36]

In contrary the controlled synechia technique which described by Friedman and Schalch has no accompanied packing adverse effects but the Bio-glue i.e. bovine serum albumin tissue adhesive is difficult to be obtained as well as it is expensive material that cannot be routinely used. [1-36]

The KupperSmith and Atkins technique is very effective procedure because it is based upon the fixation of middle turbinate into the nasal septum by application of resorbable implant with four barbs and in spite of the effectiveness of this technique but still it may be considered as of lower accessibility because of high price of applied implant thus it cannot be routinely used at all centers.

Although Bolger and Kennedy recommended the insertion of gel-films postoperatively after remove of middle meatal pack this to interfere with the possibility of synechia formation between the middle turbinate and the lateral nasal wall resulting in the re-obliteration of middle meatus. The question which is raised now, why the gel-films are not applied intraoperatively instead of the middle meatal packs? This may help in the maintenance of middle meatal patency with the avoidance of adverse effects of middle meatal packing. For this reason this serial study was planned to postulate the effect of intraoperative gel-films application on the preservation of enough middle meatal patency in addition to elucidation of the incidence rate of epistaxis, perfuse nasal discharge, facial pain, headache, nasal obstruction with mouth breathing, oral cavity dryness, oral cavity ulcers and sore throat that associated with gel-films application as compared to middle meatal packing. In accordance it was decided to illustrate the local mucosal healing rate after gel-films application as compared to middle meatal packing.

As the main aim of this serial study, it was found that the efficacy of gel-films application is significantly higher for middle meatal patency preservation as compared to packing technique this can be correlated to the long standing sustaining of gel-films at middle meatal area which may reach up to 10-14 days this will antagonize any possible fibrous tissue genesis at middle meatal area that may attract the middle turbinate toward the lateral side and causing re-obliteration of middle meatus.

Regarding the evaluation for suggested adverse effects of both techniques it was found that the incidence rate of epistaxis after FESS significantly reduced by middle meatal gel-films application as compared to middle meatal packing this can be explained by the homeostatic effect of gel-films material due to their influence for enhancement of platelets aggregations at the site of oozing. On the other hand, almost of the nasal packs materials have no physiological efficacy toward the homeostasis control and their action is confined to the local pressure effect for this reason they have no sufficient role regarding control of epistaxis.

From the other aspect, this serial study proved that nasal discharge is significantly increased by middle meatal packing as compared to middle meatal gel-film application this can be reasoned by these three possible facts: a) the pack by its size as well as its material is persistently irritating the mucosa with Goblet cells resulting in over activity of these secreting cells, b) the presence of pack will obstruct the flow of secretions drainage leading to over accumulation of these secretions, and c) the pack material itself may act as allergen that enhance the cascade of IgE mediated hypersensitivity reaction which produce local inflammatory mediators namely histamine, bradykinin, prostaglandins, protease enzyme, lysozymes and hyaluronidase enzyme which increase the local vascularity as well as the mucosal sensitivity and subsequently the nasal secretions will be over produced.

In addition, it was found that the incidence rate of headache as well as facial pain is significantly increased by middle meatal packing as compared to middle meatal gel-films application this can be correlated to two reasons: a) the pressure effect of the middle meatal pack itself and b) the obstruction of paranasal sinuses drainage and ventilation after middle meatal packing as compared to middle meatal gel-film application.

Hence the middle meatal packs have larger sizes as compared to gel-film pieces thus the middle meatal packing will be associated with significant nasal obstruction as compared to gel-films application. This can be discussed under two possible etiologies: a) the mechanical obstruction which is due to the obliteration of the nasal cavity by large sized packs, and b) the functional obstruction which might be due to the local reactive nasal congestion as the result of enhanced IgE hypersensitivity reaction to the allergen-acting pack materials therefore concomitantly the incidence rate of oral dryness as well as oral ulcers is increased significantly after middle meatal packing as compared to middle meatal gel-films application.

As it was observed via this serial study, the gel-films application after middle meatal endoscopic surgery might be associated with difficult early postoperative middle meatal routine care in form of repetitive endoscopic inspections as well as suction and clearance this is due to the sustaining of local gel-films that interfere with this care. This established disadvantage of gel-films application technique can be overcome by delaying of the planned postoperative care.

Therefore it can be concluded from this study that the middle meatal gel-films application had been proved with rough significant potential post middle meatal endoscopic surgery benefits as compared to middle meatal packing. Although the number of patients who were applied for this technique was insufficient as well as non-conclusive, and because of lack of proper helpful facilities, mostly the parameters as well as the indicators at this study were evaluated subjectively rather than objectively mainly depending upon the clinical observations and suggestions which decrease the rate of our results accuracy, in addition the references which applied have no direct relation with the title and the aim of this serial study and just cited to help for extent in supporting the

knowledge which were presented at the introduction as well as discussion chapters thus the further confirmative studies are recommended too.

References

- Petros Vlastarakos, Emilia Iacovou, Melina Fetta, Thomas P. Nikolopoulos. How effective is postoperative packing in FESS patients? A critical analysis of published interventional studies. *Archiv für Klinische und Experimentelle Ohren- Nasen- und Kehlkopfheilkunde*. 2015;273:12.
- Jason H Franklin, Erin D Wright. Randomized, controlled, study of absorbable nasal packing on outcomes of surgical treatment of rhinosinusitis with polyposis. *Archiv für Klinische und Experimentelle Ohren- Nasen- und Kehlkopfheilkunde*. 2007.
- Peter J Catalano, Eric J Roffman. Evaluation of Middle Meatal Stenting after Minimally Invasive Sinus Techniques (MIST). *Archiv für Klinische und Experimentelle Ohren- Nasen- und Kehlkopfheilkunde*. 2003.
- Jonathan Pomerantz, Jay M Dutton. Platelet Gel for Endoscopic Sinus Surgery. *Archiv für Klinische und Experimentelle Ohren- Nasen- und Kehlkopfheilkunde*. 2005.
- Ying-Piao Wang, Mao-Che Wang, Yu-Chun Chen. The effects of Vaseline gauze strip, Merocel, and Nasopore on the formation of synechia. *Journal of the Chinese Medical Association*. 2017.
- Kathleyn A Brandstetter, Joseph A Jurcisek, Steven D Goodman, Subinoy Das. Antibodies Directed Against Integration Host Factor Mediate Biofilm Clearance From Nasopore. *The Laryngoscope*. 2017.
- Rowan Valentine, Peter John Wormald. Nasal dressings after endoscopic sinus surgery: What and why?. *Current opinion in otolaryngology & head and neck surgery*. 2017.
- Tang-Chuan Wang, Chih-Jaan Tai, Yung-An Tsou, Ming-Hsui Tsai. Absorbable and non-absorbable packing after functional endoscopic sinus surgery: systematic review. *Archiv für Klinische und Experimentelle Ohren- Nasen- und Kehlkopfheilkunde*. 2017.
- Berlucchi M, Castelnuovo P, Vincenzi A, Morra B, Pasquini E. Endoscopic outcomes of resorbable nasal packing after functional endoscopic sinus surgery: a multicenter prospective randomized controlled study. *Eur Arch Otorhinolaryngol*. 2009;266:839-45. doi: 10.1007/s00405-008-0841-3. Epub 2008.
- Franklin JH, Wright ED. Randomized, controlled, study of absorbable nasal packing on outcomes of surgical treatment of rhinosinusitis with polyposis. *Am J Rhinol*. 2007;21:214-7.
- Hu KH, Lin KN, Li WT, Huang HM. Effects of Meropack in the middle meatus after functional endoscopic sinus surgery in children with chronic sinusitis. *Int J Pediatr Otorhinolaryngol*. 2008;72:1535-40. doi: 10.1016/j.ijporl. 2008.07.006. Epub 2008.
- Wormald PJ, Boustred RN, Le T, Hawke L, Sacks R. A prospective single-blind randomized controlled study of use of hyaluronic acid nasal packs in patients after endoscopic sinus surgery. *Am J Rhinol*. 2006;20:7-10.
- Verim A, Seneldir L, Naiboğlu B, Karaca ÇT, Külekçi S, Toros SZ, Oysu Ç. Role of nasal packing in surgical outcome for chronic rhinosinusitis with polyposis. *Laryngoscope*. 2014;124:1529-35. doi: 10.1002/lary.24543. Epub 2014.
- Song KJ, Lee HM, Lee EJ, Kwon JH, Jo KH, Kim KS. Anti-adhesive effect of a thermosensitive poloxamer applied after the removal of nasal packing in endoscopic sinus surgery: a randomised multicentre clinical trial. *Clin Otolaryngol*. 2013;38:225-30. doi: 10.1111/coa.12117.
- Miller RS, Steward DL, Tami TA, Sillars MJ, Seiden AM, Shete M, Paskowski C, Welge J. The clinical effects of hyaluronic acid ester nasal dressing (Merogel) on intranasal wound healing after functional endoscopic sinus surgery. *Otolaryngol Head Neck Surg*. 2003;128:862-9.
- Shi R, Zhou J, Wang B, Wu Q, Shen Y, Wang P, Wang J, Wang Y, Chen Y, Shu XZ. The clinical outcomes of new hyaluronan nasal dressing: a prospective, randomized, controlled study. *Am J Rhinol Allergy*. 2013;27:71-6. doi: 10.2500/ajra.2013.27.3833.
- Côté DW, Wright ED. Triamcinolone-impregnated nasal dressing following endoscopic sinus surgery: a randomized, double-blind, placebo-controlled study. *Laryngoscope*. 2010;120:1269-73. doi: 10.1002/lary.20905.
- Cruise AS, Amonoo-Kuofi K, Srouji I, Kanagalingam J, Georgalas C, Patel NN, Badia L, Lund VJ. A randomized trial of Rapid Rhino Riemann and Telfa nasal packs following endoscopic sinus surgery. *Clin Otolaryngol*. 2006;31:25-32.
- Jorissen M, Bachert C. Effect of corticosteroids on wound healing after endoscopic sinus surgery. *Rhinology*. 2009;47:280-6.
- Bugten V, Nordgård S, Steinsvåg S. Long-term effects of postoperative measures after sinus surgery. *Eur Arch Otorhinolaryngol*. 2008;265:531-7. Epub 2007.
- Bugten V, Nordgård S, Skogvoll E, Steinsvåg S. Effects of nonabsorbable packing in middle meatus after sinus surgery. *Laryngoscope*. 2006;116:83-8.
- Chen Q, Sun G, Wang Y, Zhong W, Shu XZ. The evaluation of two new hyaluronan hydrogels as nasal dressing in the rabbit maxillary sinus. *Am J Rhinol Allergy*. 2012;26:152-6. doi: 10.2500/ajra.2012.26.3715. Epub 2011.
- Kastl KG, Betz CS, Siedek V, Leunig A. Effect of carboxymethylcellulose nasal packing on wound healing after functional endoscopic sinus surgery. *Am J Rhinol Allergy*. 2009;23:80-4. doi: 10.2500/ajra.2009.23.3267.
- Dijkstra MD, Ebbens FA, Poublon RM, Fokkens WJ. Fluticasone propionate aqueous nasal spray does not influence the recurrence rate of chronic rhinosinusitis and nasal polyps 1 year after functional endoscopic sinus surgery. *Clin Exp Allergy*. 2004;34:1395-400.
- Leunig A, Betz CS, Siedek V, Kastl KG. CMC packing in functional endoscopic sinus surgery: does it affect patient comfort? *JAMA Otolaryngol Head Neck Surg*. 2009;47:36-40.
- Konstantinidis I, Tsakiropoulou E, Vital I, Triaridis S, Vital V, Constantinidis J. Intra- and postoperative application of Mitomycin C in the middle meatus reduces adhesions and antrostomy stenosis after FESS. *Rhinology*.

2008;46:107-11.

27. Anand VK, Tabaee A, Kacker A, Newman JG, Huang C. The role of mitomycin C in preventing synechia and stenosis after endoscopic sinus surgery. *Am J Rhinol.* 2004;18:311-4.
28. Fang KM, Wang CT, Chen YW, Huang TW. Reduction of adhesions and antrostomy stenosis with topical vitamin A after endoscopic sinus surgery. *Am J Rhinol Allergy.* 2015;29:430-4. doi: 10.2500/ajra.2015.29.4235.
29. Baguley CJ, Stow NW, Weitzel EK, Douglas RG. Silastic splints reduce middle meatal adhesions after endoscopic sinus surgery. *Am J Rhinol Allergy.* 2012;26:414-7. doi: 10.2500/ajra.2012.26.3810.
30. Hu KH, Lin KN, Li WT, Huang HM. Effects of Meropack in the middle meatus after functional endoscopic sinus surgery in children with chronic sinusitis. *Int J Pediatr Otorhinolaryngol.* 2008;72:1535-40. doi: 10.1016/j.ijporl.2008.07.006. Epub 2008.
31. Murr AH, Smith TL, Hwang PH, Bhattacharyya N, Lanier BJ, Stambaugh JW, Mugglin AS. Safety and efficacy of a novel bioabsorbable, steroid-eluting sinus stent. *Int Forum Allergy Rhinol.* 2011;1:23-32. doi: 10.1002/alr.20020. Epub 2011.
32. Friedman M, Schalch PS. Middle turbinate medialization with bovine serum albumin tissue adhesive (Bio-Glue). *Laryngoscope.* 2008;118:335-8.
33. Jebeles JA, Hicks JN. The use of MeroCel for temporary medialization of the middle turbinate during functional endoscopic sinus surgery. *Ear Nose Throat J.* 1993;72:145-6.
34. Weitzel EK, Wormald P. A scientific review of middle meatal packing\ stents. *Am J Rhinol.* 2008;22:302-7.
35. Berlucchi M, Castelnuovo P, Vincenzi A, Morra B, Pasquini E. Endoscopic outcomes of resorbable nasal packing after functional endoscopic sinus surgery: a multicenter prospective randomized controlled study. *Eur Arch Otorhinolaryngol.* 2009;266:839-45. doi: 10.1007/s00405-008-0841-3. Epub 2008.
36. Kuppersmith RB, Atkins JH. The use of bioresorbable implant to medialize the middle turbinate in sinus surgery. *Otolaryngol Head Neck Surg.* 2009;141:781-2.