Endoscopic septoplasty: Why, how and when

Mohamed Elsayed

Department of ORL, Ahmed Maher Teaching Hospital, Egypt

E-mail: elsayed1960@hotmail.com

Pan Arab Journal of Rhinology
2017, 7:50-56

Septal pathology contributes to almost all nasal deformity. In a high percentage, septal deformities are the main cause of functional complaints. They are also at the root of aesthetic complaints. We may quote Cottle, [1] who said (As the septum goes, so goes the nose). So, correction of septal deformity is one of the basic procedures in functional reconstructive nasal surgery. Correction of external nose is impossible without septal repair. In a sense, the septum is the (Soul) of the human nose. The application of endoscopic techniques to correct septal deformities was initially described by: lanza [2] and Stammberger. [3] The advances in endoscopic techniques have facilitated endoscopic septoplasty. Many authors (Hundreds) wrote on endoscopic septoplasty,

- Siegel N, Glicklich R, Taghizadeh F, Chang Y. 2000. [4]
- Hwang PH, McLaughlin RB, Lanza DC, Kennedy DW. 1999. [5]
- Chung BJ, Batra PS, Citardi MJ, Lanza DC. 2007. [6]
- Cantrell H. 1997. [7]
- Elsayed M, et al. 2005. [8]

All these authors do limited endoscopic septoploasty. So in this work we will do (Kottle) septoplasty endoscopically Following the basic rules of Cottle.The advances in endoscopic techniques have facilitated endoscopic septoplasty. Endoscopic septoplasty is useful in difficult as well as simple cases. Endoscopic septoplasty is a relatively recent and important technique. The purpose of this study was to review the surgical technique, indications, and outcomes for endoscopic septoplasty.

Methods: A retrospective review was conducted to identify patients undergoing endoscopic septoplasty between 2010 and 2012 at a Tertiary care medical center (Ahmed Maher Teaching Hospital, Cairo). Operative indications, adjunctive procedures, symptom outcome, and complications were recorded.

Results: 100 patients with a mean age of 23 years were identified. The male/female ratio was 3:1 and mean follow-up period was 13 months. Indications for endoscopic septoplasty included nasal obstruction (82%). In 33 patients endoscpic sinus surgery is done and rhinoplasty in 12 patients. Turbinoplasty is done in all cases. In all patients there were satisfactory subjective results with patent airway, improved fitness and reduced upper respiratory tract infection attacks as experienced by the patients. There was one case of septal hematoma (localized anterior and evacuated under local anaesthia). No cases of septal abscess, No perforation, No supratip depression, No synachia. Under correction occurred in 9 case and there were satisfaction by the patients and no over correction

Conclusion: Endoscopic septoplsty is very safe & effective either alone or with other nasal operation. It improves illumination and accuracy. Also is very valuable and indispensable in teaching and documentation. Following the basics rules in simple as well as difficult cases is challenging.

Pan Arab Journal of Rhinology 2017, 7:50-56

Introduction

Septal pathology contributes to almost all nasal deformity. In a high percentage, septal deformities are the main cause of functional complaints. They are also at the root of aesthetic complaints. We may quote Cottle, [1] who said (As the septum goes, so goes the nose). So, correction of septal deformity is one of the basic procedures in functional reconstructive nasal surgery. Correction of external nose is impossible without septal repair. In a sense, the septum is the (Soul) of the human nose. Correction of external nose is impossible without septal repair. The application of endoscopic techniques to correct septal deformities was initially described by: lanza [2] and Stammberger. [3] The advances in endoscopic techniques have facilitated endoscopic septoplasty. Many authors (Hundreds) wrote on endoscopic septoplasty,

- Siegel N, Glicklich R, Taghizadeh F, Chang Y. 2000. [4]
- Hwang PH, McLaughlin RB, Lanza DC, Kennedy DW. 1999. [5]
- Chung BJ, Batra PS, Citardi MJ, Lanza DC. 2007. [6]
- Cantrell H. 1997. [7]
- Elsayed M, et al. 2005. [8]

All these authors do limited endoscopic septoploasty. So in this work we will do (Kottle) septoplasty endoscopically Following the basic rules of Cottle. [1]

Material and Methods

One hundred patients of deviated nasal septum were admitted in the department of otorhinolaryngology, Ahmed Maher Teaching Hpspital for endoscopic septal surgery from January 2010 to November 2012. Including cases of:

dislocated caudal end 45 cases (45%), fracture septum 8 cases (8%), vomeral spur 28 cases (28%) and basal crest 19 cases (19%). Endoscpic sinus surgery is done in 33 patients and rhinoplasty in 12 patients. Turbinoplasty is done in all cases. Male: female ratio was 3:1 and the age range was 10-48 years old with average 23. Under general anaesthia (Hypotensive protocol) Kottle septoplasty was performed endoscopically. We follow basic of septoplasty by Kottle:

1. Approach
2. Mobilization
3. Resection
4. Repositioning
5. Reconstruction
6. Fixation

How I do it

Topical oxymetazoline was applied for decongestion; 1% lidocaine with 1:200,000 epinephrine was injected subperichondrially along the septum and at the greater palatine foramina bilaterally.

a- Incision: Caudal septal incision (Hemi transfixion). **(Figs. 1a,b).**

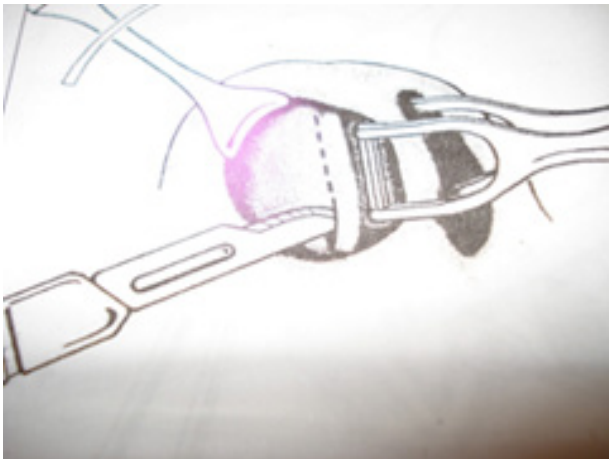

Fig 1a

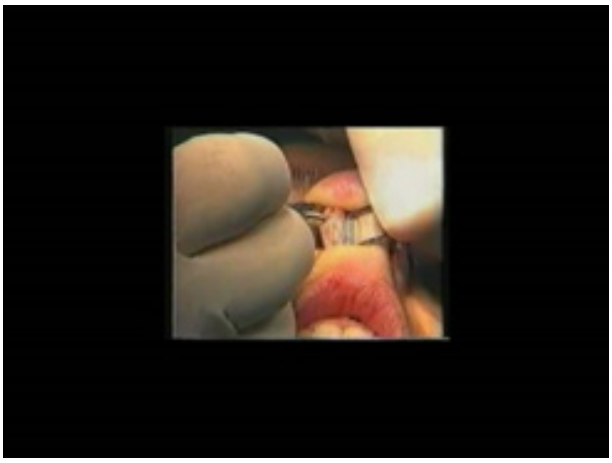

Fig 1b Hemi transfixion incision

b- Flap elevation: Subperichonrium using septal dissector **(Figs. 2a,b).**

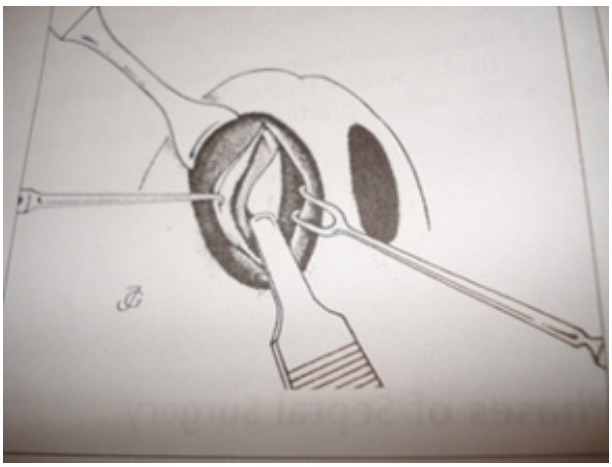

Fig 2a

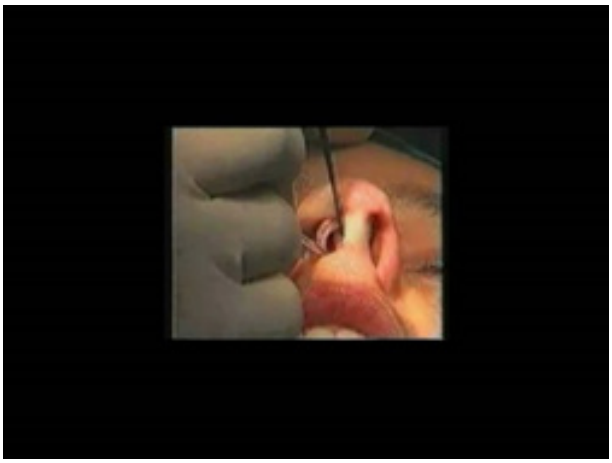

Fig 2b

C. Nasal speculum; either self retaining speculum is used or assistant holding it. Zero telescope 4 mm is introduced through the dissected area and dissection is continued exposing bony and cartilaginous septum **(Figs 3,4)**.

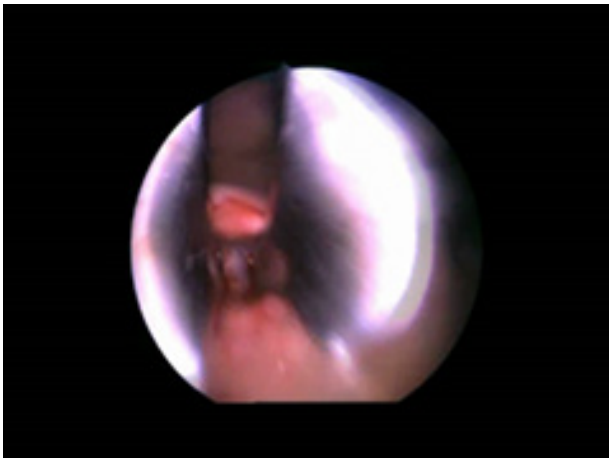

Fig 3

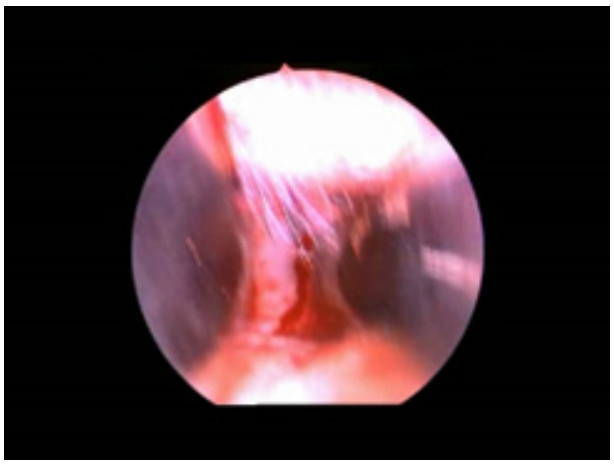

Fig 4

d. Follow the basics by creating antrosuperior tunnel (Unilater or bilateral) to mobilize cartilaginous septum. Then postrosuperior tunnel to mobilize bony septum **(Figs 5-7)**.

Fig 5

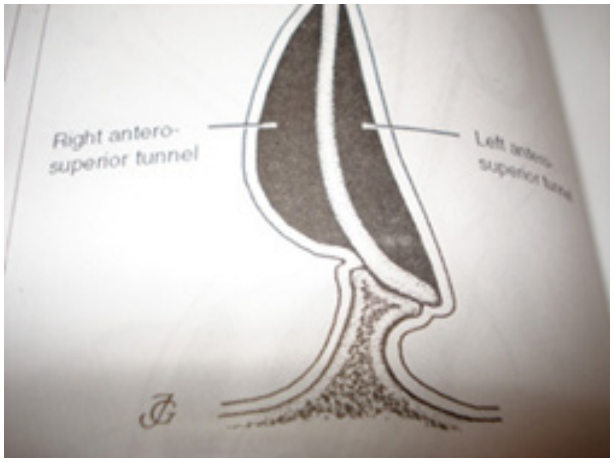

Fig 6

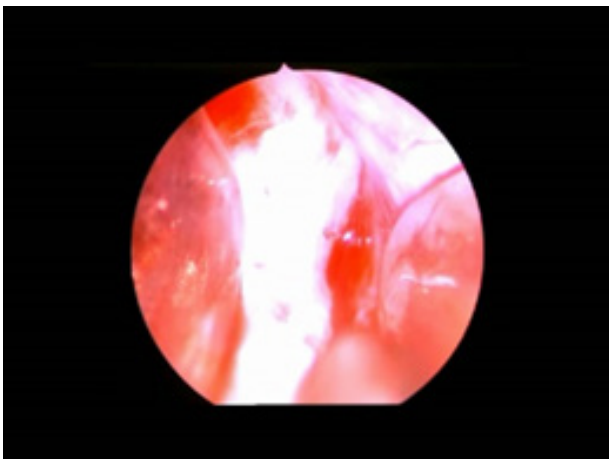

Fig 7

Vertical **(Figs 8a,b)** and horizontal condrotomy **(Figs 9a,b)** to create a swinging door technique (Cottel)

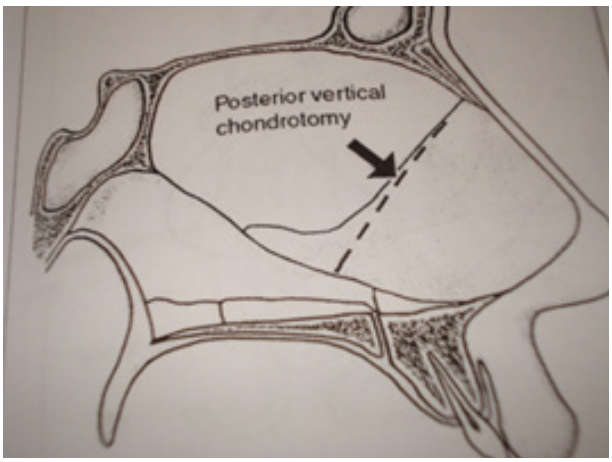

Fig 8a

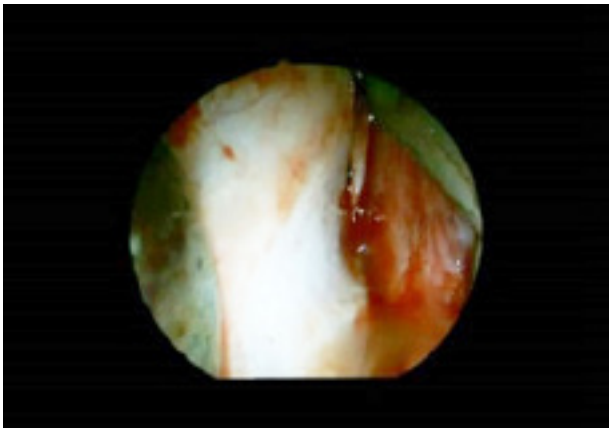

Fig 8b

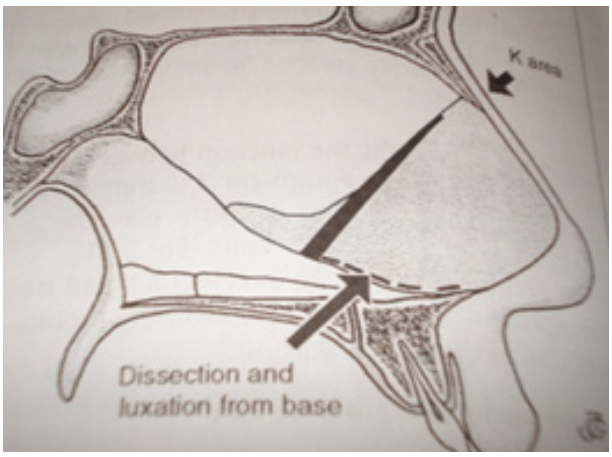

Fig 9a

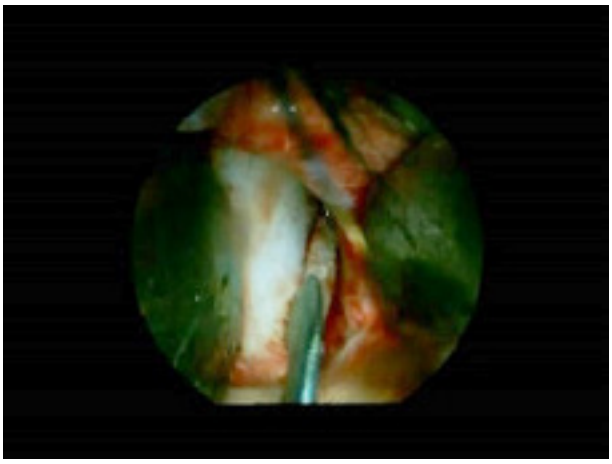

Fig 9b

Resection of the deviated part (Vertical strip, horizontal strip, crest, deviation and/or spur). **(Fig 10a&b)**

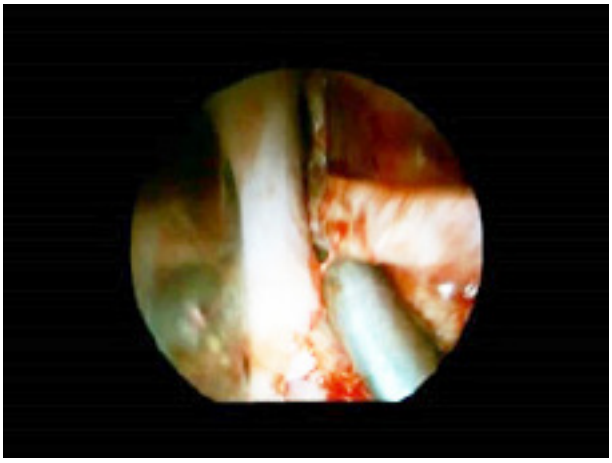

Fig 10a

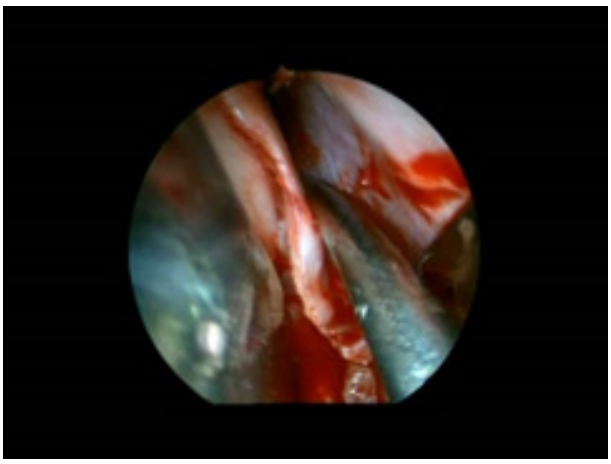

Fig 10b

Reconstruction with bone and/or cartilage is done. Mattress sutures across the septum (Transfixing sutures) are done. Finally the wound is closed **(Fig. 11)**.

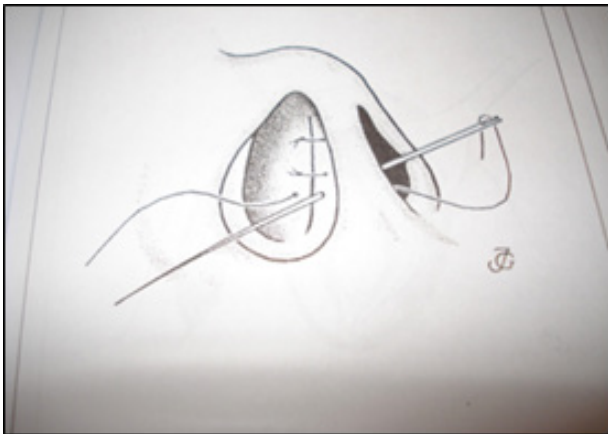

Fig 11

No packing. The patient is discharged in the same day (A day case). Follow up weekly in the first month and monthly for 6 months.

Results

One hundred patients of deviated nasal septum were admitted in the department of otorhinolaryngology, Ahmed Maher Teaching Hospital for endoscopic septal surgery from January 2010 to November 2012. Including cases of: dislocated caudal end 45 cases (45%) **(Figs. 12a,b)**, fracture septum 8 cases (8%) **(Fig. 13)**, vomeral spur 28 cases (28%) (Fig 14a, b, c, d & e) and basal crest 19 cases (19%) **(Fig. 15)**. In 33 patients endoscpic sinus surgery is done and rhinoplasty in 12 patients. Turbinoplasty is done in all cases. Male : female ratio was 3:1 and the age range was 10-48 years old with average age 23. Nasal obstruction was the commonest symptom, being found in 82 (82%) patients. The duration of presenting symptoms varied from 8 months to 8 years, with a mean duration of 22 months. All of these patients were treated medically before surgery with topical steroids sprays, mucolytic. Preoperative endoscopic nasal evaluation and CT scan were done. In all patients there were satisfactory subjective results with patent airway, improved fitness and reduced upper respiratory tract infection attacks as experienced by the patients. There was one case of septal hematoma (localized anterior and evacuated under local anaesthia). No cases of septal abscess, No perforation, No supratip depression, No synachia. Under correction occurred in 9 case and there were satisfaction by the patients and no over correction.

Fig 12a Pre-operative

Fig 12b Post-operative

Fig 13 Fracture septum

Fig 14a

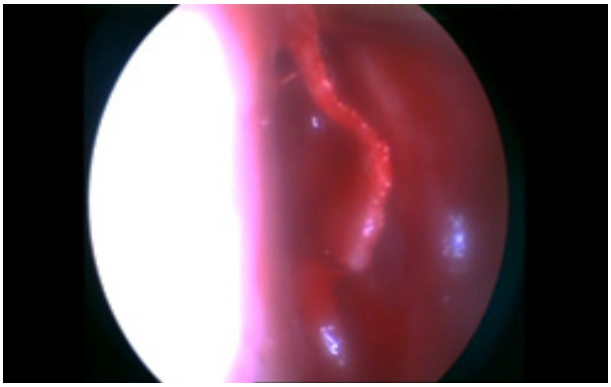

Fig 14b

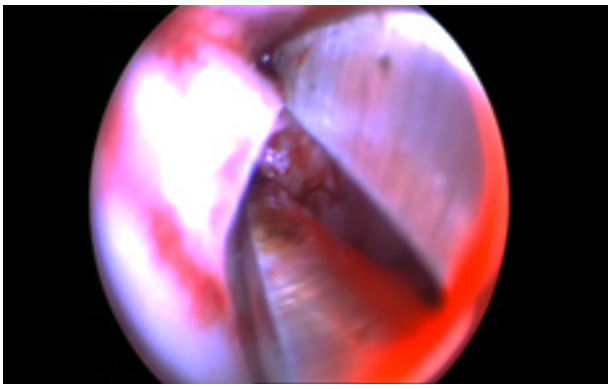

Fig 14c

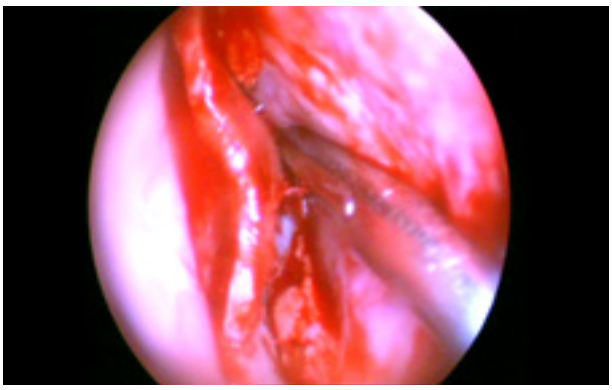

Fig 14d

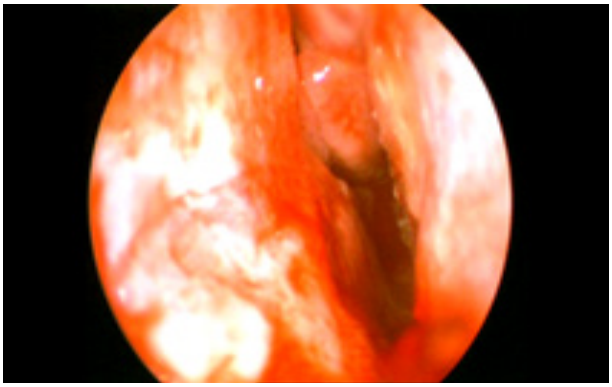

Fig 14e

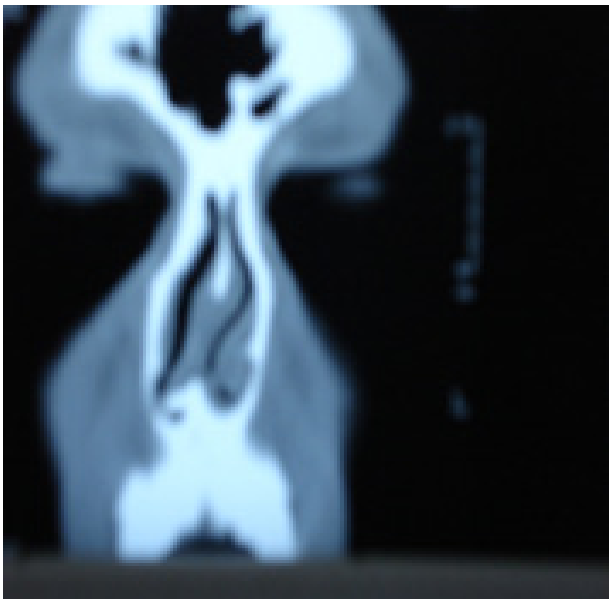

Fig 15

DISCUSSION

Septoplasty is one of the basic procedures in ENT practice. It is evolved in the last decades from total cartilage excision to classic septoplasty of Cottle. [1] The wide endoscopic practice and availability facilitate the idea of endoscopic septoplasty. All the previous authors do a limited septoplasty **(Figs. 16a,b,c)**.

Fig 16a

Fig 16b

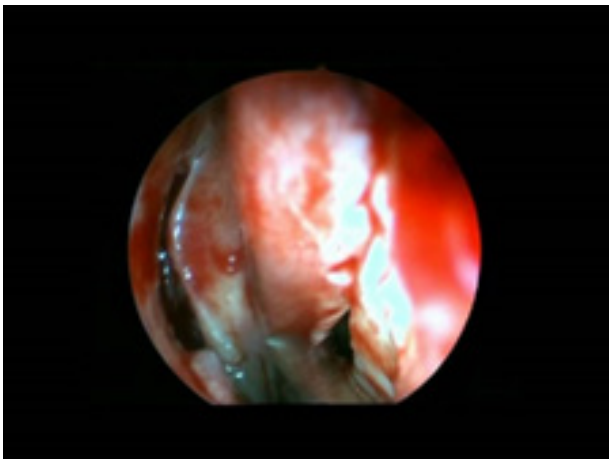

Fig 16c

Which is suitable to a localized deviation or a very small spur which is not the case in most situation. So we applied the endoscope to do basic Cottle endoscopically. **WHY?**

WHY NOT?

- High resolution
- Good illumination
- Zooming
- Very precise
- Minimal invasive
- Not time consuming

WHEN?

In all cases of septal pathology:

- Simple deviation
- Difficult cases
- Septal fracture
- Septal dislocation
- Limited (localized) deviation
- Revision septal surgery
- Septorhinoplasty
- With FESS
- Teaching
- Documentation

Septoplasty is one of the common operation performed in ENT theatre for relieving nasal airway obstruction, often in conjunction with other nasal and sinus procedures, such as aethitic rhinoplasty and functional endoscopic sinus surgery (FESS). The aim of our endocopic septoplasty is safe permanent correction of deviation without the need for exposing excessive bone and cartilage, thereby improving healing time and decreasing tissue trauma. In our study the improvement in nasal obstruction (Main symptom) is 96%, which comparable to traditional septoplasty 54%. [9] Also our complication was 1.8 % and complication rate by conventional septoplasty is 5% and limited endoscopic septoplasty is 2.08%. [5]

Conclusion

Endoscopic septoplsty is very safe & effective either alone or with other nasal operation. It improves illumination and accuracy. Also is very valuable and indispensable in teaching and documentation. Following the basics rules in simple as well as difficult cases is challenging.

References

1. Cottle MH, Loring RM, Fischer GG, Gaynon IE, et al. The maxila-premaxila approach to extensive nasal septum surgery. AMA Arch Otolaryngol. 1958;68:301-313.

2. Lanza DC, Rosin DF, Kennedy DW. Endoscopic septal spur resection. Am J Rhinol. 1993;7:213-216.

3. Stammberger H. Functional endoscopic sinus surgery. Philadelphia: B.C. Decker. 1991.

4. Siegel N, Glicklich R, Taghizadeh F, Chang Y. Outcomes of septoplasty. Otolaryngol Head Neck Surg. 2000;122:228-232.

5. Hwang PH, McLaughlin RB, Lanza DC, Kennedy DW. Endoscopic Septoplasty: Indications, technique and results. Otolaryngol Head Neck Surg. 1999;120:678-682.

6. Chung BJ, Batra PS, Citardi MJ, Lanza DC. Endoscopic septoplasty: revastation of the technique, indications and outcomes. Am J Rhinol. 2007;21:307-311.

7. Cantrell H. Limited Septoplasty for endoscopic sinus surgery. Otolaryngol Head Neck Surg. 1997;116:274-277.

8. Elsayed M, Abd El Baset A, Shokry A. Limited Endoscopic Septoplasty. Medical J. of Teaching Hospital And Institutes (GOTHIMED). 2005;65:43-50.

9. Sindwani R, Wright ED: Role of endoscopic septoplasty in the treatment of atypical facial pain. Journal of Otolaryngology. 2003;32:77-80.