Fess with septorhinoplasty do you agree? can we do?

Mohamed Elsayed

Department of ORL, Ahmed Maher Teaching Hospital, Egypt

E-mail: elsayed1960@hotmail.com

Pan Arab Journal of Rhinology
2017, 7:57-61

Introduction: Patients with cosmetic nasal aspects….may also have functional nasal complaint (obstruction…../ sinus problem).The advancement in the endoscopic sinus surgery FESS together with the in increase interest cosmetic surgery procedures including rhinoplasty; facilitate combination of the 2.

Methodology: Sixteen cases in a retrospective study; 12 female and 4 male, in a ratio 3:1. Their ages range between 17- 38 years, with a mean age 27.6.CTscan is peformed for all patients.Open septorhinoplasty with variable endoscopic sinus surgery stepsare performed under hypotensive general anaesthia.No pack is used. As day case.

Results: All the patients were satisfied with the aesthetic appearance. Fourteen (88%) of 16 patients stated that they would recommend the concurrent procedure.

Conclusion: Combined FESS with septorhinoplasty is effective and safe procsdure in selected patients. Our philosophy is to decrease operating times, healing times, as well as patient cost.We need more plastic surgeons trained in endoscopy to practice the combination surgery.

Pan Arab Journal of Rhinology 2017, 7:57-61

Introduction

Patients with cosmetic nasal aspects….may also have functional nasal complaint (Obstruction…../ sinus problem). Also many patients with functional nasal complaint may ask for cosmetic improvement. Can the rhinologist combine them together? (Rhinoplastic and sinus surgeon). Really nowadays, it the era of rhinology. The advancement in the endoscopic sinus surgery FESS: in the technique, instrumentation (Especially powered instrumentation), high-defination monitors and the revolution in anaesthia (Especially hypotensive anaesthia) have made FESS straight forward procedures in the hands of experts. The modern imaging techniques using computerized tomography (CT), have also upgrading therapy for all paranasal sinus surgery for inflammatory disease. Also the experts (Enthusiasm) who made FESS popular surgery. [1-3] All these items make functional endoscopic sinus surgery (FESS) to become the surgical modality of choice in the treatment of inflammatory sinus disease refractory to medical therapy. The skull-base surgeons dealing nowadays with FESS as a corridor for their territory. During the same interval, interest in cosmetic surgery procedures including rhinoplasty has exploded. These advances have made simultaneous procedure safe and efficacious in appropriately selected patients with sinus diseases. The increased use of antibiotics for chronic sinusitis at long time period has reduced potential risk for infection and complications. Although many surgeons combine the 2 procedures, there are few publications about effectiveness and complications of this combined procedure in the literature. [4] Our philosophyis to decrease operating times, healing times, as well as patient cost. [5]

Material and Methods

The authors has starting the combination of the 2 procedures since 2003 (After consulting professor **J. N. Trentee (President of Europian Society of Fecial Plastic Surgery) Who encourage the combination; if functional surgery and time allow to continue). We have started to combine function and aesthetic surgery since 2003 at Ahmed Maher Teaching Hospital. Earlier; in cooperation between plastic and otolaryngology divisions, later on, the author doing the cases alone. We reported here our cases from Januay 2013to December 2015. Sixteen cases in a retrospective study; (Using AIDA documentation system, Storz, Tutlingen), 12 female and 4 male, in a ratio 3:1. Their ages range between 17- 38 years, with a mean age 27.6 years. To establish a diagnosis and treatment plan; axial and coronal computed tomographic scanning without contrast **(Figs. 1a,2a,3a,4a)** and fiberscope with a 2.4-mm fiberscope were performed to evaluated the extent of functional and inflammatory abnormality: lower/ middle turbinate hypertrophy or pneumatization, septal deviation, obstruction of the osteomeatal complex, polyposis, or ethmoidal/ maxillary/ sphenoidal sinusitis and nasopharyngeal lymphoid hypertrophy. Then we evaluated desired aesthetic changes, including hump reduction, deviated nose correction, columellar show reduction, tip enhancement, and tip definition. All procedures were performed by the author under general anesthesia; with functional nasal and endoscopic sinus surgery performed first, followed by aesthetic surgery. Five millilitres of xylocaine 2% with 1:100,000 epinephrine was infiltrated into the different operative fields (e.g., septum, inferior, and middle turbinate) to enhance vasoconstriction. We did septoplasty and inferior turbinoplastyin all cases. Middle turbinoplasty in 13 cases (5 cases unilateral bullosa, 6 cases bilateral, 2 cases unilateral spongiosa). Six cases bilateral polypi, 2 cases pan sinusitis, 3 cases unilateral maxillary sinusitis, 2 cases anterior ehmoiditis. Hump reduction in all cases (4 cases by rasp, 12 cases by hump osteotomies), medial and lateral osteotomy in all cases, tip- plasty in all cases (Excision of cranial part of lower lateral cartilage, trans-domal, inter-domal sutures, collumellar-strut), Shield graft in 2 cases. Pre- and post-operative photographing **(Figs. 1b, 1c, 2b, 2c, 3b, 3c, 4b,4c)** and sinus surgery recording were done in all cases. Four cases were revision functional surgery. No packing. Septal stenting (In all cases) removed after 7 days, middle meatus spacer {(Merocele) (Bilateral in 6 cases, unilateral in 4 cases)}, removed after 3 days. All cases were a day case. Follow up range between 9 – 20 months; average: 11.6 months. No cases of active (Purlency) or fungal infection.

Results

We presented a total of 16 patients who underwent combined endoscopic sinus and rhinoplasty surgery from January, 2013, through December, 2015. The patients included 12 women and 4 men. Their age range 17- 38 years old (with a mean age 27.6 years). Patients reported a variety of primary symptoms, **(Table 1)**.

Table 1

Name of symptom	No .cases	Percentage
Nasal obstruction	16	100 %
Facial pain	10	62%
Post nasal drip	8	50%
Recurrent sinusitis	9	56%

The most common initial symptom was nasal obstruction or congestion (16/16 [100%]). In addition, 9 (56%) carried the diagnosis of chronic or recurrent sinusitis, facial pain or pressure (10/16 [62%]), postnasal drip, 8/16 [50%]). A review of all 16 patients' medical history; revealed that 4 (25%) had undergone previous functional nasal surgery. Preoperative medications included; short course oral steroid (8/16 [50%]), nasal steroids (12/16 [75%]), and antibiotics (10/16 [62%]). Examination (Including; endoscopy and CT examination) revealed a number of structural deficiencies in the 16 patients, **(Table 2).**

Table 2

Abnormality	Name of procedure	No. cases
Septal deformity	Septoplasty	16
Inferior turbinate	Inferior turninoplasty	16
Middle turbinate	Middle turbinoplasty	13
	Unilateral bullosa	5
	Bilateral bullosa	6
	Unilateral spongiosa	2

The most common was septal deformity and inferior turbinate hypertrophy (16/16 [100%]), middle turbinate in 13 patients (81%). Sinusitis included **(Table 3)**; bilateral nasal polypi in 6 patients, pansinusitis in 2 patients, unilateral maxillary sinusitisin 3 patients, unilateral anterior ethmoid sinusitis in 2 patients. All patients underwent open rhinoplasty with endoscopic sinus procedure.

Table 3

Name of disease	No. cases
Bilateral polypi	6
Pansinusitis	2
Unilateral maxillary sinusitis	3
Unilateral anterior ethmoid sinusitis	2

Adjunctive rhinoplasty procedures (Tables 4&5) included hump reduction all cases (12 cases by hump osteotome, 4 cases by rasping), medial and lateral osteotomies in all cases, tip-plasty (Excision of cranial part of lower lateral cartilage + trans-domal and inte-rdomal sutures + collumellar strut) in all cases, shield graft in 2 cases, over lay technique in 2 cases.

Table 4

Name of aesthetic problem	No. cases
Deviated nose	11
Hump	16
Distorted tip	16
Short nose	2

Table 5

Name of procedures	No. cases
Hump reduction	16
Hump osteotome	12
Hump rasping	4
Medial and lateral osteotomy	16
Tip plasty	16
Shield graft	2
Overlay of lower lateral cartilage	2

Patients had significant improvements in sinus symptoms and nasal breathing. Similarly, most sinus symptoms were resolved postoperatively. Fifteen patients (94%) reported overall improvement postoperatively. The mean operative time was 3 hours 12 minutes. There was no major intra- or post-operative complication. We observed 2 minor post-operative complications, including; synchia between middle turbinate and lateral nasal wall, requiring cutting the adhesion under local anaesthia. All the patients were satisfied with the aesthetic appearance. Fourteen (88%) of 16 patients stated that they would recommend the concurrent procedure.

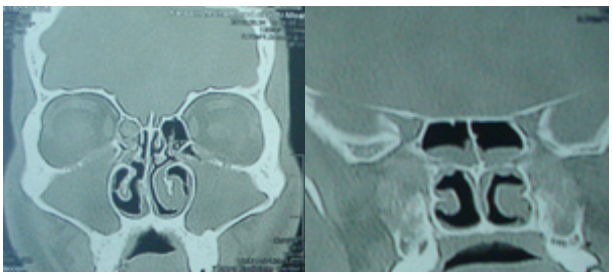

Fig1a Preoperative CT case 1

Fig1b Pre-operative case 1

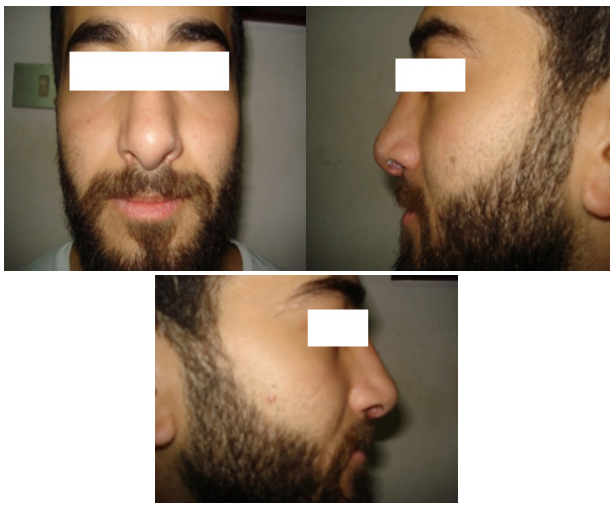

Fig1c Post-operative case 1

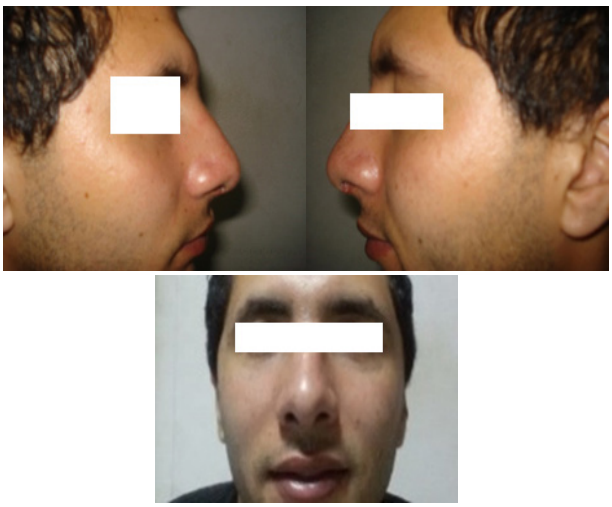

Fig 2c Post-operative case 2

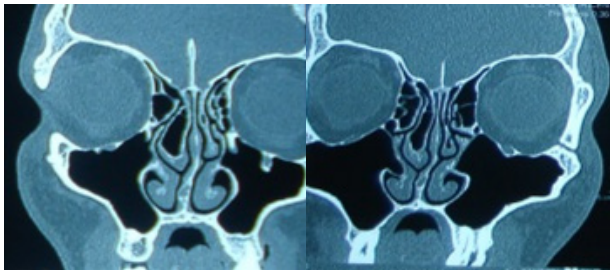

Fig 2a Pre-operative CT case 2

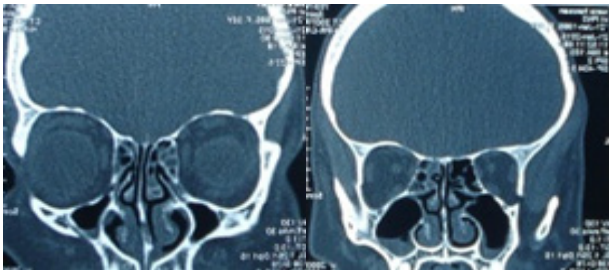

Fig3a Pre-operative CT case 3

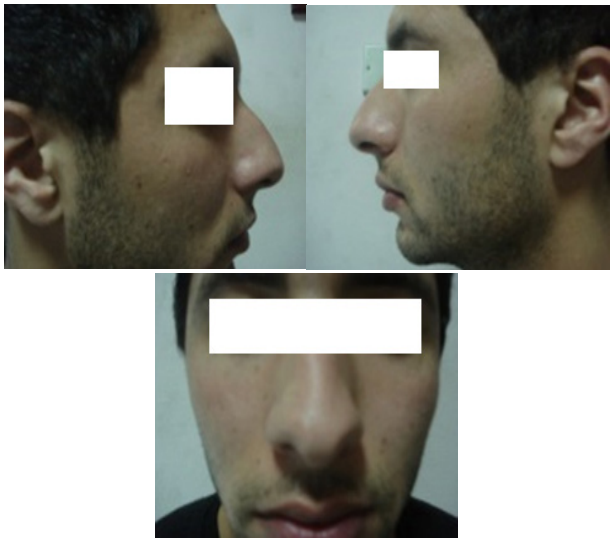

Fig 2b Pre-operative case 2

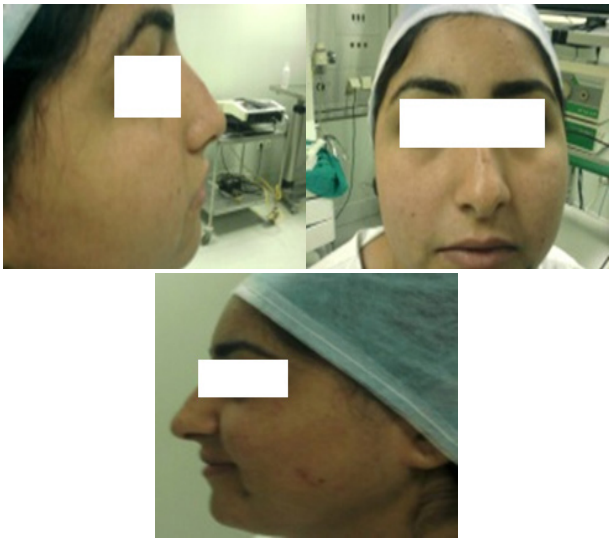

Fig 3b Pre-operative case 3

Fig 3c: Post-operative case 3

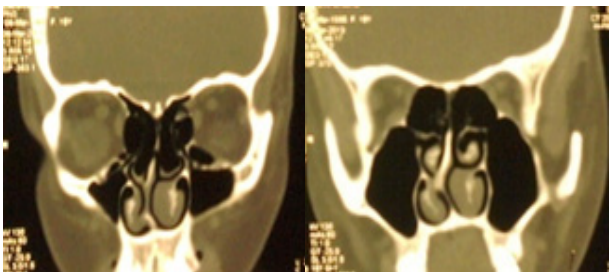

Fig 4a Preoperative CT case 4

Fig 4b: Pre-operative case 4

Fig 4c: Post-operative case 4

Discussion

With the advancement and stability in the basic endoscopic sinus surgery [1-3] and modern imaging, we can summarize it as 6 basic steps:

1. Uncinectomy
2. Middle meatal antrostomy
3. Anterior ethmoidectomy
4. Frontal osteotomy
5. Posterior ethmoidectomy
6. Sphenoidotomy

Simply, we are using some steps (Rarely all) in FESS. The same applied in modern rhinoplasty surgery; as we have common porocedures applied in most cases:

- Reduction of the dorsum (Hump reduction)
- Medial and lateral osteotomy
- Tip plasty (By applying set of steps): excision of cranial part of lower lateral cartilage+trans-domal and inter-domal sutures+collumellar strut). In addition to occasional steps like shield graft, overlay technique, augmentation and others. By understanding and applying this philosophy, we can simplify the combination of the two procedures. Not only this but also we can save time, ensure safety and improving the results. Combination of endoscopic sinus surgery with rhinoplasty was first reported by Shemenand Matarasso. [6] This study documented eight concurrent cases without complications. Toffel reported 122 combined surgeries performed between 1986 and 1992. [7] Individually endoscopic sinus surgery and rhinoplasty are effective procedures with minimal risk of complications. Since then many authors have reported large studies illustrating the overall safety and efficacy of combining the two procedures. [4,5,8,11,14] Functional endoscopic sinus surgery, introduced in the 1970s, [9] today; it represents the treatment of choice in this field and can be readily combined with aesthetic rhinoplasty. [6-10] Ricardo and Giovanni introduced the term; functional endoscopic nasal surgery for management of the septum and lower and middle turbinates endoscopicaly, in conjunction with FESS and rhinoplasty. [11] Offering a magnified view of the operative field, it allows a more precise correction of septal deviation and permits partial resections of lower/middle turbinates with identification of precise focal abnormality, avoiding both the significant intr- & post-operative hemorrhage of traditional surgery and the prolonged packing that traditionally accompanied it. [12] They avoid nasal packing in most cases producing good functional outcomes with

negligible discomfort and patient morbidity and without any compromise of the aesthetic result. [12] They encourage the plastic surgeon trained in endoscopy to practice the combination surgery. Avoiding the concurrent treatment in the presence of severe sinusitis results in safe and effective procedures. [5] Major complication of FESS are rare (1.1%) and rate of minor complication of 5.4%. [1] The overall complication (Very minor) rate in our study group (12.5%) was within the range of complication rates reported in the literature for either FESS or rhinoplasty performed alone (1%-21%). [13] When FESS and rhinoplasty are combined, neither the risk profile nor the complication rate of the procedures changes substantially. [13] In prior studies, the rhinoplasty technique used was a closed approach, whereas the recent studies use the open approach, [13] Some authors prefer a 2-team approach to allow maximum efficiency for the operative surgeons and improves access to surgical care for the patients. [11,14] On average, an endoscopic sinus procedure is about 150 minutes long. The duration of a rhinoplasty is quite variable, but it ranges from 1to 3 hours depending on case complexity. [15] The combined procedures in our study had a mean length of 192 minutes. Although this constitutes a relatively lengthy single procedure, it is less actual operative time than the combined mean of the separate procedures. Combined with the benefits of use of a single anesthetic and a single recovery period, we believe that the concurrent procedure provides a clear advantage. [14] With any elective surgery, patient satisfaction is the ultimate measure of a procedure's success. [14] In our study (88%) of the patients stated that they were happy with their procedure and would recommend a concurrent sinus and rhinoplasty procedure.

Conclusion

Combined FESS with septorhinoplasty is effective and safe procedures in selected patients. Our philosophy is to decrease operating times, healing times, as well as patient cost. We need more plastic surgeons trained in endoscopy to practice the combination surgery.

References

1. Levine HL, May M. Endoscopic sinus surgery. New York: Thieme Medical Publishers. 1993.

2. Stammberger, H. Functional Endoscopic Sinus Surgery: The Messer klinger Technique. Philadelphia: Dekker. 1991:432-433.

3. Kennedy, D. W. Functional endoscopic sinus surgery: Technique. Arch. Otolaryngol. 1985;11:643.

4. Lnanli S , Sari M , and Yazici M.Z., "The results of concurrent functional endoscopic sinus surgery and rhinoplasty," J Craniofacial Surgery. 19;3:701-704.

5. Millman B, Smith R. The potential pitfalls of concurrent rhinoplasty and endoscopic sinus surgery. Laryngoscope. 2002;112:1193-1196.

6. Shemen L, Matarasso A. Combined endoscopic sinus surgery and aesthetic rhinoplasty: a pilot study. Am J Rhinol. 1991;5:131-135.

7. Toffel PH. Simultaneous secure endoscopic sinus surgery and rhinoplasty. Ear Nose Throat J. 1994;73:554–573.

8. Rizk SS, Edelstein DR, Matarasso A. Concurrent functional endoscopic sinus surgery and rhinoplasty. Ann Plast Surg. 1997;38:323–329.

9. Messer klinger, W. Die Endoskopie der Nase. Monatsschr. Ohrenheilkd. Laryngol. Rhinol. 1970;104:451.

10. Park, D. H., Lee, J. W., Song, C. H., Han, D. G., and Ahn, K. Y. Endoscopic application in aesthetic and reconstructive facial bone surgery. Plast. Reconstr. Surg. 1998;102:1199.

11. Mazzola R. F. and Felisati G. "Rhinoplasty and endoscopic surgery for functional and inflammatory nasal/sinus disorders," Plastic and Reconstr. Surgery. 2005;115:705–710.

12. Guyuron, B. Is packing after septorhinoplasty necessary? A randomized study. Plast. Reconstr. Surg. 1989;84:41.

13. Lee J. H. Sherris D. A. and Moore E. J. Combined open septorhinoplasty and sinus surgery. Otolaryngology. 2005;133:436–440.

14. Marcus B. Patel Z. Busquets J. Hwang, P. H. and Cook T. A. "The utility of concurrent rhinoplasty and sinus surgery: a 2-team approach," Archives of Facial Plastic Surgery. 2006;8:260–262.

15. Fried MP, Moharir VM, Shin J, Taylor-Becker M, Morrison P. Comparison of endoscopic sinus surgery with and without image guidance. Am J Rhinol. 2002;16:193-197.