

Endoscopic management of pediatric allergic fungal sinusitis, case series and prognostic parameters evaluation

Hesham Mohammad Eladl, Basem Ashraf Wahba, Yasser Wafik Khafagy

Department of ORL, Mansoura University, Egypt

Corresponding to Hesham Mohamed Eladl
Department of ORL, Mansoura University, Egypt
E-mail: heshameladl@mans.edu.eg

Pan Arab Journal of Rhinology
2017, 7:35-40

Objective: To evaluate the endoscopic management of pediatric allergic fungal sinusitis as regard management protocol, and some predictive factors for prognosis of AFS as (vitamin D3 level, IgE level, orbital extension, and patient age).

Patients and methods: A prospective study was done on patients of pediatric age group presenting with allergic fungal sinusitis (AFS) in the period from March 2012 to January 2017, Ten pediatric patients were included in this study. 7 male and 3 female, their age ranged from 8 years to 16 years (13.6).

Results: postoperative evaluation showed resolution of nasal and orbital manifestations, gradual resolution of proptosis and periorbital oedema occurred in all patients, No major postoperative complications were encountered, The post-operative follow up period ranged between 14 months and 58 months (32.2 months in average), Recurrence occurred in 3 cases without orbital manifestations.

Conclusions: Endoscopic management of pediatric AFS was effective and safe technique with improvement of all nasal and orbital manifestations post operatively, Management of each case of AFS should be individually tailored according to clinical, radiological and operative findings, Severe disease form is highly regarded in pediatric AFS due to delicate anatomy with difficulty in management and follow up, Many prognostic parameters could be used in pediatric AFS as vitamin D3 and IgE level; however other researches with larger study group are required.

Keywords: Endoscopic surgery, fungal, allergic, mucin, sinus, pediatric endoscopic surgery.

Pan Arab Journal of Rhinology 2017, 7:35-40

Introduction

Allergic fungal rhinosinusitis (AFRS) is a type I hypersensitivity reaction to fungal antigens in which patients usually present with unilateral or bilateral nasal polyps. [1] AFRS was firstly described as a separate clinical term in 1976. [2] Presentation in pediatric patients with allergic fungal sinusitis is different from that in adults, with children having obvious abnormalities of their facial skeleton, unilateral sinus disease, and asymmetrical disease more often. [3] The clinical characteristics of 40 children suffering from allergic paranasal aspergillosis were marked facial deformity, orbital involvement (52.5%) and skull base erosion (12.5%). [4] Vitamin D3 is a steroid hormone that regulates bone health and numerous aspects of immune function and may play a role in respiratory health. Vitamin D3 deficiencies in (AFRS), resulting in increased mature dendritic cells and bone erosion. [5] Endoscopic surgical debridement and drainage combined with topical steroids leads to resolution of disease in the majority of cases. [6]

Material and Methods

A prospective study was done on patients of pediatric age group presenting with allergic fungal sinusitis (AFRS), The study was held in Otorhinolaryngology department, Mansoura University hospital (Egypt) and Elrafeef Mecca hospital (KSA) from March 2012 to January 2017, Ten pediatric patients with AFRS were included in this study, Seven male and 3 female, their age ranged from 8 years to 16 years (13.6 in average), The study was held after approval of institutional review board, all parents gave their informed consent prior to inclusion in the study. Inclusion criteria of this study is pediatric patient (≤ 16 years) with AFRS that

is proved clinically (preoperative and operative evaluation), radiologically (CT), histopathologically (tissue and mucin examination), and immunologically (eosinophilia and serum IgE), Studies were done to evaluate some predictive factors for prognosis of AFRS as (vitamin D3 level, IgE level, orbital extension, and patient age).

Pre-operative symptoms

In all patients case history was taken, the most common presenting symptoms were nasal obstruction and thick, highly viscous greenish yellow nasal discharge in all patients, facial headache in 7 patients, post nasal drip in 5 patients. On the other hand, orbital manifestations were detected in the form of blurred vision with periorbital swelling in 8 patients, proptosis in 3 patients, and swelling at the medial canthus in 2 patients. No visual loss was encountered in orbital manifestations of this study group.

Pre-operative Examination

All patients had undergone clinical examination, endoscopic examination, CT examination for all patients (**Figs. 1-3**), Also, ophthalmological consultation was done for all cases, Ten cases were included in our study, Patients' age at the time of treatment, sex, the extension of the disease, orbital manifestations, IgE level, vitamin D3 in blood, and follow-up periods are shown in **Table 1**. Postoperative follow up included clinical examination on regular visits, second look endoscopy, the presence or absence of postoperative complications or recurrence, and post-operative CT paranasal sinus from 2 to 6 months postoperatively, The post-operative follow up period ranged between 14 months and 58 months (32.2 months in average).

Intervention

Endoscopic surgical procedure was performed under general anesthesia in all cases, The nose was prepared with 1/100.000 adrenaline for local haemostasis. A 4 mm endoscope was used; the surgical landmarks had to be clearly identified. Although minimal invasive sinus surgery is recommended in pediatric population, wide middle meatal antrostomy with complete ethmoidectomy was done for all patients to help orbital decompression, avoid recurrence, allow good drainage and help post operative debridement, The lamina papyracea erosion was found in 6 cases, Bilateral AFRS was found in 2 cases (20%), Erosion of posterior maxillary wall was found in one case. Complete Endoscopic dissection of AFRS polyps and muddy dense discharge was done (**Fig. 4**). Endoscopic sinus surgery was done through wide middle meatal antrostomy, anterior and posterior ethmoidectomy, frontal recess clearance and sphenoidotomy, Care was taken to not injure the teeth root, lamina papyracea or skull base, Removal of right posterior maxillary wall was done in one case; in this case severe fungal extension lead to

bone resorbtion and necrosis that the bone removed without bleeding in one piece (similar to invasive fungal sinusitis) with obvious maxillary artery pulsation in ptrygopalatine fossa, Minimal submucosal cautery of inferior turbinate was done in all patients; septoplasty was done in 3 patients to wide surgical field and help post operative assessment and drainage, Histopathological examination was done for all patients showed hyperplastic mucosa with inflammatory eosinophils, lymphocytes, and plasma cells infiltration without invasion into surrounding structures, Also, mucin showed clusters of eosinophil, with Charcot-Leyden crystals and non invasive fungi, Post-operatively routine packing was done, All patients were prescribed alkaline nasal douches, Oxymetazoline hydrochloride spray together with antibiotics for 2-4 weeks, All patients use topical steroid with gradual tapering from 8 till 2 puffs on daily use for life, Oral steroid was given for short period post operatively from 4 to 12 weeks according to severity of AFRS with gradual tapering. Patients were instructed to avoid nasal blowing for 2-3 weeks to decrease post endoscopic surgical emphysema.

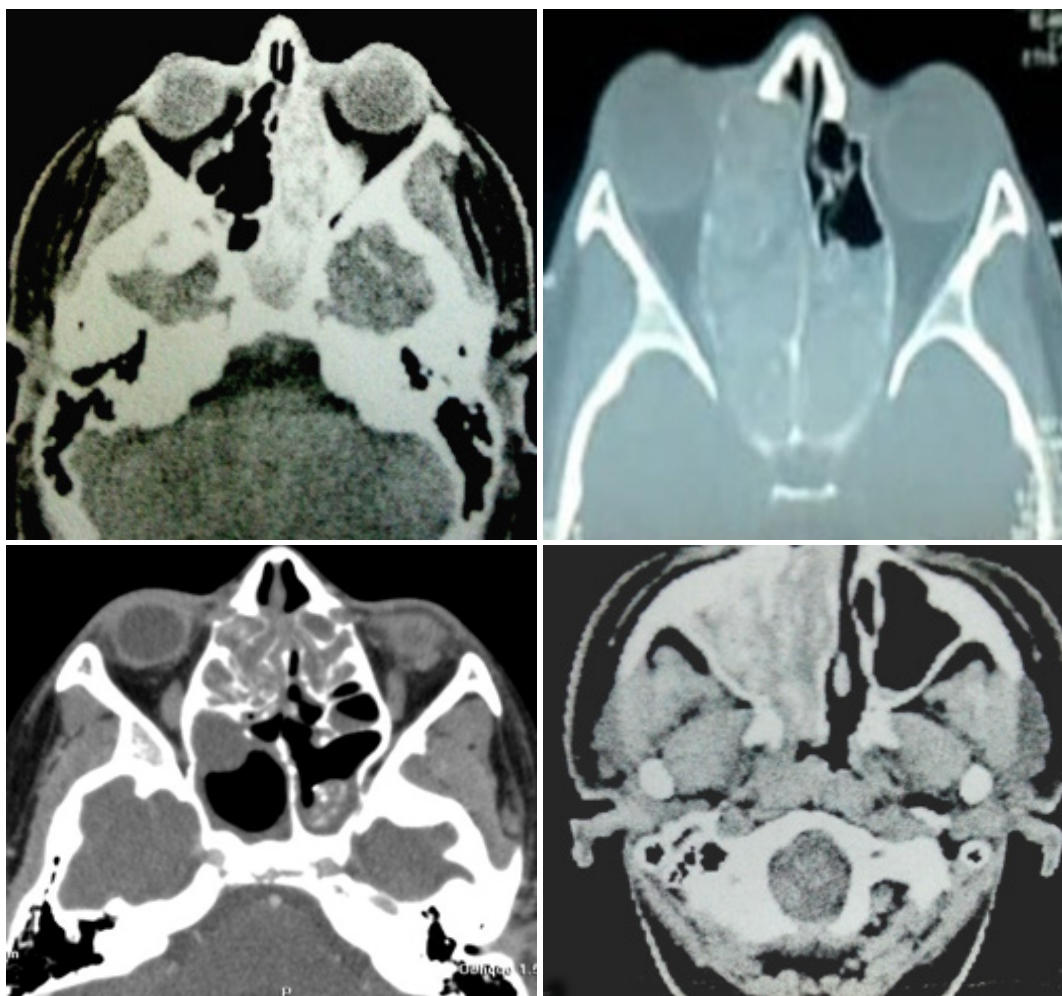


Fig 1 preoperative axial CT showing AFS

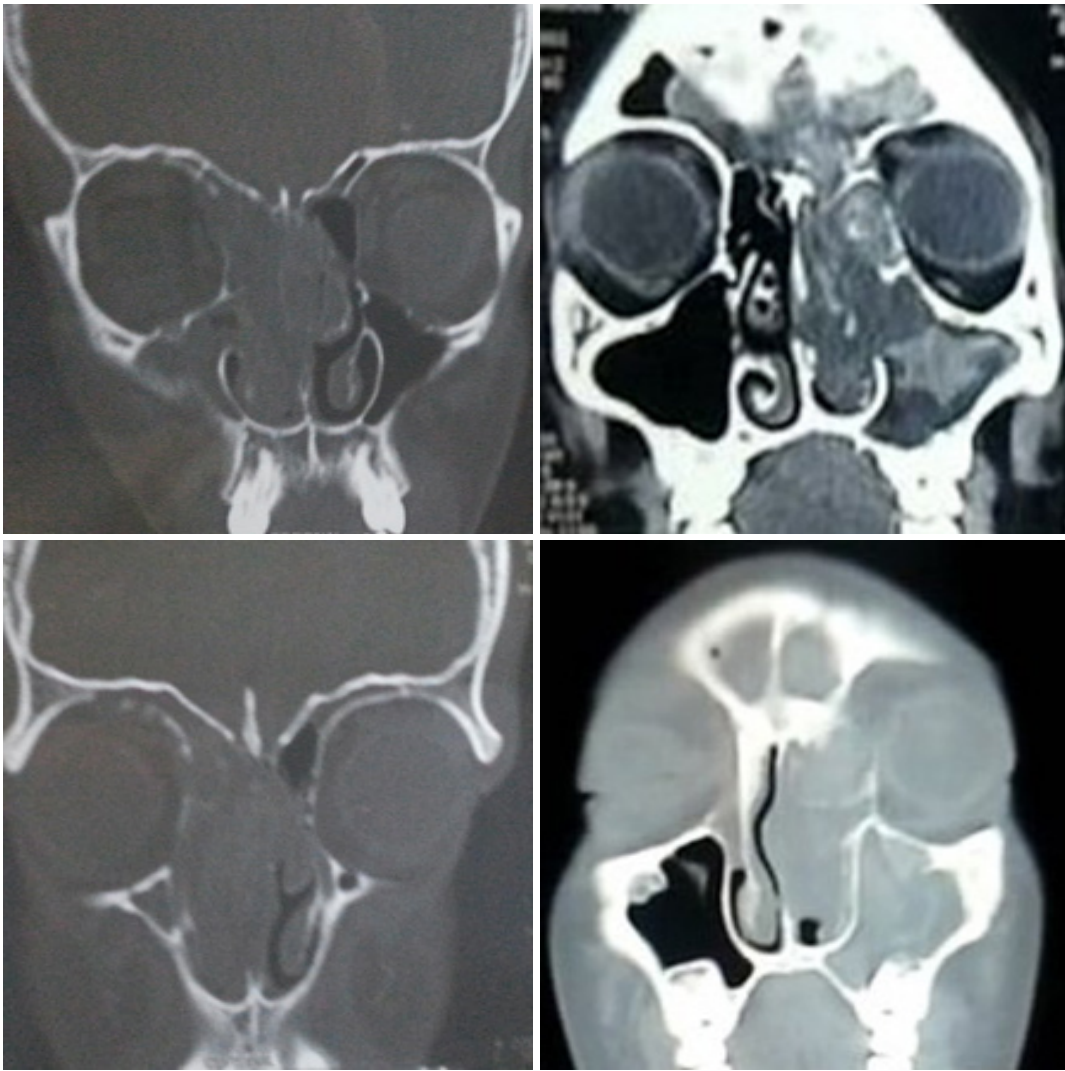


Fig 2 preoperative coronal CT showing AFS

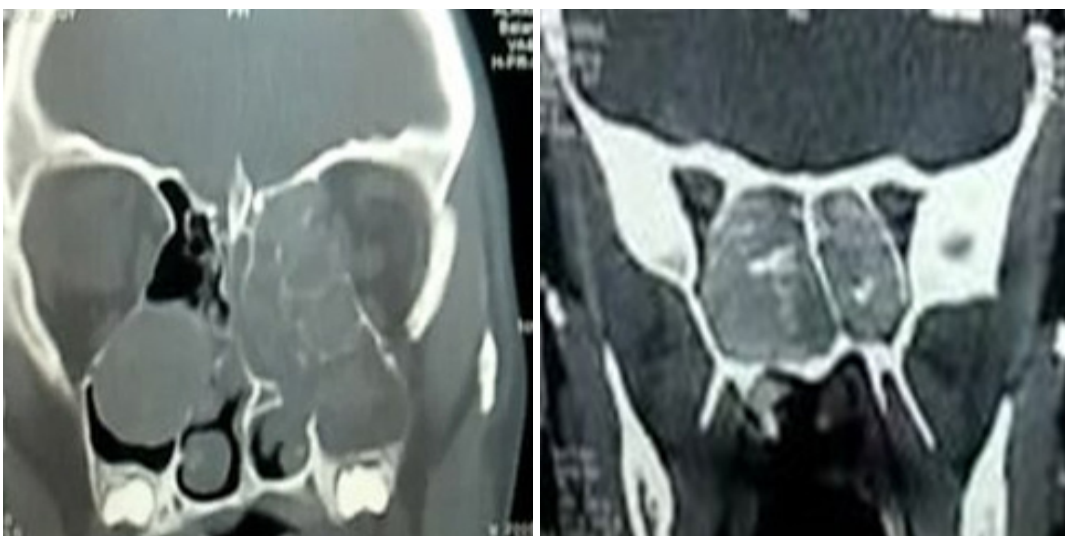


Fig 3 Preoperative coronal CT showing bilateral AFS

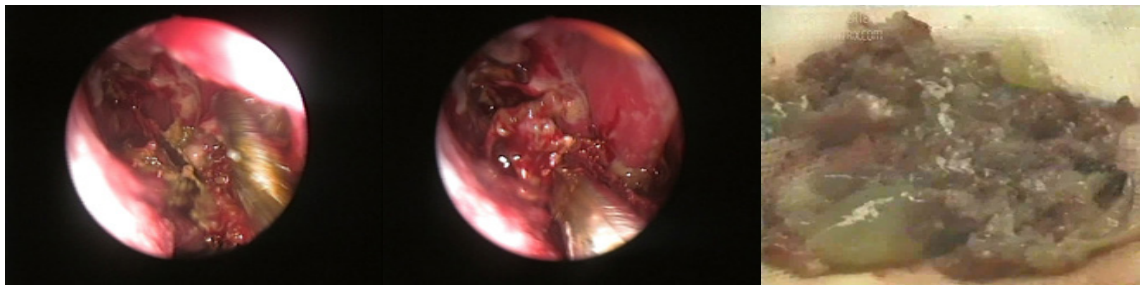


Fig 4 AFRS polyps and muddy discharge

Table 1 Variables in the case series

N	Age (years)	Sex	Side of orbital invasion	Extension	Orbital manifestation	IGE level IU/mL	Vitamin D3 ng/mL	Recurrence	Follow up period (months)
1	14	M	Right	Maxillary Ethmoidal	Periorbital swelling	824	12		58
2	8	M	Left	Bilateral Ethmoidal maxillary sphenoidal frontal	Periorbital swelling proptosis	1214	8	+	48
3	16	F	Left	Maxillary ethmoidal frontal		728	6		42
4	12	M	Right	Maxillary ethmoidal	Periorbital swelling, proptosis	689	18		34
5	16	M	Right	Maxillary ethmoidal frontal	Periorbital swelling, medial canthal swelling	980	12	+	30
6	14	F	Left	Maxillary ethmoidal sphenoidal		678	28		28
7	15	M	Right	Bilateral Maxillary ethmoidal sphenoidal	Periorbital swelling, proptosis	1130	32		27
8	16	M	Right	Maxillary ethmoidal	Periorbital swelling	788	16		27
9	13	F	Right	Ethmoidal maxillary frontal	Periorbital swelling, medial canthal swelling	540	24		18
10	12	M	Left	Ethmoidal maxillary		880	13	+	14
						13.6	845.1	16.9	32.2

Results

All patients have improved on both subjective and objective assessments.

Subjective assessment

All patients showed resolution of nasal obstruction and post nasal discharge. Facial pain show complete disappearance

in 6 cases, mild facial pain was encountered in 4 patients postoperatively with gradual improvement. As regard orbital manifestations, gradual resolution of proptosis and periorbital oedema occurred in all patients. No major postoperative complications in the form of orbital or brain injury or CSF leakage were encountered.

Objective assessment

Nasal examination showed minimal crustations, and granulations which relieved with medical treatment. Also, endoscopic evaluations (under local anesthesia) were done for all cases showing wide middle meatal antrostomy with clean healed maxillary and ethmoid sinus cavities, recurrence was detected during follow up in 3 patients. Visual examination was done postoperatively with improvement for all cases. Post operative CT evaluation revealed significant improvement on comparison to preoperative CT in all patients. Recurrence occurred in 3 cases without orbital manifestations (**Fig. 5**), and revision endoscopic sinus surgery was done for debridement and cleaning.

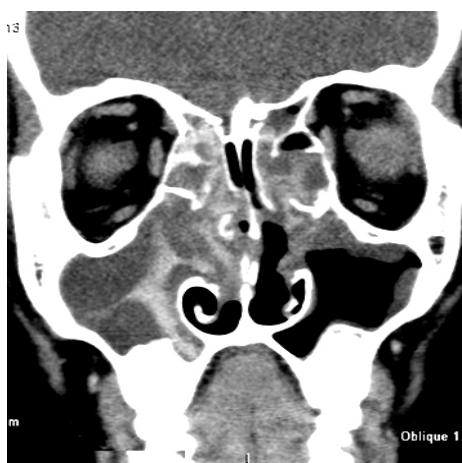


Fig 5 postoperative coronal CT showing recurrent AFS without orbital manifestation

Discussion

AFRS diagnosis is based on radiological, histological, and immunological criteria of the disease, [7] Ferguson stated that the simplest and most straight-forward requirement for defining patients as having AFRS is the presence of eosinophilic mucin with hyphae, [8] In this study diagnosis of AFRS is proved clinically (preoperative and operative evaluation), radiologically (CT), histopathologically (tissue and mucin examination), and immunologically (eosinophilia and increase serum IgE), Nevertheless, surgical findings with the characteristic appearance of the fungal muddy discharge and polyps are important issue in the diagnosis of AFRS, its extension and severity, Fungal culture and serology are used as supportive in diagnosis. Another study showed that aspergillus serology was positive in 35% and fungal culture grew the organism in 40%, [4] Previous study referred pediatric AFRS to adolescents and young adults (study average was 21.9 years), Also, the study concluded that climatic factors affect the incidence of AFRS, [3] In this study the patient's age ranged from 8 years to 16 years (13.6 in average), Wide spread of AFRS in hot weather could increase the incidence of pediatric age group affection, Many children complained of protracted nasal obstruction with dark discharge from the nose, [9] In this study all patient had nasal obstruction and greenish dark thick nasal discharge, Orbital manifestations were detected in 8 patients (80%) in the form of periorbital swelling in 8 patients, proptosis in 3 patients, and swelling at the medial canthus in 2 patients, Bilateral disease affected 2 patients, Six patients showed orbital invasion with erosion of lamina papyracea clinically and radiologically.

In this study, vitamin D3 level was lower than normal average (16.9 ng/mL in average), Nevertheless, in the recurrent cases (3 cases) vitamin D3 level was even below the study average, Thus, vitamin D3 lower level could increase AFRS orbital extension and recurrence incidence, However, larger

study group is necessary to certificate this relation, Other study concluded that vitamin D3 deficiency in pediatric AFRS could be attributed to higher dendritic cell infiltration in the tissue, [10] and associated with more severe bone erosion, [5] Kuhn and Javer found that total IgE is important factor in predicting persistence or recurrence in AFRS, [11] Ferguson in his study found a high level of IgE in AFRS (668 IU/mL in average), [12] In other study, the mean IgE level was 820.2 IU/mL for AFRS, [13] Moreover, total IgE was correlated significantly with the disease severity, and 10% increase or more in total serum IgE during follow-up period was important predictor of recurrence and the need for revision surgery, [14] In this study IgE level was higher in all patients (845.1 IU/mL average), In the 3 recurrent cases the IgE level was even above this average (1214, 980, and 880), However a more detailed study with a larger group is needed to prove this correlation, Markers of disease severity (bone erosion, orbitocranial involvement and recurrence) in AFRS were associated with lower income, rural counties, poor housing quality, and less health care access, [15] However, in other study no socioeconomic factors were identified that correlated with the incidence of bone erosion in patients diagnosed with AFRS, [16] In this study we can't find specific relation between socioeconomic factors and AFRS severity and bone erosion.

A study defined termination of nasofacial growth has as 14.7 years for boys and 13.4 years for girls, [17] In this study the pediatric age is considered below 16 to include patients in adolescent, and school age (13.6 in average), In AFRS, skull base and orbital erosion are seen in one-third of casesm Orbital erosion is 1.5 times more common than skull base erosion, [3] Local bony involvement is 10 times more common in AFRS than in other forms of chronic rhinosinusitis (CRS), [7] Significantly decreased orbital volumes (to approximately 70% of normal) have been noted to return to 90% of normal after successful management, [18] In this study ethmoid sinus was affected in all patients with intraorbital invasion in 8 patients (80%), All orbital manifestations improved post operatively without recurrence, Invasion was more due to expansion of AFRS mucin rather than a destructive process, However, in one case posterior right maxillary wall necrosis resembling invasive fungal sinusitis but pathology didn't reveal fungal invasion with good prognosis and postoperative improvement for, This could add to the debate about fungal sinusitis classification and the need to evolve this from separate titles into a spectrum with interdissecting forms of the disease, Also, management of each case of AFRS should be individually tailored according to clinical, radiological and operative findings, High incidence of recurrence is always regarded in AFRS especially in pediatric age group due to difficulty in management and follow up, Researches shows variability in the recurrence rate which could attribute to difference in sample size, follow up period and management protocol, In other study, six of 11 patients (54.5%) with AFRS showed recurrence within one year, [13] Other studies showed 15% recurrence rate, [4] and 44% recurrence rate, [19] In this study, from 10 patients having pediatric AFRS with intraorbital extension only 3 patients showed recurrence (30%) without orbital manifestations, According to these results age and intraorbital extension didn't have much impact on AFRS recurrence, Although no apparent impact on AFRS recurrence by age could be defined, a more severe form of AFRS is regarded in pediatric age group due to delicate anatomy and difficulty in management and follow up.

A standardized protocol for the treatment of AFRS has not yet evolved, Most AFRS protocols include combined surgery with steroid (locally and or systemic) with close follow up, In this study, all patients received oral steroid post operatively from 4 to 12 weeks according to AFRS severity. Oral steroid therapy benefits include increased cure rates and clinically milder disease among those in whom disease recurred, increased time to revision surgery, reduction in mucosal stage of disease, and reduced systemic IgE levels, [1] Classical surgery has been aggressive, with radical removal of mucosa and frequent external approaches, The strategy has evolved to incorporate endoscopic tissue-sparing techniques described as conservative but complete, [15] Surgery should remove obstruction and allow natural drainage patterns with complete removal of all mucin and debris to eliminate the antigenic-iciting factor. In addition, postoperative access must be kept in mind to allow for examination in the clinic and diagnosis of recurrence, However, the physical characteristics of AFRS have significant implications on endoscopic sinus surgery due to slow accumulation of allergic fungal mucin and associated bony decalcification which mimic invasion and result in the loss of normal bony landmarks, placing vital structures at risk, [9] Nevertheless, in a growing child care should be taken for the unique position of the skull base, anterior ethmoids and orbital lamina, [20] Hence, endoscopic sinus surgery in pediatric AFRS, considered uneasy job due to the delicate inconstant anatomy which hinder the procedure and limits postoperative follow up of the surgical field.

Conclusion

Endoscopic management of pediatric AFRS was effective and safe technique with improvement of all nasal and orbital manifestations post operatively, Management of each case of AFRS should be individually tailored according to clinical, radiological and operative findings, Severe disease forms are highly regarded in pediatric AFRS due to delicate anatomy with the difficulty in management and follow up, Many prognostic parameters could be used in pediatric AFRS as vitamin D3 and IgE level; however other detailed researches with a larger study group are required.

References

- Ryan MW, Marple BF. Allergic fungal rhinosinusitis: diagnosis and management. *Curr Opin Otolaryngol Head Neck Surg.* 2007;15:18–22.
- Safirstein B. Allergic bronchopulmonary aspergillosis with obstruction of the upper respiratory tract. *Chest.* 1976;70:788–790.
- McClay JE, Marple B, Kapadia L, Biavati MJ, Nussenbaum B, Newcomer M, Manning S, Booth T, Schwade N. Clinical presentation of AFRS in children. *Laryngoscope.* 2002;112:565-9.
- Gupta AK, Ghosh S, Gupta AK. Sinonasal aspergillosis in immunocompetent Indian children: an eight-year experience. *Mycoses.* 2003;46:455-61.
- Mulligan JK, Bleier BS, O'Connell B, Mulligan RM, Wagner C, Schlosser RJ. Vitamin D3 correlates inversely with systemic dendritic cell numbers and bone erosion in chronic rhinosinusitis with nasal polyps and allergic fungal rhinosinusitis. *Clin Exp Immunol.* 2011;164:312-20.
- Marfani MS, Jawaid MA, Shaikh SM, Thaheem K. Allergic fungal rhinosinusitis with skull base and orbital erosion. *J Laryngol Otol.* 2010;124:161-5.
- Bent JP, Kuhn FA. Diagnosis of AFRS. *Otolaryngol Head Neck Surg.* 1994;111:580–588.
- Ferguson BJ. The diagnosis of AFRS. Sinus surgery, endoscopic and microscopic approaches. *Leviene HL, editor. Thieme Medical;* 2005:290–299.
- Marple BF. Allergic fungal rhinosinusitis: current theories and management strategies. *Laryngoscope.* 2001;111:1006-19.
- Mulligan JK, White DR, Wang EW, Sansoni SR, Moses H, Yawn RJ, Wagner C, Casey SE, Mulligan RM, Schlosser RJ. Vitamin D3 deficiency increases sinus mucosa dendritic cells in pediatric chronic rhinosinusitis with nasal polyps. *Otolaryngol Head Neck Surg.* 2012;147:773-81.
- Kuhn FA, Javer A. Utilizing fungal specific IgE levels as a serological marker for AFRS activity. *Am Rhinologic Soc Spring Meet.* 1999.
- Ferguson BJ. Eosinophilic mucin rhinosinusitis: a distinctive clinicopathological entity. *Laryngoscope.* 2000;110:799–813.
- Laila M. Telmesani. Prevalence of AFRS among patients with nasal polyps. *Ann Saudi Med.* 2009;29:212–214.
- Schubert MS. AFRS: pathogenesis and management strategies. *Drugs.* 2004;64:363–374.
- Miller JD, Deal AM, McKinney KA, McClurg SW, Rodriguez KD, Thorp BD, Senior BA, Zanation AM, Ebert CS Jr. Markers of disease severity and socioeconomic factors in allergic fungal rhinosinusitis. *Int Forum Allergy Rhinol.* 2014;4:272-9.
- Ghegan MD, Wise SK, Gorham E, Schlosser RJ. Socioeconomic factors in allergic fungal rhinosinusitis with bone erosion. *Am J Rhinol.* 2007;21:560-3.
- Huizing EH. Septum surgery in children; indications, surgical technique and long-term results. *Rhinology.* 1979;17:91–100.
- Campbell JM, Graham M, Gray HC, Bower C, Blaiss MS, Jones SM. AFRS in children. *Ann Allergy Asthma Immunol.* 2006;96:286–290.
- Al-Swiahb JN1, Al-Ammar A, Al-Dousary SH. AFRS in children in Saudi Arabia. *Saudi Med J.* 2007;28:1711-4.
- Verwoerd CD, Verwoerd-Verhoef HL. Rhinosurgery in children: developmental and surgical aspects of the growing nose. *GMS Curr Top Otorhinolaryngol Head Neck Surg.* 2010;9:Doc05.