

# Pleomorphic adenoma of the nasal septum: a case report and review of the literature

Ali Al Momen\*, Abdulrahman Al Khatib

Department of ENT, King Fahad Specialist Hospital, Dammam, MOH, Saudi Arabia

\*Correspondence to Ali Al Momen, Department of ENT, King Fahad Specialist Hospital, Dammam, MOH, Saudi Arabia  
Tel: +966 13 844 2222;  
e-mail: alihalmomen@yahoo.com

Received 27 October 2015

Accepted 25 November 2015

Pan Arab Journal of Rhinology  
2016, 06:36–38

Intranasal pleomorphic adenomas are quite rare and are frequently misdiagnosed. We report a nasal septal pleomorphic adenoma in a 60-year-old man. Rigid endoscopy of the nose revealed a large polypoid mass filling the right posterior nasal cavity. Computed tomography scan of the paranasal sinuses demonstrated well-pneumatized paranasal sinuses and a soft tissue mass in the posterior aspect of the right nasal cavity arising from the posterior part of the septum. A submucous resection was used as an approach to the tumor and as a method of excising the mass with the segment of septum attached to it. After 4 years, the patient had experienced no further problems with the nasal airway, and repeated nasal endoscopic examination revealed no recurrence of the disease.

## Keywords:

nasal mass, nasal septum, pleomorphic adenoma

Pan Arab J Rhinol 06:36–38  
© 2016 2090-7540

## Introduction

Pleomorphic adenomas form 60% of all salivary gland neoplasms. This benign mixed minor salivary gland involvement can be seen in 8% of cases, with the palate being the most common site [1]. Intranasal pleomorphic adenomas are quite rare and are frequently misdiagnosed because they are highly cellular and, compared with pleomorphic adenomas of the major salivary glands, have few myxoid stromata [2], compared to those elsewhere. Pleomorphic adenomas are most common benign tumour of the major salivary glands. In addition, they may also occur in the minor salivary glands of the hard and soft palate.

## Case history

A 60-year-old man presented with a 2-year history of right nasal obstruction and right-sided facial pain. There was no history of visual defect, epistaxis, atopy, or previous trauma to the nose. His weight and general health were stable. Rigid endoscopy of the nose revealed a large polypoid mass filling the right posterior nasal cavity. There was no evidence of rhinosinusitis and his postnasal space was normal. There were no palpable neck nodes. Computed tomography scan of the paranasal sinuses demonstrated well-pneumatized paranasal sinuses and a soft tissue mass in the posterior aspect of the right nasal cavity arising from the posterior part of the septum. The smooth surface, preservation of mucosal lining, and the localized nature of the mass were consistent with a benign lesion (Fig. 1). Preoperative incisional biopsy of a smooth, rounded, and firm mass arising from the septal mucosa established the diagnosis of a pleomorphic adenoma. A submucous

resection was used as an approach to the tumor and as a method of excising the mass with the segment of septum attached to it. A 1 cm margin of normal ipsilateral mucosa and the surrounding perichondrium were also excised. The septal mucosa of the opposite side was preserved. Pathologic examination found a well-circumscribed, homogeneous, firm 2.5×2×1 cm grayish-white tumor (Fig. 2).

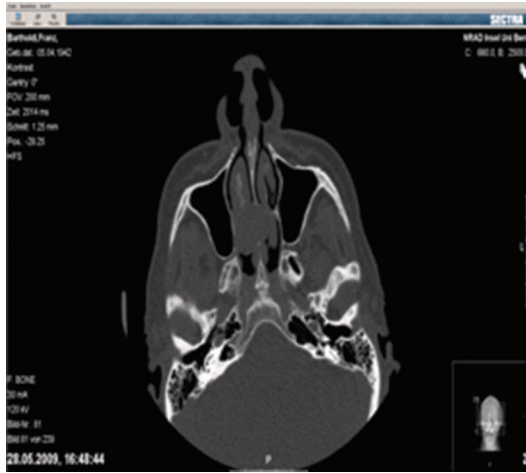Histologic examination revealed two components: epithelial and mesenchymatous. The former comprised basaloid epithelial and spindle-shaped myoepithelial cells in trabeculae, tubules, and cribriform structures, and the latter comprised large chondroid lobules with spaces occupied by regular chondrocytes and loose myxoid zones without mitosis, atypia, or necrotic sites. The tumor was well-circumscribed by a regular, noninvaded fibrous capsule, without perineural invasion (Fig. 3).

The postoperative course was uneventful. After 4 years, the patient had experienced no further problems with the nasal airway, and repeat nasal endoscopic examination revealed no recurrence of the disease.

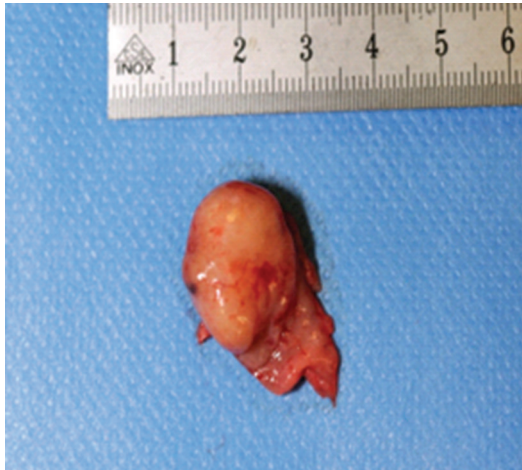## Discussion

Pleomorphic adenoma occurs commonly in the major salivary glands, predominantly the parotid gland. It also occurs in the minor salivary glands of the hard

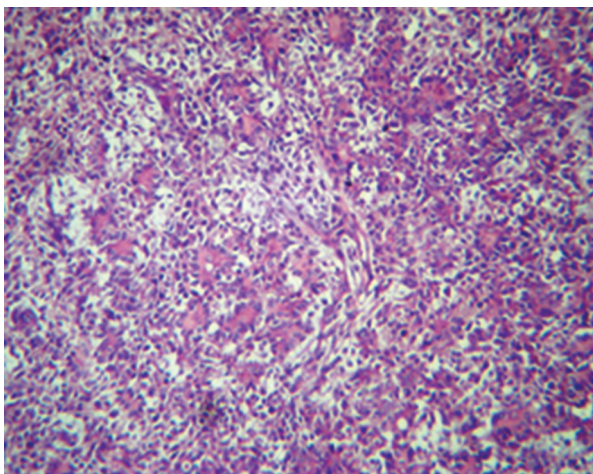
This is an open access article distributed under the terms of the Creative Commons Attribution-NonCommercial-ShareAlike 3.0 License, which allows others to remix, tweak, and build upon the work non-commercially, as long as the author is credited and the new creations are licensed under the identical terms.

**Figure 1**

The smooth surface, preservation of mucosal lining, and the localized nature of the mass were consistent with a benign lesion.

**Figure 2**

Pathologic examination found a well-circumscribed, homogeneous, firm 2.5x2x1 cm grayish-white tumor.

**Figure 3**

The tumor was well-circumscribed by a regular, noninvaded fibrous capsule, without perineural invasion.

and soft palate [3]. Mixed salivary gland tumors are found to arise from any part of the upper aerodigestive tract. However, they are rare in the nasal cavity [4]. In the nasal cavity, nasal septum is the most common site and accounts for 80% of the cases, and only 20% originated from the lateral wall or the turbinates [5]. Patients often seek medical attention because of nasal obstruction, epistaxis, or the presence of a nasal mass.

The first reported case in the literature of a pleomorphic adenoma of the nasal cavity was in 1929 [6]. Large series studies of nasal pleomorphic adenomas include 40 cases reported by Compagno and Wong [7], 41 cases by Suzuki *et al.* [8], and 59 cases reported by Wakami *et al.* [9]. The majority of tumors present between the age of 30 and 60 years and are slightly more common in women. Typical presenting features include unilateral nasal obstruction (71%) and epistaxis (56%). Other signs and symptoms include a mass in the nose, nasal swelling, epiphora, and mucopurulent rhinorrhea [7].

Pleomorphic adenomas are characterized by epithelial tissue mixed with tissues of mucoid, myxoid, or chondroid appearance. The features of pleomorphic adenomas in the aerodigestive tract are somewhat similar to those of mixed tumors of the salivary glands. Nevertheless, some differences are recognized. Myoepithelial cellularity is unusually increased in these tumors compared with major salivary gland tumors. Therefore, epithelial elements rather than the stromal elements predominate. Occasionally, pleomorphic adenomas are composed almost entirely of epithelial cells with few or no stromata [7].

Because of the high cellularity and lack of a stromal component, histologically, they resemble aggressive epithelial tumors. Haberman and Stanley reported a case of a nasal septal pleomorphic adenoma misdiagnosed as an adenoid cystic carcinoma on the basis of tissue biopsy [9]. This difficulty is reflected in a study by Compagno and Wong [7], in which 55% of cases were initially misdiagnosed.

Many authors have speculated as to the etiology of these tumors. Stevenson [10] suggested that mixed tumors in the nasal septum originate from the remnants of the vomeronasal (Jacobson's) organ. However, mixed tumors also occur in the lateral wall, where no such areas exist. Matthew *et al.* [11] believed that the origin of these tumors was from displaced embryonic ectodermal epithelial cells, which are carried through the nasal pits into the septum. Evans and Cruickshank [12] contradicted the previous two theories and claimed that these tumors are entirely epithelial tumors that arise in fully developed gland tissue.

The most useful imaging studies for the diagnosis of intranasal pleomorphic adenoma are computed tomography and MRI. The role of these techniques is to detect the mass and to determine its origin [13]. It may be difficult to demonstrate the origin when the mass is large, or when it comes in touch with two opposing surfaces. The treatment of choice for pleomorphic adenoma of the nasal cavity is local surgical excision with histologically clear margins. Various surgical approaches have been used, depending upon the size and location of the tumor in the nasal cavity. They include intranasal excision, facial degloving, and lateral rhinotomy. The development of new endoscopic techniques and instruments enable lesions to be safely removed from the nasal cavity, if the tumor is small enough to expose. These techniques have advantages of minimal blood loss, less pain, and absence of external scarring [14].

Local recurrence of intranasal pleomorphic adenomas have also been reported [15]. The histopathologic characteristic most frequently associated with recurrent tumor is a myxoid stroma, which could be spilled into the surgical field, providing a nidus for future recurrence [16].

A neoplasm originating from the nasal septum has a higher risk for malignancy compared with other sites in the nose [17]. Occasionally, pleomorphic adenoma can behave in a malignant manner, the most common variant being carcinoma ex-pleomorphic adenoma, which has a potential to metastasize. The predominant metastatic site is bone but spread to lungs, regional lymph nodes, and liver has been documented [18].

## Conclusion

In summary, pleomorphic adenomas are rare tumors of the nasal cavity. They have a higher epithelial and lower stromal component compared with their major salivary gland counterparts and may be misdiagnosed at an early stage, leading to more aggressive treatment. Although the recurrence rate is low under adequate excision, long-term follow-up and careful

examination of the nose with an endoscope are necessary.

## Financial support and sponsorship

Nil.

## Conflicts of interest

There are no conflicts of interest.

## References

- Hanna EY, Lee S, Fan CUY, Suen JY. Benign neoplasms of the salivary glands. in Cummins CW, *et al.*(Editors) *Otolaryngology head and neck surgery (Ed 4)*. Philadelphia: Elsevier Mosby; 1998, 348–377.
- Liao BS, Hilsinger RL Jr, Chong E. Septal pleomorphic adenoma masquerading as squamous cell carcinoma. *Ear Nose Throat J* 1993; 72:781–782.
- Tahlan A, Nanda A, Nagarkar N, Bansal S. Pleomorphic adenoma of the nasal septum: a case report. *Am J Otolaryngol* 2004; 25:118–120.
- Bergstrom B, Bjorkland A. Pleomorphic adenoma of the nasal septum: report of two cases. *J Laryngol Otol* 1981; 95:179–181.
- Batsakis JG. *Tumours of the head and neck. Clinical and pathologic considerations*. Ed 2 Baltimore: Williams & Wilkins; 1984. 76-99.
- Denker A, Kahler O. *Handush der Hals. Nasen ohrenheilkunde* 1929; 5:202.
- Compagno J, Wong RT. Intranasal mixed tumors (pleomorphic adenomas): a clinicopathologic study of 40 cases. *Am J Clin Pathol* 1977; 68:213–218.
- Suzuki K, Moribe K, Baba S. A rare case of pleomorphic adenoma of lateral wall of nasal cavity – with special reference of statistical observation of pleomorphic adenoma of nasal cavity in Japan. *Nippon Jibiinkoka Gakkai Kaiho* 1990; 93:740–745.
- Wakami S, Muraoka M, Nakai Y. Two cases of pleomorphic adenoma of the nasal cavity. *Nippon Jibiinkoka Gakkai Kaiho* 1996; 99:38–45.
- Stevenson HN. Mixed tumor of the septum. *Ann OtolRhinol* 1932; 41:563–570.
- Matthew S, Ersner MD, Saltzman M. A mixed tumor of the nasal septum: report of a case. *Laryngoscope* 1944; 54:287–296.
- Evans RW, Cruickshank AH. *Epithelial tumors of the salivary glands. Major problems in pathology*. Philadelphia, PA: WB Saunders Co; 1970. 167.
- Oztürk E, Saglam O, Sonmez G, Cüce F, Haholu A. CT and MRI of an unusual intranasal mass: pleomorphic adenoma. *Diagn IntervRadiol* 2008; 14:186–188.
- Motoori K, Takano H, Nakano K, *et al.* Pleomorphic adenoma of the nasal septum: MR features. *Am J Neuroradiol* 2000; 21:1948–1950.
- Jassar P, Stafford ND, MacDonald AW. Pleomorphic adenoma of the nasal septum. *Pathology in focus. J Laryngol Otol* 1999; 113:483–485.
- Krolls SO, Boyers RC. Mixed tumours of salivary glands. Long-term follow-up. *Cancer* 1972; 30:276–281.
- Rauchfuss A, Stadler F. The differential diagnosis of benign neoplasm of the nasal septum. *HNO* 1981, 29:124–127.
- Freeman FB, Kennedy KS, Parker GS, Tatum SA. Metastasizing pleomorphic adenoma of the nasal septum. *Arch Otolaryngol Head Neck Surg* 1990; 116:1331–1333.