

The incidence of complications after prelacrimal recess approach versus endoscopic sinus surgery of maxillary sinus lesions

Mohammed A. AlAyadi^a, Sherif A. Raafat^a, Khalid A. Ateya^a,
Fadi M. Gharib^a, Abdullah M. AlMurtada^b

^aDepartment of Otorhinolaryngology, Cairo University, Cairo, ^bDepartment of Otorhinolaryngology, Tamar University, Tamar, Yemen

*Correspondence to Abdullah Mohammed Al Murtada, MD, Baghdad St. Sanaa, Yemen
e-mail: Dr.abdullahmurtada@yahoo.com

Received 25 November 2015

Accepted 10 December 2015

Pan Arab Journal of Rhinology

2016, 06:16–21

Aim of work

The aim of the study was to evaluate the incidence of complications after prelacrimal recess approach (PLRA) and compare it with endoscopic sinus surgery for maxillary sinus lesions.

Patients and methods

This was a prospective study in which 20 patients were recruited between July 2013 and September 2015 from the otorhinolaryngology outpatient clinic of Kasr Al-Ainy Hospital, Cairo University. Patients with bilateral maxillary sinus lesions underwent endoscopic sinus surgery on one side and PLRA on the other side. Postoperative complications during 2-year follow-up were assessed.

Results

Two patients had epiphora at the PLRA side; one cured spontaneously, and the other was treated accordingly. Four patients had adhesions at the PLRA side, whereas two patients had adhesions at the middle meatal antrostomy side. Two patients developed numbness at the PLRA side, and one patient had persistent facial pain at the PLRA side. Intraoperatively there was excessive bleeding in three patients and an inferior turbinate destabilization in three patients at the PLRA side.

Conclusion

Our study demonstrated that, although PLRA is a minimally invasive technique, it still carries a risk for complications.

Keywords:

endoscopic sinus surgery, maxillary sinus, prelacrimal recess

Pan Arab J Rhinol 06:16–21

© 2016 2090-7540

Introduction

Complications related to Endoscopic sinus surgery (ESS) can be divided into minor and major categories. Minor complications can usually be treated with minimal consequences. The most common minor complication is synechia formation, which does not require any type of revision [1].

However, catastrophic complications do occur occasionally. They can be treated safely if recognized early.

The complication rate was linked to the extent of disease, which was measured in terms of symptom severity and health-related quality of life, the extent of polyposis, level of opacity of the sinuses on CT, and the presence of comorbidity, but not on the basis of surgical characteristics (extent of surgery, use of endoscope or microdebrider, grade of surgeon, and adjunctive turbinate surgery). An older large review of complications of ESS found a minor complication rate of 6.9% and a major complication rate of 0.85% [2].

Prelacrimal recess is a concavity in the medial, anterosuperior part of the maxillary sinus (MS). It is

located in front of the eminence of the lacrimal passages on the medial wall of maxillary sinus [3] (Fig. 1).

In our study we assessed the incidence of complications related to the endoscopic prelacrimal recess approach (PLRA) and compared them with those from middle meatal antrostomy (MMA).

Patients and methods

This is a prospective clinical trial in which 20 patients with anterior MS lesions were recruited between July 2013 and September 2015 from the otorhinolaryngology outpatient clinic, Kasr Al-Ainy Hospital, Cairo University, with a follow-up period of around 2 years.

Full history was taken from all enrolled patients and nasal examination was conducted through nasal

This is an open access article distributed under the terms of the Creative Commons Attribution-NonCommercial-ShareAlike 3.0 License, which allows others to remix, tweak, and build upon the work non-commercially, as long as the author is credited and the new creations are licensed under the identical terms.

endoscopy. Axial and coronal computed tomography of the nose and paranasal sinuses was performed with intravenous contrast when indicated. MRI was performed in selected cases.

Patients included in this study met the following criteria: they were aged 17 years or older, of either sex, and had a MS lesion.

Patients younger than 17 years with vascular tumors or with an aggressive tumor extending out of the MS were excluded from our study.

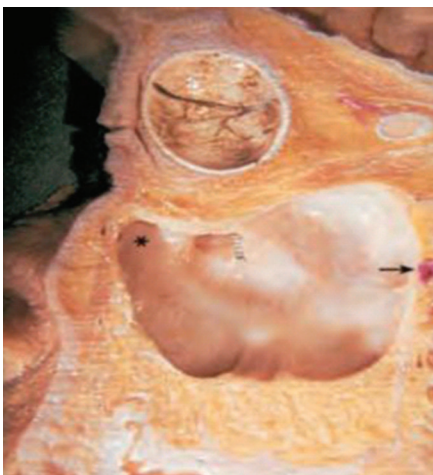Surgical details

All surgeries were performed under general anesthesia. The nasal cavity was packed with 4% xylocaine and 1:10 000 adrenaline to reduce mucosal swelling. The middle meatus lesion was removed. Uncinectomy was performed and the MS ostium was widened.

The procedure widening the maxillary ostium was performed posteroinferiorly and also anteriorly using back-biting forceps while ensuring that the nasolacrimal duct (NLD) was not injured. After complete removal of the sinus lesion from both sides, a differently angled nasal endoscope was used to assess the MS. The PLRA was performed at the side at which the lesion could not be completely removed.

The surgical technique of PLRA was started by infiltrating the incision site with 1% lidocaine (xylocaine) with 1:100 000 epinephrine solution. A curved mucosal incision was made on the lateral wall of the nasal cavity between the anterior aspect of the inferior turbinate (IT) and the posterior end of the nasal vestibule, reaching the underlying bone.

Figure 1



Medial wall of the antrum in an anatomical dissection. The prelacrimal recess (*) protrudes in an anterosuperior direction in front of the bulge of the nasolacrimal canal [4].

The mucoperiosteum was lifted posteriorly until attachment of the IT to the lateral nasal wall and then the bony attachment of IT was disconnected.

The anterior bony portion of the medial wall of the MS (parts of the frontal process of the maxilla) was opened by bone removal, which was achieved by a gauth and hammer or by using a high-speed electric drill.

An IT-NLD flap was formed and pushed medially; then the medial mucosal wall of the MS was exposed (Fig. 2).

Septoplasty was performed in seven patients. Other sinuses were managed according to the underlying pathological lesion of each patient. Finally, the nasal cavity was packed with a nasal tamponade for 48 h.

Follow-up visits were weekly during the first month, followed by monthly for over 3 months, and then at 6-month intervals for 2 years (Figs 3–5).

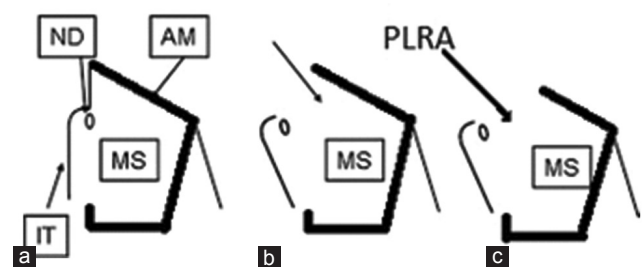
Results

Twenty patients were included into this prospective study. Eleven (55%) patients were men, and nine (45%) were women. The male to female ratio was 11:9. Their ages ranged from 24 to 71 years with an average age of 27.8 ± 11.5 years.

Intraoperative

- (1) *IT stabilization*: during operation the IT showed instability in three patients (15%) at the PLRA side, whereas at the MMA side the IT was not affected.
- (2) *The bleeding*: three patients (15%) had excessive bleeding at the PLRA side, whereas there was only the normal of bleeding from the MMA side.

Figure 2



Scheme of surgical approach. (a, b) The nasolacrimal duct (NLD) and inferior turbinate (IT) are shifted in a medial direction to allow wide exposure. (c) The lesion in the maxillary sinus (MS) is seen directly through the prelacrimal recess (PLR).

- (3) *Need for extranasal tamponade*: four cases needed two nasal tampons (the normal being one tamponade) at the side at which the PLRA was adopted, whereas on the MMA side the usual one nasal tampon was needed.
- (4) The operation time was longer when the PLRA was adopted. In the beginning the mean increase was 30 min, whereas later as the surgeon became familiar with the PLRA the operation time decreased to 15 min.

Postoperative data

All patients included in this work attended postoperative follow-up visits at 2-week intervals for 1 month, followed by monthly visits for 3 months, and then at 6-month intervals for 2 years.

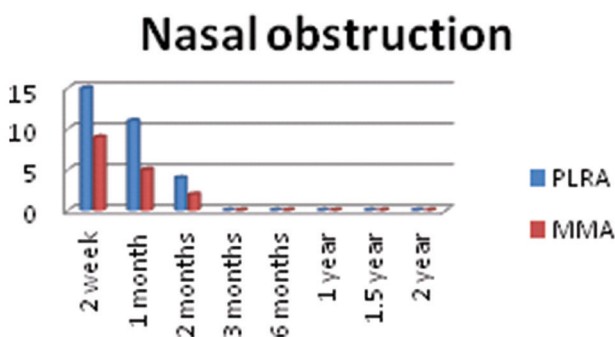
Subjective assessment

Questioning the patient about the presence or absence of preoperative symptoms, the symptoms were recorded as follows:

Nasal obstruction

- (1) At 2 weeks' postoperative interval the partial nasal obstruction was more prominent in 15 patients (75%) on PLRA side, whereas on the side of the MMA nine patients (45%) complained of partial obstruction.
- (2) At 1-month postoperative interval the partial nasal obstruction was more prominent in 11 patients (55%) on the PLRA side, whereas five patients (25%) complained of partial nasal obstruction on the MMA side.
- (3) At 3-month, 6-month, 1-year, 1.5-year, and 2-year postoperative intervals no patients complained of nasal obstruction on either the PLRA or the MMA side (Fig. 6).

Figure 3



Numbers of cases that had nasal obstruction related to postoperative follow up period.

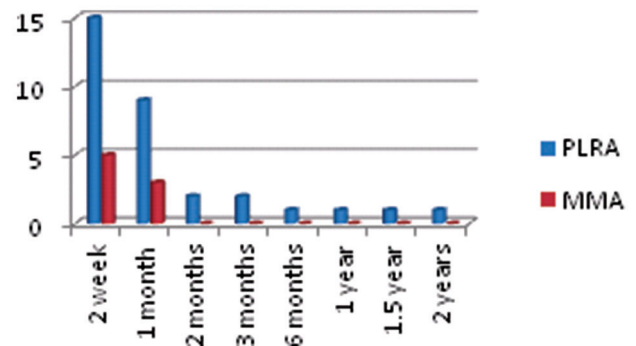
Facial pain

- (1) At 2 weeks' postoperative interval 15 patients (75%) complained of facial pain at the PLRA side, whereas only five patients (25%) had pain at the MMA side.
- (2) At 1-month postoperative interval nine patients (45%) still complained of facial pain, whereas only three patients (15%) complained of facial pain at the MMA side.
- (3) At 2 months' and 3 months' postoperative interval two patients (10%) complained of facial pain, whereas there was no facial pain at the MMA side.
- (4) At 6-month, 1-year, 1.5-year, and 2-year postoperative interval one patient (5%) complained of facial pain, whereas there was no facial pain at the MMA side (Figs. 7 and 8).

Epiphora

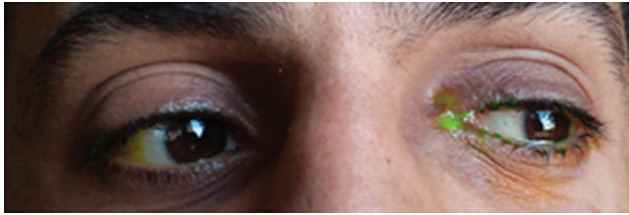
- (1) At 2 weeks' postoperative interval two patients (10%) complained of epiphora at the PLRA side, whereas there was no epiphora at the MMA side. Fluorescein test showed lacrimal system obstruction on the left side (PLRA side).
- (2) At 1, 2, 3, and 6 months' postoperative interval only one patient (5%) still complained of epiphora at the PLRA side, whereas there was no epiphora at the MMA side.
- (3) The patient who complained of unilateral epiphora at the side of the PLRA was medically treated but showed no improvement after 6 months. Both regurgitation test and fluorescein test were positive (Fig 5) in left lacrimal system at side where the PLRA was done, indicated that the NLD may injured and obstructed; hence, dacryocystorhinostomy was scheduled.
- (4) At 1-year, 1.5-year, and 2-year follow-up interval no patient complained of epiphora (Fig. 9).

Figure 4



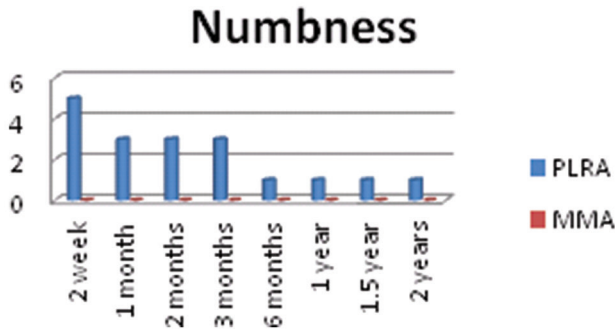
Number of patients that had a Facial pain related to postoperative follow up intervals.

Figure 5



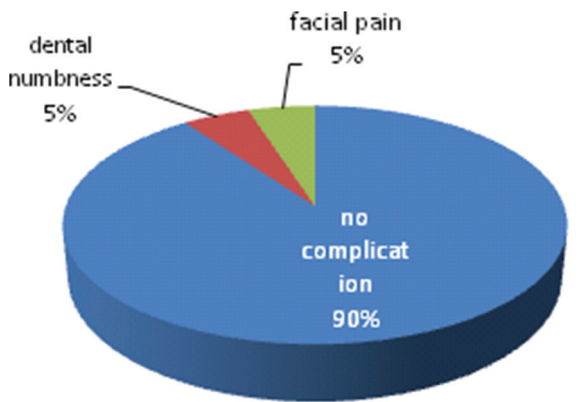
Fluorescein test showed lacrimal duct obstruction on the left side (PLRA side)

Figure 7



Number of patients that complained of teeth numbness related to postoperative follow up intervals.

Figure 9



Complication of PLRA at 2 years

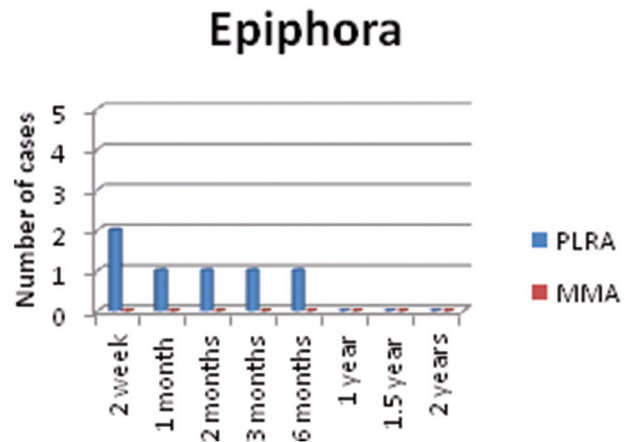
Complications of PLRA at 2 years postoperative interval.

Numbness

At 2 weeks' postoperative follow-up interval there were five patients (25%) who complained of numbness at the upper central and lateral incisor on the PLRA side, but there were no cases of numbness on the MMA side.

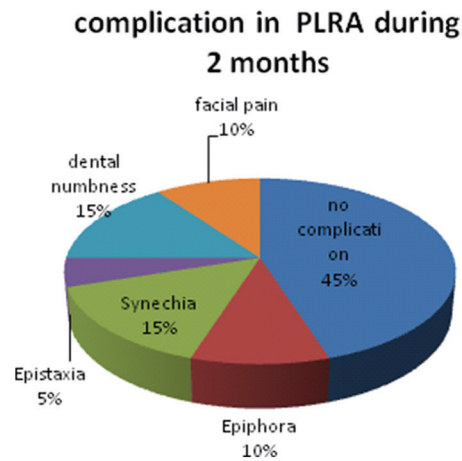
At 1, 2, and 3 months' postoperative follow-up interval there were three patients (15%) with complaints of upper central and lateral teeth numbness at the PLRA side, but there were no cases of numbness at the MMA side.

Figure 6



Number of patients that complained of Epiphora related to postoperative follow up intervals.

Figure 8



Complications of PLRA during 2 month postoperative intervals.

At 6-month, 1.5-year, and 2-year follow-up intervals there was one patient who continued to complain of numbness of the upper central and lateral teeth at the PLRA side but there were no cases of numbness at the MMA side.

Objective assessment

The postoperative evaluation in the follow-up visits included nasal endoscopic evaluation of the IT destabilization, IT-NLD flap status, granulation tissue, crustations, bleeding, synechia, inferior meatus obliteration, and need for extranasal tamponade.

- (1) *IT destabilization*: during the postoperative period there was no destabilization of the IT in any of the cases at both the PLRA and the MMA sides.
- (2) *IT-NLD flap status*: three patients (15%) had a small bare area, which healed spontaneously after

1 month, whereas on the MMA side there was no disturbance of the IT or NLD area.

- (3) *Granulation tissue*: five patients (25%) had small granulation tissue in place of the prelacrima recess incision, which was treated accordingly and disappeared within 1 month, whereas on the MMA side there was no granulation tissue.
- (4) *Crustations at the site of the prelacrima recess incision*: 19 patients (95%) had excessive crustation at the incision site at 2 weeks postoperatively. Further, at the MMA side there was very less crustation compared with the PLRA side and at the 2-month visit no crustation was found in any of the 20 patients (100%).
- (5) *Bleeding*: one patient had one attack of moderate unilateral epistaxis during the first 1 month postoperatively on the PLRA side and was treated appropriately, but there were no cases of bleeding from the MMA side.
- (6) *Synechiae*: three patients (15%) had synechiae on the PLRA side, which appeared 3 weeks postoperatively between the middle turbinate and the septum and was treated appropriately, whereas only one patient had synechiae on the MMA side.
- (7) *Inferior meatus obliteration*: two patients (10%) had an inferior meatus obliteration at the side of the PLRA, whereas there were no cases of inferior meatus obliteration on the MMA side.

Discussion

Hopkins *et al.*[5] carried out a prospective multicenter study of 3128 patients who underwent sinonasal surgery in England and Wales. Major complications such as orbital or intracranial complications, bleeding requiring ligation or orbital decompression, and return to the operating room occurred in 11 patients (0.4%). Minor complications (all other untoward events) occurred in 207 patients (6.6%). The most commonly reported minor complications were excessive perioperative hemorrhagic bleeding (5.0%) and postoperative hemorrhage requiring treatment (0.8%). In our study there was no major complication, and no postoperative bleeding.

Under such conditions the traditional Caldwell–Luc operation is necessary to reach blind areas. However, this approach is associated with significant morbidity and complications such as postoperative bleeding, buccal swelling, infraorbital nerve paresthesia, dental numbness, and devitalized teeth [6]. In our study complications such as buccal swelling and dental numbness were encountered at the PLRA side but not at the MMA side.

Numbness of the frontal teeth is caused by a lesion of the superior alveolar nerve, which runs through

the bone of the anterior MS wall and can be damaged if the piriform aperture is resected (Denker operation) [7].

In our study we encountered some morbidities as dental pain and numbness in the upper central incisors at the PLRA side in five patients (25%) as early as at 2 weeks postoperatively, whereas no dental numbness was encountered at the MMA side. The pain resolved after 1 month postoperatively, whereas the numbness was present in one patient (5%) for 2 years postoperatively. Superior alveolar nerve affection may explain this numbness.

In our study we encountered one patient with prominent facial pain at the PLRA side, whereas there was no facial pain at the MMA side. These symptoms were probably related to extensive use of the electric drill.

Brian *et al.* in a retrospective study of endoscopic sinus surgery reviewed charts of 22 patients from a medical center and of 133 patients from a private practice ($N = 155$). They found that hemorrhage had occurred postoperatively in two patients (1.5%) [8], whereas in our study only one patient had moderate postoperative epistaxis.

Gras-Cabrero and colleagues showed that total turbinectomy is associated with a significant risk for severe hemorrhage. If the IT tail is not injured, epistaxis is less likely to occur because of preservation of the IT artery [9].

Garth *et al.*[10] observed postoperative hemorrhage in 0.9% of patients who underwent anterior turbinectomy. In our study, mild epistaxis was encountered as a postoperative complication at the PLRA side in one case (5%).

It has been reported that the incidence of epiphora is as high as 30% when performing medial maxillectomy [11].

In our study, epiphora was encountered in only one case and there was persistent epiphora at the PLRA side.

The operation time was prolonged by a mean of 30 min, which may be due to lack of experience and practice with the new approach.

Conclusion

Our study demonstrated that, although the PLRA is a minimally invasive technique, it still carries a complication risk.

Financial support and sponsorship

Nil.

Conflicts of interest

There are no conflicts of interest.

References

- 1 Stammberger H, Posawets W. Functional endoscopic sinus surgery: concept, indications and results of the Messerklinger technique. *Eur Arch Otorhinolaryngol* 1990; 247:63–76.
- 2 Ramakrishnan VR, Kingdom TT, Nayak JV, Hwang PH, Orlandi RR. Nationwide incidence of major complications in endoscopic sinus surgery. *Int Forum Allergy Rhinol* 2012; 2(1):34–39.
- 3 Hosemann W, Scotti O, Bentzien S. Evaluation of telescopes and forceps for endoscopic transnasal surgery on the maxillary sinus. *Am J Rhinol* 2003; 17(5):311–316.
- 4 Wigand ME. Endoscopic anatomy of the nose and paranasal sinuses. In: Wingand ME, Iro H, editors *Endoscopic surgery of the paranasal sinuses and anterior skull base*. 2nd ed. New York: Thieme; 2008; 46.
- 5 Hopkins C, Browne JP, Slack R, Lund VJ, Topham J, Reeves BC, *et al.* Complications of surgery for nasal polyposis and chronic rhinosinusitis: the results of a national audit in England and Wales. *Laryngoscope* 2006; 116(8):1494–1499.
- 6 Kim E, Duncavage JA. Caldwell–Luc procedure. *Operative Tech Otolaryngol* 2010; 21:163–165.
- 7 Weber RK, Werner JA, Hildenbrand T. Endonasal endoscopic medial maxillectomy with preservation of the inferior turbinate. *Am J Rhinol Allergy* 2010; 24(6):132–135.
- 8 Matthews BL, Smith LE, Jones R, Miller C, Brooks Schmidt JK. Endoscopic sinus surgery-outcome in 155 cases. *Otolaryngol Head Neck Surg* 1991; 104:244–246.
- 9 Gras-Cabrerizo JR, Masegur-Solench H, Pujol-Olmo A, Montserrat-Gili JR, Ademá-Alcover JM, Zarraonandia-Andraca I. Endoscopic medial maxillectomy with preservation of inferior turbinate: how do we do it?. *Eur Arch Otorhinolaryngol* 2011; 268(3):389–392.
- 10 Garth RJ, Cox HJ, Thomas MR. Haemorrhage as a complication of inferior turbinectomy: a comparison of anterior and radical trimming. *Clin Otolaryngol Allied Sci* 1995; 20(3):236–238.
- 11 Wormald PJ, Ooi E, van Hasselt CA, Nair S. Endoscopic removal of sinonasal inverted papilloma including endoscopic medial maxillectomy. *Laryngoscope* 2003; 113(5): 867–873.