

# Endoscopic nasopharyngectomy for nasopharyngeal carcinoma

Reda Hussien Kamel<sup>a</sup>, Mohamed Salah Eldeen Hassan<sup>a</sup>,  
Ahmed Elfarouk Abdelfattah<sup>a</sup>, Ahmed Selim Fouad<sup>b</sup>, Sameh Medhat Zamzam<sup>c</sup>

<sup>a</sup>Professor of Otorhinolaryngology,  
<sup>b</sup>Professor of Clinical Oncology, <sup>c</sup>Lecturer of  
Otorhinolaryngology, Faculty of Medicine, Cairo  
University, Kasr Alainy Medical School, Garden  
City, Cairo, Dean's Office, Egypt

\*Correspondence to Reda Hussien Kamel, MD,  
Professor of Otorhinolaryngology,  
Faculty of Medicine, Cairo University,  
00201222137172 Kasr Alainy Medical School,  
Garden City, Cairo, Dean's Office, Egypt  
e-mail: rhinology@redakamel.com

Received 2 October 2015

Accepted 24 February 2016

Pan Arab Journal of Rhinology  
2016, 06:5–10

## Background

The radiosensitivity of nasopharyngeal carcinoma has led to effective primary treatment using radiation with or without chemotherapy. Despite modern radiotherapy techniques, recurrent or persistent disease remains challenging.

## Materials and Methods

This study included 10 patients who underwent endoscopic nasopharyngectomy: two primary cases of nasopharyngeal carcinoma, five cases recurrent after finishing treatment with chemoradiation by 7–14 months, and three patients showed residual disease just after finishing therapy using chemoradiotherapy confirmed with biopsy. The average age was 43.5 years. Chemoradiotherapy was performed postoperatively for all patients. Margin status and complications were evaluated. Repeated nasopharyngeal endoscopic assessment plus computed tomography and MRI imaging with contrast were carried out, with a mean follow-up period of 17.5 months.

## Results

One patient showed recurrence (10%) and was managed with resurgery. No deaths were recorded due to the disease (overall survival rate, 100%) until the end of this study, and there were no major complications.

## Conclusion

Endoscopic nasopharyngectomy is a feasible, direct, effective, and safe surgical procedure. Long-term follow-up is necessary for better assessment.

## Keywords:

endoscopic, nasopharyngeal carcinoma, nasopharyngectomy

Pan Arab J Rhinol 06:5–10  
© 2016 2090-7540

## Introduction

The recurrence rate of nasopharyngeal carcinoma (NPC) at 5 years following modern radiotherapy ranges from 19 to 56% depending on the initial stage of presentation [1]. Multiple reirradiation modalities have been developed for the management of recurrent NPC, including brachytherapy, intensity-modulated radiation therapy, and stereotactic radiation. However, surgical salvage has also been validated as an alternative with favorable local control and survival rates [2].

The recent use of endoscopic approaches to perform nasopharyngectomy has raised substantial interest, offering the advantage of targeted resection under high magnification while avoiding the functional and cosmetic problems associated with transpalatal, transmaxillary, or transcervical approaches. The natural access afforded by the nasal cavities to access the entire nasopharynx has facilitated achieving a complete resection with reduced patient morbidity [3].

## Aim of the study

The aim of this study was to evaluate the feasibility, efficacy, and safety of nasopharyngeal endoscopic resection (NER) as a treatment for primary and recurrent NPC.

## Materials and methods

This study included 10 patients with NPC between May 2012 and January 2015: two patients with a history of no previous treatment, five cases recurrent after finishing treatment with chemoradiation by 7–14 months, and three patients with residual disease just after finishing therapy using chemoradiotherapy confirmed by means of biopsy. As regards TMN classification, five patients were classified as T<sub>3</sub>N<sub>0</sub>M<sub>0</sub>, three as T<sub>1</sub>N<sub>0</sub>M<sub>0</sub>, one patient as T<sub>2a</sub>N<sub>0</sub>M<sub>0</sub>, and another patient was classified as T<sub>3</sub>N<sub>1</sub>M<sub>0</sub> [Table 1]. This study had been approved by ethical committee of faculty of medicine, Cairo university.

In this study, NER was performed using an exclusively endoscopic technique, the two-handed technique, using cold instruments. Surgical navigation was not used.

For two patients, the resection was limited to the posterosuperior nasopharyngeal wall reaching the bony

This is an open access article distributed under the terms of the Creative Commons Attribution-NonCommercial-ShareAlike 3.0 License, which allows others to remix, tweak, and build upon the work non-commercially, as long as the author is credited and the new creations are licensed under the identical terms.

**Table 1 Site of the lesion and staging as evaluated with endoscopy and imaging**

Patient number	TNM	Roof of the nasopharynx	Fossa of Rosenmuller	Posterior wall of the nasopharynx	Nasal cavity	Invading sphenoid sinus	Cartilaginous ET	Parapharyngeal space	PPF and ITF
1	T <sub>3</sub>	+	+	-	-	+	-	-	-
2	T <sub>2a</sub>	+	+	+	+	-	-	-	-
3	T <sub>1</sub>	-	+	+	-	-	-	-	-
4	T <sub>3</sub>	+	+	+	-	+	-	-	-
5	T <sub>1</sub>	-	+	+	-	-	-	-	-
6	T <sub>3</sub>	+	+	+	-	+	-	-	-
7	T <sub>3</sub>	+	+	+	+	+	-	-	-
8	T <sub>1</sub>	+	+	-	-	-	-	-	-
9	T <sub>3</sub>	+	+	-	-	+	-	-	-
10	T <sub>3</sub>	+	+	+	-	+	-	-	-

ET, Eustachian tube; PPF, Pterygopalatine fossa; ITF, Infratemporal fossa

floor of the sphenoid sinus. The cartilaginous portion of the Eustachian tube was preserved. Posteriorly, the surgical resection deeply reached the periosteum of the skull base, and the ventral portion of the clivus was always drilled out. In such a limited resection, the tumor was always removed in a piecemeal manner with adequate and safe mucosal margins.

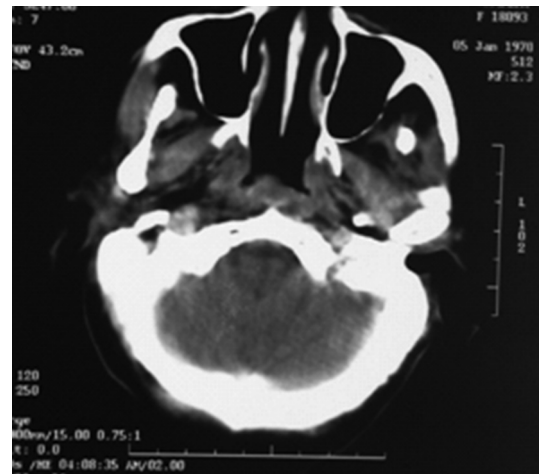
For the other eight patients, the resection was extended superiorly to include the anterior wall and the floor of the sphenoid sinus. The posterior part of the nasal septum was removed together with the sphenoid rostrum superiorly, and then the natural ostia were enlarged and both the anterior sphenoidal wall and the intersphenoidal septum were removed. The sphenoidal mucosa was stripped out and the floor of the sinus was entirely drilled to the coronal plane at the level of the clivus. The cartilaginous portion of the Eustachian tube was preserved. The superior turbinate was resected to obtain a wide median sphenoidotomy.

Tympanic membrane ventilation tube was inserted in all patients. One patient underwent block neck dissection for metastatic cervical lymphadenopathy.

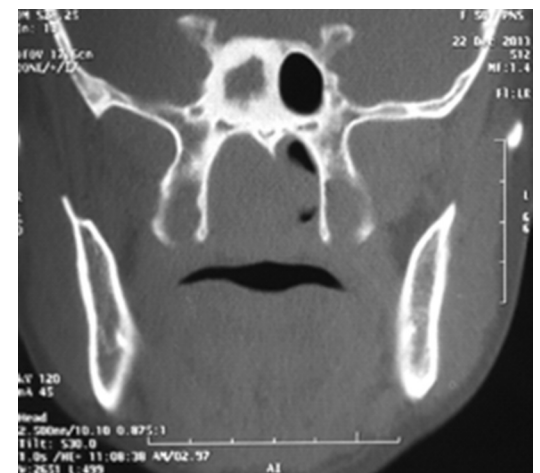## Results

This study included six female and four male patients. Five patients were between 40 and 60 years of age, three patients were between 20 and 40 years of age, and two patients were older than 60 years. Eight patients complained of headache, two had epistaxis, five had nasal obstruction, six had aural fullness and deafness, and one patient presented with metastatic cervical lymph nodes.

In the current study, site of the lesion had been documented using data from preoperative computed tomography scan (Figs 1–3), MRI, and endoscopic evaluation (Fig. 4) at the time of surgery [Table 1].

**Figure 1**

Computed tomography (CT) scan axial view on the nasopharynx showing posterior wall nasopharyngeal carcinoma.

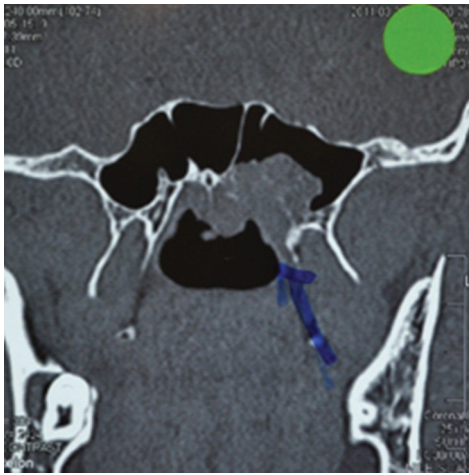
**Figure 2**

Computed tomography (CT) scan coronal view on the nasopharynx showing right nasopharyngeal carcinoma (NPC) invading sphenoid air sinus.

In the current study, eight patients (80%) had squamous cell carcinoma grade III according to the WHO classification, one patient (10%) was diagnosed

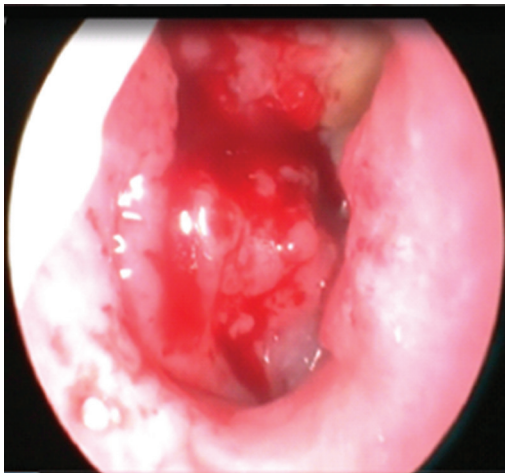
as having squamous cell carcinoma grade II, and the last one was diagnosed as having adenocarcinoma [Table 2].

**Figure 3**



Computed tomography (CT) scan coronal view on the nasopharynx showing nasopharyngeal carcinoma (NPC) in the roof and invading the left sphenoid air sinus.

**Figure 4**



Endoscopic view of nasopharyngeal carcinoma of the right fossa of Rosenmuller.

In the current study, three patients (30%) showed positive oncological margin, whereas seven patients (70%) showed free margin. Three patients (30%) showed postoperative adhesions at the site of surgery on follow-up after 2 months of surgery, and two patients developed new otitis media with effusion after blockage of their ventilation tubes with ear wax.

No intraoperative or postoperative major complications were detected. All cases were subjected to postoperative adjuvant chemoradiotherapy. Follow-up period ranged from 11 to 24 months, with a mean of 17.5 months. Follow-up included meticulous endoscopic examination every 2 months. MRI and computed tomography scan with contrast (Figs 5 and 6) and biopsy were reserved for suspicious lesion. Both radiological techniques were used for two cases during the follow-up period: one of them showed recurrence (10%) (the adenocarcinoma patient) 24 months postoperatively and was treated with resurgery. Following the same methodology of this study, the resurgery was performed by means of endoscopic resection of the mass and resection of the left pterygoid process inferior to lateral recess with preservation of the cartilaginous portion of the Eustachian tube with no subsequent recurrence after 6 months of follow-up.

## Discussion

Several approaches to the nasopharynx have been described. The approach used nowadays is the distillation of the efforts made by countless surgeons over the years, who have attempted to remove disease from this particularly challenging part of the skull base. A variety of surgical approaches have been described, and some are designed for specific pathological entities. Each approach has its own applications, advantages, and limitations [4].

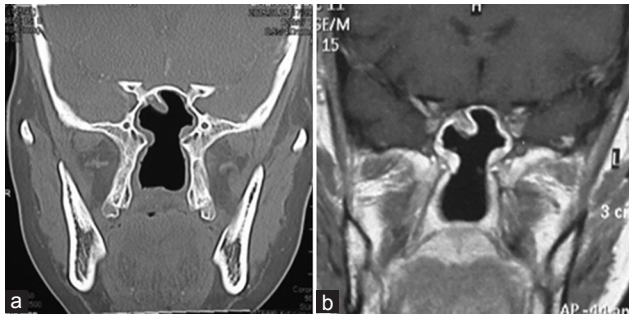
Surgery avoids the potentially severe complications of reirradiation, including temporal lobe necrosis, hemorrhage, and osteoradionecrosis [5].

**Table 2** Parts removed during surgery

Patient number	Posterior septectomy	Posterior nasopharyngeal wall mucosa	Partial resection of superior turbinate	Sphenoidotomy and sphenoid floor	Medial maxillectomy and trans pterygoid	Cartilaginous ET
1	+	+	+	+	-	-
2	+	+	-	+	-	-
3	-	+	-	-	-	-
4	+	+	+	+	-	-
5	-	+	-	-	-	-
6	+	+	+	+	-	-
7	+	+	+	+	-	-
8	+	+	-	+	-	-
9	+	+	+	+	-	-
10	+	+	+	+	-	-

ET, Eustachian tube

Figure 5



Postoperative computed tomography (CT) scan (a) and MRI (b).

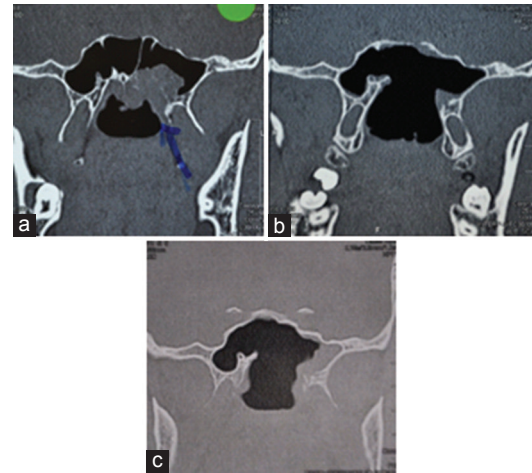
Surgery (open nasopharyngectomy) holds its own significant challenges, to circumvent critical anatomic structures and to obtain adequate exposure and visualization. The limited exposure and proximity to vital structures can in fact undermine the resection [6].

In the study by Chen *et al.* (2009) [7], 17, four, 14, and two of 37 patients were classified as rT1N0M0, rT2aN0M0, rT2bN0M0, and rT3N0M0, respectively. In the study by Chen *et al.* (2011) [8], of 12 patients, six patients were classified as rT1N0M0, three patients were classified as rT2N0M0, and three patients were classified as rT3N0M0. In the study by Castelnovo *et al.* (2010) [9], among 17 patients, 10 cases were of stage 1, two cases were of stage 2, three cases were of stage 3, and two cases were of stage 4. However, in the current study, five patients were classified as T<sub>3</sub>N<sub>0</sub>M<sub>0</sub>, three patients as T<sub>1</sub>N<sub>0</sub>M<sub>0</sub>, one patient as T<sub>2a</sub>N<sub>0</sub>M<sub>0</sub>, and another patient was classified as T<sub>3</sub>N<sub>1</sub>M<sub>0</sub>.

Castelnovo *et al.* (2010) [9] performed 17 NER: nine for NPC, two for adenocarcinoma, one for melanoma, three for adenoid cystic carcinoma, one for papillary adenocarcinoma, and one for undifferentiated sarcoma. In a study by Al-Sheibani *et al.* (2011) [10], endoscopic endonasal transpterygoid nasopharyngectomy was performed for 20 patients (nine epidermoid carcinoma, one lymphoepithelioma, five adenoid cystic carcinoma, two adenocarcinoma, two mucoepidermoid carcinoma, and one sarcoma). However, the current study included nine cases of squamous cell carcinoma and one patient with adenocarcinoma.

There is some debate on endoscopic nasopharyngectomy for primary cases with no prior therapy with Chemoradiotherapy (CRT). We agree with the studies by Castelnovo *et al.* (2010) [9], who performed NER for five of 17 cases with no prior therapy. In a study by Al-Sheibani *et al.* (2011) [10], 10 of 20 patients underwent endoscopic nasopharyngectomy with no prior therapy. Similarly, in the study by Lai and Chen (2011) [11], NER was performed for two cases with no prior therapy.

Figure 6



Preoperative (a) and postoperative (b) computed tomography (CT) scan and recurrence (c) for the adenocarcinoma patient.

We also agree with most of the studies conducted for recurrent cases. In a study by Yoshizaki *et al.* (2005) [2], endoscopic salvage nasopharyngectomies were performed for five patients and for six patients in a study by Chen *et al.* (2007) [12]. Six patients with recurrent NPC underwent endoscopic surgery in the study by Rohaizam and colleagues (2009). Nine patients with recurrent tumors underwent salvage endoscopic surgery in the study by Ning and colleagues (2014) [13,14]. In a study by Macdonald *et al.* (2014) [15], two patients with recurrent NPC underwent surgery.

Ko *et al.* (2009) [16], used potassium titanyl phosphate (KTP 532) laser with endoscopic nasopharyngectomy. Two studies have used a combined technique of Da Vinci transoral robotic surgery and endonasal endoscopic nasopharyngectomy. Tsang *et al.* (2013) [17] used transoral robotic surgery with the delivery of the specimen transorally. In a study by Tay and colleagues (2014), they created sufficient access for the robotic instruments to be docked by means of bilateral superior sublabial incisions, followed by anterior antrostomies or midfacial degloving. They recommended this technique to overcome the disadvantages of four-handed endoscopic nasopharyngectomy used by Yoshizaki *et al.* (2005) and Al-Sheibani *et al.* (2011) [2,10,18].

Ho *et al.* (2012) [19] used the navigation system to facilitate identification of the skull base and carotid artery. In the study by Al-Sheibani *et al.* (2011) [10], they used the navigation system in all cases; this may be explained by their use of transpterygoid approach in all cases. In the present study, there was no need for navigation system as lesions were limited and away from internal carotid artery. The same as in many studies [2,16,20].

Most of the studies performed en-bloc removal of the tumor with frozen section for the margins [8–12,15,21]. In the present study, we removed the tumor in a piecemeal manner without frozen section for the margins. En-bloc resection was technically difficult. Biopsies from the margin were sent to the pathology department as a separate specimen. No reconstruction was performed, and wounds were left to heal by secondary intention.

Castelnuovo and colleagues (2010) had classified endoscopic nasopharyngectomy into three types according to tumor extension. The third type includes medial maxillectomy to approach the pterygopalatine fossa and for resection of the cartilaginous part of the Eustachian tube. This also carries the risk for injury of the parapharyngeal segment of the internal carotid artery [9]. In this study, we performed eight surgeries equivalent to NER type 2 (NER 2) and two surgeries equivalent to NER 1 according to the Castelnuovo classification.

In contrast, most of the studies did not follow the Castelnuovo classification. Al-Sheibani *et al.* (2011) [10] recommended medial maxillectomy as a main step together with sphenoidotomy and ethmoidectomy to create a single big cavity for allowing the bimanual technique with proper handling of instruments for resection of the tumor. Ning *et al.* (2014) [14] performed medial maxillectomy with drilling of the medial pterygoid plate for rT3 patients.

In the current study, radical neck dissection was performed for only one patient who had lymphatic metastasis. Al-Sheibani *et al.* (2011) [10] performed neck dissection for one patient (5%) with recurrent lymphoepithelioma of 20 patients. Ko *et al.* (2009) [16] performed modified neck dissection for two patients with N1. In a study by Ho *et al.* (2012) [19], three patients had neck disease addressed concurrently.

In the present study, no intraoperative or postoperative major complications were reported. Chen and colleagues (2007), Chen and colleagues (2009), and Castelnuovo and colleagues (2010) also reported the same. However, in a study by Al-Sheibani and colleagues (2011), one patient suffered from an Internal Carotid Artery (ICA) injury, without permanent sequelae [7,9,10,12].

In the study by Chen and colleagues (2007), follow-up was carried out for 16–59 (average 29) months. One local recurrence was noted in secondary case, which was treated with intensity-modulated radiation therapy and chemotherapy [12]. In the study by Chen and colleagues (2009), the follow-up period was 6–45 months. Recurrence was reported in five (13.5%) secondary cases [6]. According to the study by Castelnuovo

*et al.* (2010), follow-up period was 10–138 months, and recurrence was reported in five of 17 cases (30%) (three NPC, one adenoid cystic carcinoma, and one undifferentiated sarcoma) (three secondary cases and two primary) [9]. In the study by To *et al.* (2002) [22], 15/31 patients showed recurrence after a mean follow-up period of 16 months after open nasopharyngectomy. In the present study, patients were followed up to 11–24 months with 10% recurrence (one patient with adenocarcinoma) managed with resurgery. This low recurrence rate may be explained by proper eradication of malignant tissue and by postoperative adjuvant therapy, taking in consideration the short-term follow-up period.

## Conclusion

Endoscopic nasopharyngectomy is a feasible, direct, effective, and safe surgical procedure. This work should be carried out by a specialized team of otolaryngologists and oncologists.

## Financial support and sponsorship

Nil.

## Conflicts of interest

There are no conflicts of interest.

## References

- 1 Sanguineti G, Geara FB, Garden AS, Tucker SL, Ang KK, Morrison WH, Peters LJ. Carcinoma of the nasopharynx treated by radiotherapy alone: determinants of local and regional control. *Int J Radiat Oncol Biol Phys* 1997; 37(5):985–996.
- 2 Yoshizaki T, Wakisaka N, Muro S, Shimizu Y, Furukawa M. Endoscopic nasopharyngectomy for patients with recurrent nasopharyngeal carcinoma at the primary site. *Laryngoscope* 2005; 115(8):1517–1519.
- 3 Solares CA, Ong YK, Snyderman CH. Transnasal endoscopic skull base surgery: what are the limits? *Curr Opin Otolaryngol Head Neck Surg* 2010; 18(1):1–7.
- 4 Wei WJ. Salvage surgery for recurrent primary nasopharyngeal carcinoma. *Crit Rev Oncol Hematol* 2000; 33(2):91–98.
- 5 Suárez C, Rodrigo JP, Rinaldo A, Langendijk JA, Shaha AR, Ferlito A. Current treatment options for recurrent nasopharyngeal cancer. *Eur Arch Otorhinolaryngol* 2010; 267(12):1811–1824.
- 6 King WW, Ku PK, Mok CO, Teo PM. Nasopharyngectomy in the treatment of recurrent nasopharyngeal carcinoma: a twelve-year experience. *Head Neck* 2000; 22(3):215–222.
- 7 Chen MY, Wen WP, Guo X, Yang AK, Qian CN, Hua YJ, *et al.* Endoscopic nasopharyngectomy for locally recurrent nasopharyngeal carcinoma. *Laryngoscope* 2009; 119(3):516–522.
- 8 Chen M, Wang S, Zhu Y. Use of posterior pedicle nasal septum and floor mucoperiosteum flap to resurface the nasopharynx after endoscopic nasopharyngectomy for recurrent nasopharyngeal carcinoma. *Head Neck* 2011; 34(10):1383–1388.
- 9 Castelnuovo P, Dallan I, Bignami M, Battaglia P, Mauri S, Bolzoni Villaret A, *et al.* Nasopharyngeal endoscopic resection in the management of selected malignancies: ten-year experience. *Rhinology* 2010; 48(1):84–89.
- 10 Al-Sheibani S, Zanation AM, Carrau RL, Prevedello DM, Prokopakis EP, McLaughlin N, *et al.* Endoscopic endonasal transpterygoid nasopharyngectomy. *Laryngoscope* 2011; 121(10):2081–2089.

- 11 Lai YS, Chen MK. Exclusively endoscopic resection of nasopharyngeal adenocarcinoma. *Clin Exp Otorhinolaryngol* 2013; 6(4):263–265.
- 12 Chen MK, Lai JC, Chang CC, Liu MT. Minimally invasive endoscopic nasopharyngectomy in the treatment of recurrent T1-2a nasopharyngeal carcinoma. *Laryngoscope* 2007; 117(5):894–896.
- 13 Rohaizam J, Subramaniam SK, Vikneswaran T, Tan VE, Tan TY. Endoscopic nasopharyngectomy: the Sarawak experience. *Med J Malaysia* 2009; 64(3):213–215.
- 14 Hsu NI, Shen PH, Chao SS, Ong YK, Li CS. En bloc resection concept for endoscopic endonasal nasopharyngectomy: surgical anatomy and outcome. *Chin Med J (Engl)* 2014; 127(16):2934–2939.
- 15 Macdonald K, Fandino M, Vescan A, Gentili F, Witterrick I. Endoscopic nasopharyngectomy for locally recurrent nasopharyngeal carcinoma: how we do it?. *J Otol Rhinol* 2014;3:4.
- 16 Ko JY, Wang CP, Ting LL, Yang TL, Tan CT. Endoscopic nasopharyngectomy with potassium-titanyl-phosphate (KTP) laser for early locally recurrent nasopharyngeal carcinoma. *Head Neck* 2009; 31(10):1309–1315.
- 17 Tsang R, Ho W, Chan J, Wei W. Combined robotic and endoscopic nasopharyngectomy for recurrent nasopharyngeal carcinoma. *Asian Rhinol J* 2013; 1:61–64.
- 18 Tay H, Han H, Sudirman S. Robotic nasopharyngectomy. *Operat Tech Otolaryngol* 2014; 25:299–303.
- 19 Ho AS, Kaplan MJ, Fee WE Jr, Yao M, Sunwoo JB, Hwang PH. Targeted endoscopic salvage nasopharyngectomy for recurrent nasopharyngeal carcinoma. *Int Forum Allergy Rhinol* 2012; 2(2):166–173.
- 20 Chen MY, Hua YJ, Wan XB, Sun R, Huang PY, Xiang YQ, *et al*. A posteriorly pedicled middle turbinate mucoperiosteal flap resurfacing nasopharynx after endoscopic nasopharyngectomy for recurrent nasopharyngeal carcinoma. *Otolaryngol Head Neck Surg* 2012; 146(3):409–411.
- 21 Kasemsiri P, Prevedello DM, Otto BA, Old M, Ditzel Filho L, Kassam AB, Carrau RL. Endoscopic endonasal technique: treatment of paranasal and anterior skull base malignancies. *Braz J Otorhinolaryngol* 2013; 79(6):760–779.
- 22 To EW, Lai EC, Cheng JH, Pang PC, Williams MD, Teo PM. Nasopharyngectomy for recurrent nasopharyngeal carcinoma: a review of 31 patients and prognostic factors. *Laryngoscope* 2002; 112(10):1877–1882.