



The application of the modified skoog's technique in correction of saddle nose deformity

Nassim T. Nassim

Faculty of Medicine, Cairo University, Egypt

Email: naseentalat@yahoo.com

A number of techniques have been used to repair saddle nose deformities. Tissue properties of autogenous costal cartilage make it particularly suitable for nasal augmentation. Graft warping is one the most common complications of costal cartilage use. Many trials have been attempted to overcome warping, none of them was totally successful. In this study 14 cases with saddle nose deformity were corrected using a modification of Skoog's technique with satisfactory results.

Keywords: Saddle nose, Skoog's technique.

INTRODUCTION

Saddle nose is a term to describe collapse of the middle vault in relation to the tip and dorsum of the nose. This collapse results from a decrease in the structural support of the cartilaginous or bony framework deep to the nasal soft tissue envelope.⁽¹⁾ It was first recognized in the mid nineteenth century as resulting from nasal septal perforation, and still presents significant reconstructive challenge.⁽²⁾

The cause of saddle nose deformity is essentially traumatic. This includes accidental and iatrogenic trauma. Severe frontal blows to the nose can cause saddling directly by disrupting both the bony and cartilaginous skeletons of the nose. Indirectly, accidental trauma can cause septal hematoma followed by necrosis and loss of dorsal support.⁽³⁾

Iatrogenic saddle nose deformity results from over-reduction of a nasal hump including both its bony and cartilaginous elements. Radical sub-mucous resection of the nasal septum can equally result in supra-tip nasal saddling.⁽⁴⁾ Other rare causes for nasal saddling include Binder syndrome,⁽⁵⁾ nasal granulomas,⁽⁶⁾ cocaine abuse⁽⁷⁾ and malignant nasal tumors.⁽⁸⁾

A variety of graft material had been advocated in correction of the saddle nose deformity. These include costal cartilage,⁽⁹⁾ conchal cartilage, septal bone,⁽¹⁰⁾ iliac crest bone,⁽¹¹⁾ calvarial bone,⁽¹²⁾ synthetic grafts as gore-tex,⁽¹³⁾ medpore,⁽¹⁴⁾ diced cartilage wrapped in surgical (Turkish delight),⁽¹⁵⁾ diced cartilage wrapped in fascia,⁽¹⁶⁾ tibial bone graft,⁽¹⁷⁾ and lastly coral implants.⁽¹⁸⁾

Costal cartilage remains to be among the top of the reconstructive graft material armamentarium in correction of the saddle nose deformity. This is due to its ease of fabrication and sculpturing, consistency and resistance to absorption.⁽¹⁹⁾

The main disadvantage of costal cartilage graft is warping, which is the tendency of the cartilage to curl up and become curved, this is due to distortion of the system of intersecting forces (that are in delicate balance with intact cartilage) when the cartilage is cut.⁽²⁰⁾

Various measures have been advocated to reduce the rate of rib graft warping, however, none of them was proved to be very effective in prevention of warping. However all these measures were aiming at preventing or decreasing a natural inherent character in the costal cartilage. To our knowledge, no attempts have been made to hide the phenomenon rather than preventing it. This study utilizes the concept of "Skoog's technique",^(21,22) initially described

The application of the modified skoog's technique in correction of saddle nose deformity

to overcome dorsal irregularity after nasal hump reduction, as a camouflage to mask costal cartilage warping in correction of the saddle nose deformity.

PATIENTS AND METHODS

Fourteen patients with saddle nose deformities were operated upon at Cairo University Hospitals, during the period from October 2009 to June 2011.

Eight patients were females, while six patients were males. Age ranged from 21-42 years with a mean of 29.3 years.

The cause of the saddle deformity included previous nasal (septal) surgery (8 patients) and facial trauma (6 patients).

Previous attempts done elsewhere were done in two patients (tibial bone graft, costal cartilage graft). The rest of the patients (n=12) were candidates for primary correction.

Costal cartilage was used as a dorsal augmentation graft in all cases. The lower edge of the seventh costal cartilage was used in all cases. Modified "Skoog's technique" was used in all cases in an attempt to mask any future cartilage warping.

Technique: The nasal dorsum was approached in all cases via a closed approach. Bilateral rim incisions were made, and then the lower lateral cartilages were exposed, followed by sub-SMAS dissection over the nasal dorsal skeleton.

The costal cartilage graft was harvested from the lower border of the seventh costal cartilage and was fashioned in a boat-shaped dorsal graft.

Using a 15 blade, the cartilaginous dorsum was incised on either side such that a thin layer of cartilage is shaved off the dorsum. The incision was started about 0.5cm cranial to the septal angle (where the upper lateral cartilages and the septum meet). Preserving this point keeps the upper lateral cartilage-septal assembly intact caudally. (Fig. 1a).

This is further extended into the bony dorsum using a hump osteotome taking only few millimetres of the bony dorsum. This hump osteotomy was not continued through the glabellar attachment. Instead, a green-stick fracture was sufficient just to allow this thin bony-cartilaginous plate to hinge upwards. This can be achieved using a curved osteotome. (Fig. 1b).

The fashioned costal cartilage graft was then inserted underneath this dorsal plate. Using prolene 4.0 sutures, the dorsal plate, graft and underlying upper lateral cartilages were sutured for fixation. (Fig. 1c).

Complementary tip support was done in all cases in the form of columellar struts and shield grafts. A nasal splint was kept in place for ten days after surgery.

Post-operative photographs were taken starting from 3 months and repeated every month thereafter. Objective assessment was done by documentation of the degree of warping. The degree of "warping" was detected by analysing the post-operative front views. Scoring of the degree of warping was done accordingly. Table 1 Subjective assessment was done by scoring the patient's satisfaction. Table 2.

Follow-up period ranged from 8 to 19 months with a mean of 12.3 months.

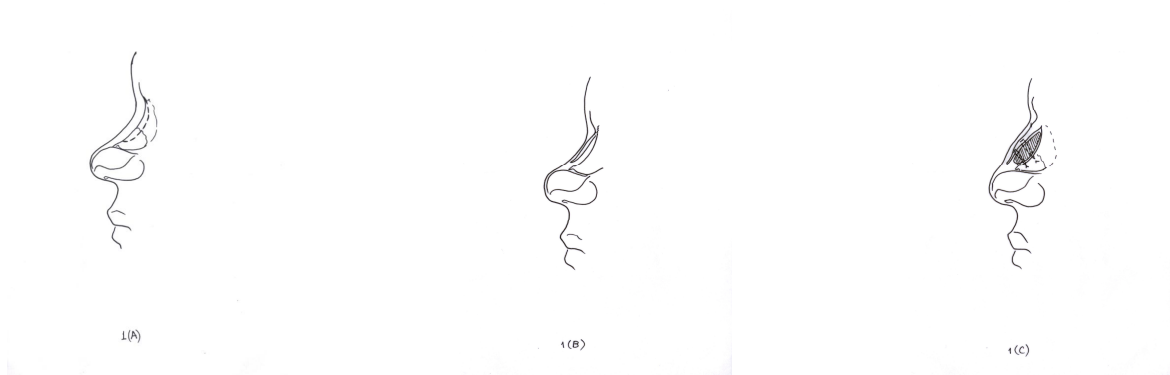


Fig 1. Diagrammatic illustration of the Technique. 1-a: the incision in the cartilaginous dorsum extended using the hump osteotome into the bony dorsum shaving a thin plate of the natural dorsum. Note that the incision in the cartilaginous part started few millimetres cranial to the septal angle, where the upper lateral cartilages meet the septal angle medially. Preserving this point keeps the assembly of the mid-dorsum intact. 1-b: the cranial edge of the osteotomy is only green-stick fractured such that the dorsal plate hinges upwards. 1-c: the graft is placed underneath the dorsal plate and fixed in place using prolene sutures.

RESULTS

Shaving a thin dorsal plate off the nasal skeleton was not an easy task to do. However, this dorsal plate was successfully dissected in all patients.

Fixation of the graft by prolene sutures to the dorsal plate above and the saddle bed below was done in all patients without difficulty.

Objective assessment showed nine patients with no noticeable warping. Five patients developed mild warping. No patients had moderate or severe warping on front views. Table 3. (Fig. 2).

Subjectively, those who did not show any warping were fully satisfied (n=9). Among the five patients with objectively mild warping, only two patients showed concern with the deviation, however, with no intention for secondary surgery. Table 4. (Fig. 3).

No complications were noted. Regarding the donor site, no hematoma, infection, bleeding or deformity were noted. Regarding the nose, no dislocation, infection or resorption was noted.

Table 1. Objective Assessment. Scoring of warping.

0	No warping
1	Mild warping. Hardly Noticeable
2	Moderate warping. Noticeable
3	Severe warping. Obvious

Table 2. Subjective Assessment. Scoring of patient's satisfaction.

3	Fully satisfied
2	Satisfied with reservation
1	Not satisfied

Table 3. Objective Assessment of the surgical outcome.

Description	Numerical score	Number of patients	Percentage
No warping	(0)	9	64%
Mild warping	(1)	5	36%
Moderate warping	(2)	0	0%
Severe warping	(3)	0	0%

Table 4. Subjective Assessment of the surgical outcome.

Description	Numerical score	Number of patients	Percentage
Full satisfaction	(3)	12	86%
Satisfied with reservation	(2)	2	14%
Not satisfied	(1)	0	0%

The application of the modified skoog's technique in correction of saddle nose deformity

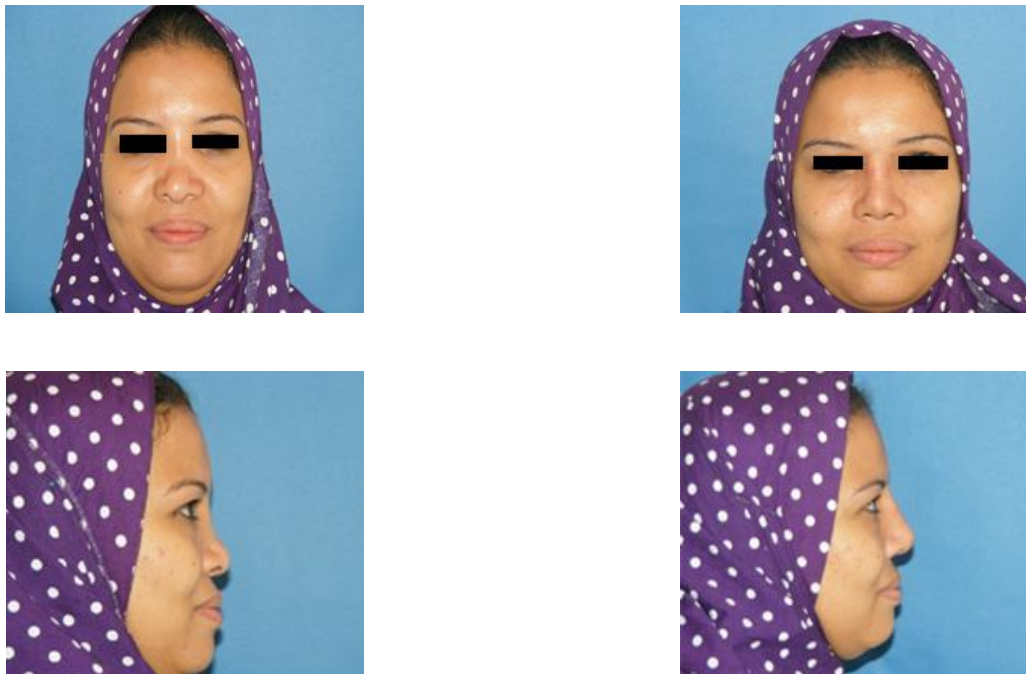

Fig 2. A: Pre (left) and Post-operative (right) front views of a patient with no obvious warping 19 months after surgery. B: Lateral view.

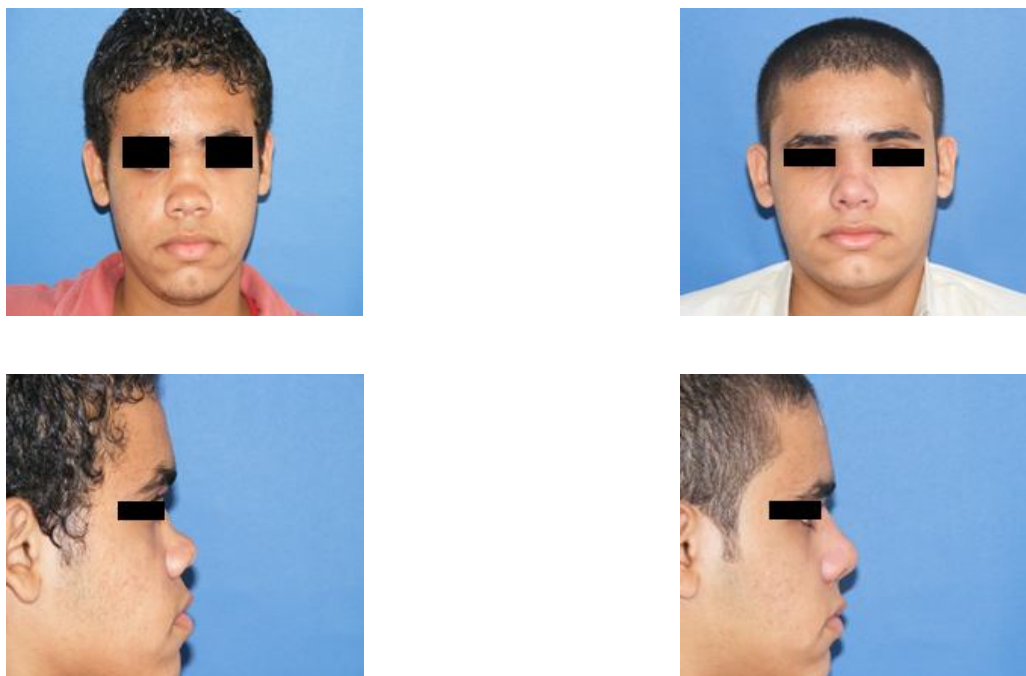

Fig 3. A: Pre (left) and Post-operative (right) front views of a patient with mild warping 11 months after surgery. Note that the graft is showing mild (hardly noticeable) warping towards the left side. B: Lateral view.

DISCUSSION

Costal cartilage is a commonly-used graft in saddle nose correction. Warping is a known event that compromises the surgical outcome. Various attempts have been proposed to prevent or reduce the incidence of cartilage warping. However, none proved to deserve standardization.

Early attempts include balanced cross-sections of the cartilage by concentric carving.⁽²³⁾ Irradiation of homograft cartilage was tried. The reported drawback of cartilage irradiation was the high rate of resorption reaching up to 75%. This was attributed to the lack of living chondrocytes.⁽²⁴⁾

Internal stabilization of rib grafts with Kirschner wire was described by Gunter et al, (1997), who operated on 28 patients. There was no warping after 1 year, but wire extrusion occurred in 3 cases.⁽²⁵⁾

Avoiding molding the graft has been proposed by some surgeons.^(26,27) This implies the use of a straight cartilage that is naturally straight and has no curvature whatsoever. This mainly applies to the eleventh rib.

Another way to reduce warping is the edge – on technique where the inferior border of the cartilage is rotated 90 degrees to become the convex dorsum. Thus, the graft is re-oriented from its orthotopic axial position to a coronal one.⁽²⁸⁾

Jung et al, 2004 recommended to transect 70% of the cartilage width every 1 to 2 mm, alternating between both sides along the entire graft length, once again this technique does not prevent warping completely.⁽²⁹⁾

Therefore, several attempts are described to combat the inherent tendency of the costal cartilage to warp. These included, as described, irradiation of the graft, fixation, avoidance of molding, decortication and cross-hatching. All these techniques were addressing the problem in a direct way. To our knowledge, the problem was not addressed before in an indirect way, meaning to camouflage warping rather than preventing it.

To hide warping, a straight cover is needed. In this study, the natural dorsum, in fact a thin plate of it, was used as a straight cover to achieve this objective. This is considered to be a modification of the Skoog's technique, which was originally described to reposition the resected dorsal hump after osteotomies in order to obtain a natural nasal dorsum without irregularities.

A technical problem was encountered in this study, which is the difficulty of shaving a thin bony-cartilaginous dorsal plate off an already depressed (saddle) dorsum. The use of the knife in the cartilaginous dorsum and an osteotome in

the bony dorsum should be done with care to preserve the integrity of the dorsal plate. The cartilaginous part of this plate is important in graft fixation. The use of a curved osteotome is essential in weakening the dorsal plate at its glabellar attachment, such that a green-stick fracture can be obtained.

Results are quite encouraging; however, the size of the specimen is still small to reach conclusions. The preserved dorsal plate was successful in hiding the warping completely in 9 patients (64%) Mild (hardly noticeable) warping was noted in 5 patients (36%), Table 3. however this did not have a great impact on patient's satisfaction Table 4. Full satisfaction reached 84% patients, although only 64% had no obvious warping. This means that mild warping can be accepted without reservations in some cases. Accordingly subjective scores can further improve the overall results of this technique.

This study raises two new concepts. The first is the modification of the Skoog's technique such that the dorsal plate (rather than the hump) is green-stick fractured and hinged cranially (rather than resection and repositioning). The second new concept is "camouflaging" the warping incident rather than preventing it. Technical difficulties of such a procedure include the difficulty of shaving a thin plate off a saddle dorsum, and the difficulty of achieving suture fixation. Based on our preliminary results we are encouraged to continue using this proposed technique in an attempt to overcome costal cartilage warping.

REFERENCES

1. Emsen IM. New and detailed classification of saddle nose deformity: step by step surgical approach using the current techniques for each group. *Aesthetic Plastic Surgery*. 2008;32:274-85.
2. Lupo G. The history of aesthetic rhinoplasty: special emphasis on saddle nose *Aesthetic Plastic Surgery*. 1997;21:309-27.
3. Frodel JL. Management of nasal dorsum in central facial injuries. *Archives of Otolaryngology Head and Neck Surgery*. 1995;121:307-12.
4. Yabe T., and Muraoka M. Treatment of saddle type nasal fracture using Kirschner wire fixation of nasal septum. *Annals of Plastic Surgery*. 2004;53:89-92.
5. Banks P, Tanner B. The mask rhinoplasty: a technique for treatment of Binders syndrome and related disorders. *Plastic and Reconstructive Surgery*. 1993;92:1038-44.
6. Tardy ME, Schwartz M, Parras G. Saddle nose deformity: autogenous graft repair. *Facial Plastic Surgery*. 1989;6:121-34.

The application of the modified skoog's technique in correction of saddle nose deformity

7. Helie F, Fournier J. Destructive lesions of the median line secondary to cocaine abuse. *Journal of Otolaryngology*. 1997;26:67-69.
8. Dyer WK, Beaty M, Probhat A. Architectural deficiencies of the nose: treatment of saddle nose and short nose deformity. *Otolaryngology Clinics of North America*. 1999;32:89-112.
9. Kim DW, Anil R, Dean M. Concentric and eccentric carved costal cartilage. A comparison of warping. *Archives of Facial Plastic Surgery*. 2006;8:42-6.
10. Daniel RK. Rhinoplasty: septal saddle nose deformity and composite reconstruction. *Plastic and Reconstructive Surgery*. 2007;119:1029-43.
11. Karacaoglan N, Uysal O. Use of iliac bone graft for saddle nose deformity. *Uris Nasus Larynx*. 1998;25:49-57.
12. Thomassin J, Paris J, Richard t. Management and aesthetic results of support graft in saddle nose surgery. *Aesthetic Plastic Surgery*. 2001;25:332-7.
13. Inanli S, Sari M, Serder B. The use of expanded polytetrafluoroethylene (Gore Tex) in rhinoplasty. *Aesthetic Plastic Surgery*. 2007;31:345-8.
14. Chen CT, Hu TL, Lai JB, Chen YC, Chen YR. Reconstruction of traumatic nasal deformity in Orientals. *Plastic and Reconstructive Aesthetic Surgery*. 2008;63:257-64.
15. Erol O. The Turkish Delight: A pliable graft for rhinoplasty. *Plastic and Reconstructive Surgery*. 2000;105:22-9.
16. Daniel RK. Diced cartilage graft in rhinoplasty surgery: current technique and application. *Plastic and Reconstructive Surgery*. 2007;122:1883.
17. Garcia E, Guisantes E, Fontdevile J, Raigosa M, Serra J. Cortical tibial bone graft for nasal augmentation: donor site short scar. *Journal of Plastic, Reconstructive and Aesthetic Surgery*. 2009;105:22-9.
18. Dagli AS, Akalin Y, Bilgili H, Seckin, Ensari S. Correction of saddle nose deformities by coral implantation. *European archives of otorhinolaryngology*. 1997;254:274-6.
19. Gillies HD, Millard DR. Principle and art of plastic surgery. Boston: Little, Brown and co. 1957.
20. Gerow FJ, Stal S, Spira M. Rib graft reconstruction of the nose. *Annals of Plastic Surgery*. 1983;11:273-2810.
21. Hall JA, Peters MD, Hilger PA. Modification of the Skoog dorsal reduction for preservation of the middle nasal vault. *Arch Facial Plast Surg*. 2004;6:205-10.
22. Regnault P, Alfaro A. The Skoog rhinoplasty a modified technique. 1980;66578-90.
23. Gibson T, Davis WB. The distortion of autologous cartilage graft: its cause and prevention. *Journal of Plastic, Surgery*. 1958;10:257.
24. Welling DB, Maves MD, Schuller DE. Irradiated homologous cartilage graft: long term results. *Archive of Otolaryngology Head and Neck surgery*. 1988;114:291-5.
25. Gunter JP, Clark CP, Friedman RM. Internal stabilization of autogenous rib cartilage grafts in rhinoplasty: a barrier to cartilage warping. *Plastic and Reconstructive Surgery*. 1997;100:161-9.
26. Gentile P, Cervelli V. Nasal dorsum reconstruction with 11th rib cartilage and auricular cartilage graft. *Annals of Plastic Surgery*. 2009;62:63-6.
27. Song C, Mackay DR, Chait LA. Use of costal cartilage grafts in Negroid rhinoplasty. *Annals of Plastic Surgery*. 1991;27:201-9.
28. Al Qattan MM. The mask rhinoplasty a technique for the treatment of Binder syndrome and related disorders. *Plastic and Reconstructive Surgery*. 2007;92:1038-44.
29. Jung DH, Choi SH, Moon HJ. A cadaveric analysis of the ideal costal cartilage graft for Asian rhinoplasty. *Plastic and Reconstructive Surgery*. 2004;114:545-50.