



## Transnasal endoscopic management of congenital bilateral choanal atresia with and without stenting

**Shawky M. Elmorsy**

Otorhinolaryngology Department, Faculty of Medicine, Mansoura University, Egypt

Correspondence to: Shawky M. Elmorsy, Email: shawky\_morsy2003@yahoo.com

**Introduction:** *Surgery of choanal atresia aims at complete removal of the atretic plate and assurance of long term wide patency. The use of stents in the treatment of patients with choanal atresia is a controversial subject.*

**Material and Methods:** *This study included 2 groups:*

**First group:** *20 patients with bilateral choanal atresia for whom endoscopic management together with stenting after operations was done (1998-2003). Second look operation was done for all patients.*

**Second group:** *22 patients with bilateral choanal atresia for whom endoscopic management without stenting was done (2003-2008).*

**Results:** *First group: 20 patients (mean ages 10 days  $\pm$  2days). In 4 patients the choanae remained patent after surgery, 12 patients had choanal granulation tissue, 2 patients had repeat stenosis, and 2 patients developed polyp formation, 1 patient had collumellar injury with vestibular stenosis, 1 patient developed posterior pharyngeal wall ulcer from contact with the portex tube & healed spontaneously. Second look operation was done for all patients during removal of the stent.*

**Second group:** *22 patients (mean age 12days  $\pm$  3 days). In 19 patients, the case remained patent after surgery, 7 patients had restenosis, and 1 patient had polyp in the choana.*

**Conclusion:** *Stenting should be avoided as it stimulates granulation formations and is associated with more complications. 2nd look operation appears to be mandatory with the use of the stent. Post-operative follow up to treat any complications and assure complete patency of the neochoanae is important.*

**Keywords:** *Choanal atresia, endoscopic surgery, stenting, flaps.*

### INTRODUCTION

Surgery of choanal atresia aims at complete removal of the atretic plate and assurance of long term wide patency. This entails proper preoperative assessment and good intraoperative visualization. Many approaches have been advocated, including the transpalatal, transnasal, transseptal and transantral.<sup>(1)</sup>

The transpalatal approach has proved to be a popular technique for reasons of ease of surgical exposure, short term stenting, postoperative results and lack of significant complications; mucosal flaps can be easily developed. The transpalatal approach also allows good visualization of the operative field preventing disorientation of the surgeons operating transnasally and possible damage to the base of the skull or posterior pharyngeal wall and spinal cord.<sup>(2)</sup>

## Transnasal endoscopic management of congenital bilateral choanal atresia with and without stenting

Recent advances in the field of computed tomography and intranasal endoscopic surgery led to the suggestion of the Trans nasal endoscopic approach in newborns and infants.<sup>(3)</sup> Careful review of the computed tomography scan and experience with endoscopic nasal surgery makes the transnasal endoscopic treatment a safe and effective approach for managing bilateral choanal atresia.<sup>(4)</sup>

The transnasal endoscopic approach is believed to be the most direct approach to this area and is performed completely under strict visualization. It helps preserve most of the valuable mucosa and avoid injury to nearby important structures. It is performed as a same day surgery, offers immediate feeding, and revision surgery is possible. After surgery, endoscopic follow up helps detect and treat any mucosal adhesions, granulations and or crusting to ensure choanal patency.<sup>(1)</sup>

Choanal atresia has 4 anatomic parts: narrow nasal cavity, lateral bony obstruction by the lateral pterygoid plate, medial obstruction by a thickened vomer, and a membranous obstruction. It was believed that most of the cases were bony (90%), but recent reviews of computerized tomography (CT) studies suggest that most atresias are mixed, and all membranous atresias have some bony component.<sup>(5)</sup>

The use of stents in the treatment of patients with choanal atresia is a controversial subject. Basic questions about mucosal flaps remained to be answered.

Choanal atresia may be an isolated anomaly or one feature of a number of associated congenital anomalies e.g CHARGE association (Coloboma, heart defects, choanal atresia, genital anomalies and ear abnormalities) these associated anomalies should be excluded in a baby with choanal atresia. Minimal investigations in addition to CT scan are cardiac echo, renal scan, and an ophthalmology and audiology review.<sup>(2)</sup>

## PATIENTS AND METHODS

### ***This study included 2 groups***

**First group:** 20 patients (mean ages 10 days $\pm$  2days) with bilateral choanal atresia for whom stenting was used after surgery (1998-2003).

**Second group:** 22 patients (mean age 12days  $\pm$ 3 days) with bilateral choanal atresia for whom no stenting was used after surgery (2003-2008).

**Surgical technique:** Patients were sprayed through the nose with oxymetazoline for 60 minutes, 5 times before the procedure. General anesthesia and intubations were

performed. A zero-degree, 2.7-mm endoscope was used for application of adrenaline soaked pledgets to the nasal cavity, and zero-degree, 2.7- or 4-mm endoscopes were used during the procedure. Longitudinal incision over posterior septum was done, elevating the flap over the vomer and the atretic plate. The soft tissue of the flap was removed, baring the vomer and the atretic plate. The atretic plate was then penetrated through its weakest part and, in most cases, this part is the inferomedial part of the atretic plate. This penetration was widened with extra-long burr and back biting forceps. An endoscope placed on the contra lateral side can provide excellent visualizations during the procedure; curettes, Kirrison's forceps and microdebrider were used for widening the neochoana. The neochoana was widened laterally to the medial pterygoid plate, inferiorly to the palatine bone, medially to the nasal septum, and superiorly just below the level of the sphenoid sinus. The posterior-most part of the septum was also taken by back biting forceps to widen the opening to the nasopharynx, stenting with portex endotracheal tube. Fixation of the stent by proline sutures transeptally.

### ***Post-operative care***

**First group:** Neonatal care for one day, the parents were trained to use suctioning before discharge, the infants was seen every week before removal of the stents.

Stenting for (6-8) weeks. Antibiotics were administered for the whole period of stenting together with saline nasal drops. Second look operation for all patients during stent removal, any granulation or polyps were removed & nasal endoscopy was performed to ensure complete patency of the neochoanae

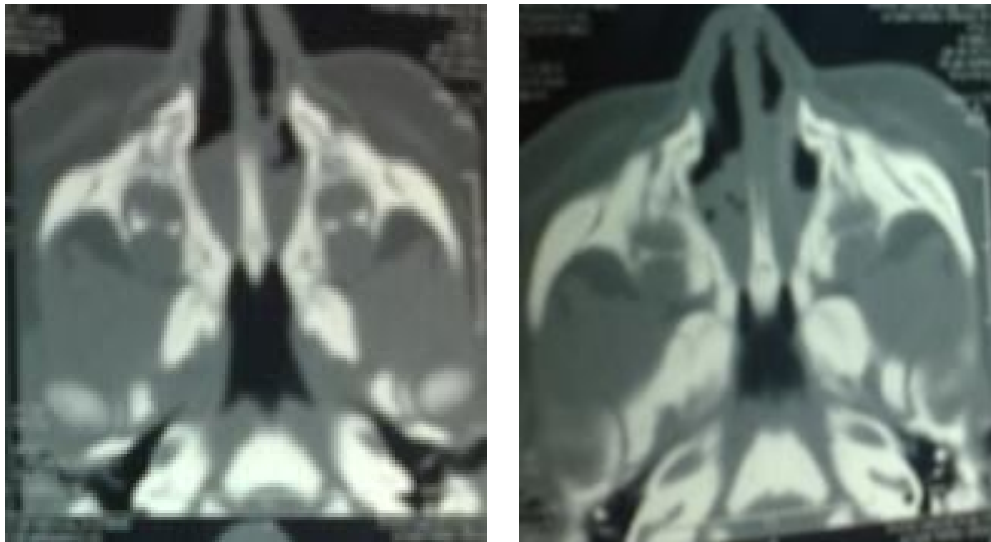
**Second group:** Neonatal care for one day, antibiotics and saline nasal drops were used for one week, fiberoptic endoscopic follow up was done (3-6) months after surgery.

## RESULTS

choanal atresia (Eighteen females and 2 males) in first group, (19 females and 3 males) in second group. Airway placement, admission in neonatal care unit, immediate CT scan (axial cuts) Fig. 1, bleeding profile was obtained, excluding other congenital anomalies especially CHARGE association, blood grouping and preparation of 100cc of fresh blood before surgery, follow up periods ranging from 20-48 months.

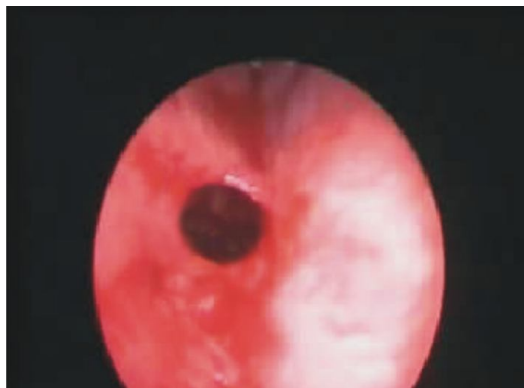Table 1.

	Granulation tissues	Restenosis	Polyp	Collumellar injury	Pharyngeal ulceration
1st group	12	7	2	1	1
2nd group	--	2	1	--	--



**Fig 1. CT scan axial cut. Bilateral choanal atresia.**

**First group:** In 4 patients the case remained patent after surgery (Fig. 2).



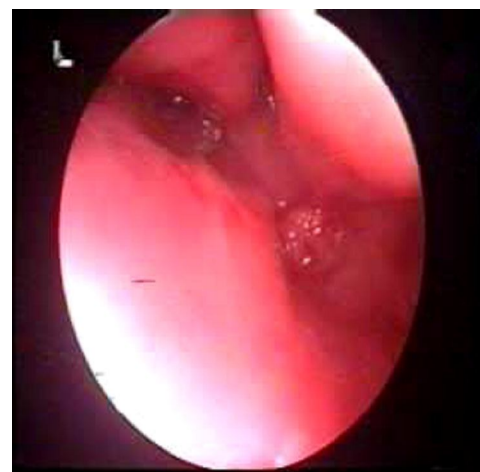**Fig 2. Endoscopic picture of patent RT choana after removal of the stent.**

Twelve patients had choanal granulation tissues which had been removed during removing of the stent.

Seven patients did have repeat stenosis due to inadequate vomer resection and inadequate widening of the choanae

laterally; revision surgery with widening of the choanae was done.

Two patients developed polyp formation, 3 months after removal of the stent for whom revision surgery was done with cleaning of the new choanae (Fig .3).



**Fig 3. Endoscopic view of the LT choana with restenosis and polyp formation.**

## Transnasal endoscopic management of congenital bilateral choanal atresia with and without stenting

One patient had collumellar injury & vestibular stenosis from the rotating burrs.

one patient developed posterior pharyngeal wall ulcer from contact with the portex tube & healed spontaneously.

**Second group:** Surgical technique was done as 1st group but without stenting.

Follow up periods (20-48 months revealed).

Nineteen patients, the case remained patent after surgery.

Two patients had restenosis due to inadequate widening of the choanae laterally; revision surgery was done 6 months and 8 months respectively after the primary surgery.

One patient had granuloma in the choana which was removed endoscopically 4 months after the primary surgery.

### DISCUSSION

Congenital choanal atresia was first described by Roder in 1755.<sup>(6)</sup> choanal atresia occurs in 1-8000 births, of these cases 45% bilateral.

Recent CT and histopathological studies showed evidence of higher incidence of mixed bony and membranous anomalies (70%) and pure bony atresia 30% with No pure membranous anomalies.<sup>(5)</sup>

A survey of the American society of pediatric otolaryngology (ASPO) members revealed that, endoscopic approaches are favored but only slightly over transpalatal repair.<sup>(7)</sup>

2<sup>nd</sup> look operation was a mandatory step in the first group to ensure complete patency of the choanae and to remove any granulation tissues or polyps, during removing the stents. But in the second group, fiberoptic endoscopy was sufficient in postoperative follow up.

The use of stents in the treatment of patients with choanal atresia is a controversial subject. Some surgeons believe that stents are useful in stabilizing the nasal airway in the postoperative period to prevent the development of stenosis by maintaining a lumen. However, others believe that stents may act as a nidus for infection and may induce a foreign body reaction. This may contribute to choanal restenosis, such as an endotracheal tube may cause subglottic stenosis.

**As regards stenting 10 points were put in mind during stenting:**

1. **Length;** the end of the stent should pass through the posterior choanae but should not touch the nasopharyngeal wall; the length should be adequate to support both newly formed choanae but short enough to avoid discomfort or regurgitation of food through the nose.
2. **Width;** the newly formed choanae should approximately match the diameter of the patients endotracheal tube. In a newborn it should be the size of (3.5) mm.
3. **Type;** many types of stents have been suggested; Singh <sup>8</sup> reported good results with a soft stent (gore-tex). Bartal<sup>(9)</sup> suggested the use of a Foley catheter, Lazar et al<sup>(10)</sup> reported excellent results and no complications using a polyvinyl stents.
4. **Fixation;** the stent is fixed in place using proline sutures transseptally.
5. **Suction;** Patients are admitted for at least 2 days to ensure complete patency of the choanae, parents are trained to use a suction apparatus during this period ,the patients are followed up after discharge till removing the stent. Suctioning is recommended at least 6 times daily
6. **Duration;** most studies agree that the stent should stay in place for 6-12 weeks, Lazar et al.<sup>(10)</sup> 1995. The duration of stenting should be individualized but the stent should be left in place until the choanal operative site is mucosalized. Josephson,et al.<sup>(11)</sup> advised 3 weeks for unilateral atresia,6 weeks for bilateral atresia.
7. **Antibiotics;** most authors recommend to use broad spectrum antibiotics for the whole period of stenting. Although prolonged use of antibiotics may occasionally cause the growth of resistant strains of microorganisms.
8. **Anterior end;** should not protrude from the nose to prevent it being grasped by the infant or child and should not be visible externally to prevent social and psychological trauma in older children.
9. **Complications;** injury to the posterior pharyngeal wall, difficult swallowing, nasal regurgitations, granuloma formation at the choanae, infection, adhesions, collumellar injury septal perforation, psychological troubles in older children.
10. **Yes or no?** Stenting is an option with more recent literature pointing towards management without a stent.

Schoem<sup>(12)</sup> reported that the use of a stent in choanal atresia repair seems unnecessary with telescopes, high speed protected drill, and microdebridors. Careful removal of the posterior septal/vomer segment reduces the need to protect denuded tissue from obstructing synechia formation and exuberant granulation tissue.

A recent study suggests that the placement of stents for bilateral choanal atresia repair during the neonatal period results in a high rate of restenosis as well as the need for multiple subsequent procedures during infancy.<sup>(13)</sup>

Cedin et al.<sup>(14)</sup> analyzed the long-term results of a new stentless surgical technique for choanal atresia. They reported that, using neither stents nor nasal packing, this technique allowed fast recovery in a one-step surgery. The endonasal micro-endoscopic surgical approach is successful if combined with postoperative dilations for up to one year. Stenting should be abandoned as it stimulates granulation formation that frequently leads to restenosis. The intraoperative application of Mitomycin C offers a promising adjunct in achieving a stable lumen.<sup>(15)</sup>

Predictive factors of restenosis are the presence of GERD, age younger than 10 days at the time of surgery, and insufficient postoperative endoscopic revision. However, previous surgery and associated malformations are not predictive of a poor surgical outcome.<sup>(16)</sup>

Although creation of flaps varied from investigator to investigator, such as the use of medially or laterally based and crosshatch-like flaps, surgical outcome was very favorable.<sup>(1)</sup>

Basic questions about mucosal flaps remained to be answered. In this series removal of the mucosal flaps over the posterior septum and the atretic plate were done in all patients with or without stenting. The defect over the bone is very small and mucosal healing in infants is excellent. With removal of the posterior edge of the septum no fear from adhesions or granulation tissues formations.

Preservation of the mucosal flaps over the choanae was found to be difficult and unnecessary leaving excess mucosa in the small neonatal choanae would lead to repeat stenosis.<sup>(6)</sup> Onerci et al.<sup>(17)</sup> used laterally based flaps to cover the denuded mucosa and obtained extremely well Results. They concluded that the use of the endoscopic technique with meticulous creation and preservation of intranasal flaps, and avoidance of stenting, provide a good chance of success in choanal atresia repair. Swinging door flap technique for endoscopic transeptal repair of bilateral choanal atresia was described, an adequate functional nasal breathing and appropriate feeding with sufficient weight gain were maintained during the entire follow-up period. The described endoscopic technique offered excellent visualization of the choana and allowed maximal

widening of the choana while preserving the mucosa along the entire circumference of the newly created choana and hence less risk of postoperative stenosis.<sup>(18)</sup> Transnasal mucosal flap rotation technique for repair of posterior choanal atresia was described by Dedo.<sup>(19)</sup>

In this series, cold instruments as curettes, through cutting scissors, Kerrison's, and backbiting forceps were safer and better than powered instrumentations.

KTP laser can be considered as an alternative to conventional procedures in premature infants with bilateral choanal atresia.<sup>(20)</sup>

A combined technique using navigational guidance and nasal and retropalatal endoscopy was used for instrument navigation successfully removing the bony atretic plates. This clinical report demonstrates the feasibility of a combined approach with surgical navigation.<sup>(21)</sup>

## SUMMARY AND CONCLUSION

- Endoscopic management of congenital bilateral choanal atresia without stenting allowed fast recovery in a one-step surgery.
- Stenting should be avoided as it stimulates granulation formations and is associated with more complications.
- Second look operation appears to be mandatory with stenting. Post-operative follow up to treat any complications and assure complete patency of the neochoanae is important.
- Excellent experience, caution, good orientation are needed to avoid injury of nearby important structures.
- With removal of posterior septum, no need for flaps.
- Endoscopic management of congenital bilateral choanal atresia is one of the most difficult applications of advanced endoscopic sinus surgery.

## REFERENCES

1. Kamel R. Transnasal endoscopic approach in congenital choanal atresia. *Laryngoscope*. 1994;104:642-6.
2. Hengerer AS, Newburg JA. Congenital malformations of the nose and paranasal sinuses, in Bluestone CD, Stool SE (eds): *Pediatric Otolaryngology* (ed 2). Philadelphia, PA, Saunders. 1990:727-8.
3. Stankiewicz JA. The endoscopic repair of choanal atresia. *Otolaryngol Head Neck Surg*. 1990;103:931-7.

## Transnasal endoscopic management of congenital bilateral choanal atresia with and without stenting

4. Khafagy YW. Endoscopic repair of bilateral congenital choanal atresia. *Laryngoscope*. 2002;112:316-19.
5. Brown OE, Pownell P, Manning SC. Choanal atresia: A new anatomic Classification and clinical management applications. *Laryngoscope*. 1996;106:97-101.
6. Cumberworth VL, Diazeri B, Maclay IS. Endoscopic fenestration of choanal atresia. *J of Laryngol and Otol*. 1995;109:31-5.
7. Park AH, Brockenbrough J, Stankiewicz. Endoscopic versus traditional approach to choanal atresia. *Otolaryngol Clinic North Amer*. 2000;33:77-90.
8. Singh B. Bilateral choanal atresia: key to success with the transnasal approach. *J Laryngol Otol*. 1990;104:482-4.
9. Bartal, M. An improved stent for use in the management of congenital posterior choanal atresia. *J Laryngol and Otol*. 1988;102:146-7.
10. Lazar RH, Younis RT. Transnasal repair of choanal atresia using telescopes. *Arch Otolaryngol Head Neck surg*. 1995;121:517-20.
11. Josephson GD, Vickery CL, Giles WC, Gross CW Transnasal endoscopic repair of choanal atresia: Long term results. *Arch Otolaryngol Head Neck Surg*. 1998;124:573-40.
12. Schoem SR: Transnasal endoscopic repair of choanal atresia: Why stent? *Otolaryngol Head Neck Surg*. 2004;131:362-6.
13. Zuckerman JD, Zapata S, Sobol SE. Single-stage choanal atresia repair in the neonate. *Arch Otolaryngol Head Neck Surg*. 2008;134:1090-3.
14. Cedin AC, Fujita R, Cruz OL. Endoscopic transeptal surgery for choanal atresia with a stentless folded-over-flap technique. *Otolaryngol Head Neck Surg*. 2006;135:693-8.
15. Gosepath J, Santamaria VE, Lippert BM, Mann WJ. Forty-one cases of congenital choanal atresia over 26 years--retrospective analysis of outcome and technique. *Rhinology*. 2007;45:158-63.
16. Teissier N, Kaguelidou F, Couloigner V, François M, Van Den Abbeele . Predictive factors for success after transnasal endoscopic treatment of choanal atresia. *Arch Otolaryngol Head Neck Surg*. 2008;134:57-61.
17. Önerci M, Yücel TK, Ögretmenoglu O. Transnasal endoscopic surgery in choanal atresia. *Operative Techniques in Otolaryngol*. 2006;17:143-6.
18. Nour YA, Foad H. Swinging door flap technique for endoscopic transeptal repair of bilateral choanal atresia. *Eur Arch Otorhinolaryngol*. 2008;265:1341-7.
19. Dedo H: Transnasal mucosal flap rotation technique for repair of Posterior choanal atresia. *Otolaryngol Head Neck Surg*. 2001;124:674-82.
20. Lapointe A, Giguère CM, Forest VI, Quintal MC. Treatment of bilateral choanal atresia in the premature infant. *Int J Pediatr Otorhinolaryngol*. 2008;72:715-8.
21. Westendorff C, Dammann F, Reinert S, Hoffmann J. Computer-aided surgical treatment of bilateral choanal atresia. *J Craniofac Surg*. 2007;18:654-60.